

# Gadolinium chelate-associated nephrogenic systemic fibrosis

Kei P L, Chan L P

Nephrogenic systemic fibrosis (NSF) is a rare multisystem disease characterised by widespread tissue fibrosis. It is recognised for its epidemiological association in patients with chronic renal failure, after administration of gadolinium-chelate magnetic resonance (MR) contrast agent, particularly gadodiamide (Omniscan, GE Health Diagnostic, Amersham, United Kingdom). Gadolinium-based contrast agents (GBCAs) are used for MR imaging because of gadolinium's ability to increase the T1 relaxivity of soft tissue, increasing the contrast between normal tissue and pathology. As gadolinium, in its free form ( $Gd^{3+}$ ), can result in a toxic reaction *in vivo*, it exists in a form of water-soluble gadolinium chelate complex for use in medical imaging. Several brands of gadolinium-based contrast agents exist, differing from each other by the chelate which binds to the gadolinium ion.

The clinical features of NSF were first observed in 1997 and formally documented in 2000.<sup>(1,2)</sup> By January 2006, Grobner first proposed a possible causal relation between gadolinium-based contrast media and NSF. In that paper, Grobner observed that five of nine haemodialysis patients exposed to a GBCA (gadodiamide in this instance) developed NSF within 2–4 weeks of an MR imaging examination.<sup>(3)</sup> Since then, more than 80 related papers have been published, strengthening the epidemiological association between GBCAs and the development of NSF. Based on currently available data, the estimated incidence for the development of NSF in the patients with chronic renal failure, and who have had GBCA, is in the range of 3%–5%.<sup>(4-6)</sup> NSF has not been described in patients with normal renal function.

The disease was originally named nephrogenic fibrosing dermopathy (NFD) for its more obvious dermatological clinical manifestations; it was later renamed nephrogenic systemic fibrosis in recognition of its systemic effects.<sup>(7)</sup> In spite of this, NSF remains a misnomer as it is not a kidney disease, but rather, it seems to occur in patients with severe renal failure who have received GBCAs. The estimated time between onset of symptoms and the contrast-enhanced MR imaging examination is about two to several months.<sup>(6,8)</sup> The skin manifestation is often the most obvious feature, although it can mimic scleromyxoedema, cellulitis or lymphoedema.<sup>(1)</sup> The skin thickening is usually insidious, but it can develop rapidly and confine the patient to a wheelchair within weeks. There is a predilection for the extremities, but torso

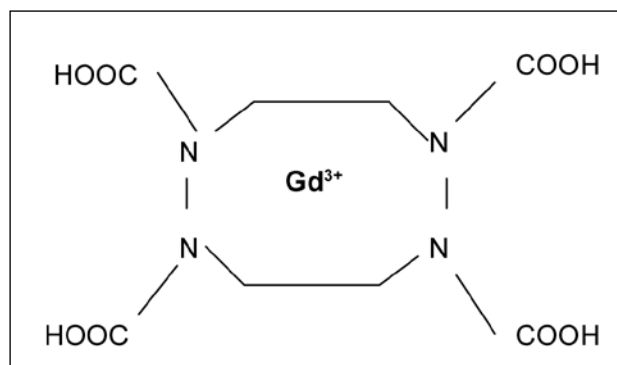


Fig. 1a Chemical structure of a typical macrocyclic contrast agent: Dotarem.

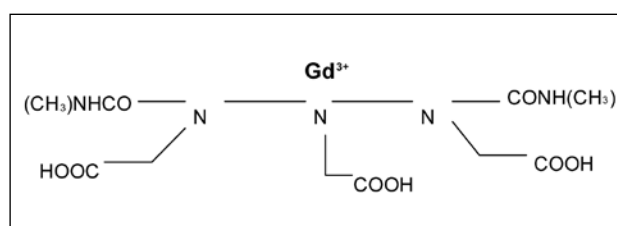


Fig. 1b Chemical structure of a typical linear contrast agent: Omniscan.

involvement has been described. NSF typically spares the face and lacks the serological markers for scleroderma, such as antinuclear antibodies, anti-Scl 70 antibodies and anticentromere antibodies.<sup>(8)</sup> Autopsy series have shown fibrosis of skeletal muscles, bones, lungs, pleura, pericardium, oesophagus and kidneys.<sup>(7,9,10)</sup>

The diagnosis is confirmed on skin biopsy. Histologically, there is increased tissue deposition of collagen bundles separated by cleft and proliferation of distinctive dermal spindle cells that stain positive for both CD 34 and procollagen. The precursors for these spindle cells exist in circulation as free “circulating fibrocytes”. In NSF, these “circulating fibrocytes” are thought to leave the circulation and differentiate into terminal fibroblast cells that are ultimately responsible for systemic fibrosis.<sup>(11)</sup> What triggers these circulating fibrocytes to differentiate into terminal fibroblast cells is unclear, but current thinking suggests  $Gd^{3+}$  may play a major role in the development of NSF. Recent reports have found gadolinium in skin biopsy of patients with NSF on electron dispersion spectroscopy.<sup>(12,13)</sup> While this is not a proof of causation, it is nevertheless supportive of epidemiological association between exposure to GBCA and development of NSF.

Department  
of Diagnostic  
Radiology,  
Singapore General  
Hospital,  
Outram Road,  
Singapore 169608

Kei PL, MBChB,  
MMed, FRCR  
Registrar

Chan LP, MBBS,  
FRCR  
Consultant

Correspondence to:  
Dr Kei Pin Lin  
Tel: (65) 6222 3322  
Fax: (65) 6326 5242  
Email: binglin8@  
yahoo.com.sg

**Table I. Types of gadolinium chelates for MR imaging.**

| Property                             | Gadodiamide<br>Omniscan | Gadopentate<br>Dimeglumine<br>Magnevist | Gadobenate<br>Dimeglumine<br>MultiHance | Gadoterate<br>Meglumine<br>Dotarem | Gadoteridol<br>ProHance | Gadobutrol<br>Gadovist |
|--------------------------------------|-------------------------|---|---|------------------------------------|-------------------------|------------------------|
| Type                                 | Linear                  | Linear                                  | Linear                                  | Macrocyclic                        | Macrocyclic             | Macrocyclic            |
| Charge                               | Non-ionic               | Ionic                                   | Ionic                                   | Ionic                              | Non-ionic               | Non-ionic              |
| Log <sub>10</sub> K <sub>therm</sub> | 16.9                    | 22.5                                    | > 22                                    | 25.4                               | 22.8                    | 21.75                  |
| Log <sub>10</sub> K <sub>cond</sub>  | 14.9                    | 18.1                                    | Not available                           | 19                                 | 16.9                    | 14.67                  |
| Concentration (mol <sup>-1</sup> )   | 0.5M                    | 0.5M                                    | 0.5M                                    | 0.5M                               | 0.5M                    | 1.0M                   |

Extracellular GBCA is eliminated from the body almost exclusively by the kidneys.<sup>(14)</sup> In the setting of chronic renal failure, especially those on dialysis or GFR < 15 ml/min, GBCA exists in the body for a much longer time. The half-life of gadodiamide, for example, is 1.3 hours in normal volunteers and 34.3 hours in patients with end-stage renal disease.<sup>(15)</sup> Marckmann et al postulated that NSF may result from a toxic reaction from Gd<sup>3+</sup>, liberated from the chelate as a result of transmetallation, a process whereby endogenous ions, such as copper, zinc or calcium, substitute for the chelate-bound gadolinium.<sup>(15)</sup> The longer half-life of GBCA in patients with renal impairment may predispose to transmetallation. Some authors have questioned whether transmetallation does occur, citing their own GBCA stability studies,<sup>(16,17)</sup> but most authorities on this subject have not entirely excluded this mechanism.<sup>(18-20)</sup>

GBCAs are classified on the basis of chelate biochemical structures (macrocyclic vs. linear) (Figs. 1a & b) and the chelate charge (ionic vs. non-ionic). Macrocyclic molecules bind gadolinium more tightly than linear chelates, are more stable, and have a lower dissociation rate. Ionic macrocyclic chelates are thought to be least likely to release Gd<sup>3+</sup>, a process which can lead to a toxic reaction in the body.<sup>(21)</sup> Dissociation is an equilibrium, which is governed by a constant, called the thermodynamic stability constant (log<sub>10</sub>K<sub>therm</sub>). Macrocyclic complexes have the highest thermodynamic stability constant. Moreover, at physiological pH, the study of the conditional stability constant (log<sub>10</sub>K<sub>cond</sub>) showed that non-ionic structures are the most stable (Table I).<sup>(22)</sup> In this respect, GBCA with a lower conditional and thermodynamic stability, such as gadodiamide, may be at a higher risk of dissociation than other more stable GBCAs.<sup>(5)</sup> So far, nearly all the GBCAs available on the market have been implicated, with the majority reports linked to gadodiamide. The rest, such as gadopentetate dimeglumine (Magnevist; Berlex Imaging, Montville, NJ, USA) and gadoversetamide (Optimark; Mallinckrodt, St Louis, MO, USA), have also been implicated, albeit in a smaller proportion of patients.<sup>(23)</sup> Since May 2007, the

US Food and Drug Administration (FDA) has requested a blanket “black-box” warning regarding the potential risk of NSF in patients with renal failure to be added to all FDA-approved gadolinium-based MR contrast agents marketed in the United States.<sup>(23)</sup>

It is unclear if other cofactors are needed to trigger the development of NSF. Some authors have also proposed that an underlying inflammatory milieu or metabolic acidosis may exist, such as in the setting of tissue injury (recent surgery and ischaemia), to cause the release of cytokines; these recruit circulatory fibrocytes from the bone marrow to deposit in the skin, joints and soft tissue.<sup>(3,8,24,25)</sup> Acidosis, in particular, has attracted some attention, since the conditional stability of chelate is directly related to the pH of the solution. Grobner was the first to suggest this relationship.<sup>(3)</sup> However, several authors have since questioned whether acidosis is truly necessary for the development of NSF, quoting their own cases in which the mean bicarbonate level was normal in most, if not all, of their patients.<sup>(6,15,26,27)</sup> Erythropoietin has also been implicated as a possible cofactor in the development of NSF.<sup>(28)</sup> Patients with certain concurrent hepatic disease, such as in the setting of acute hepatorenal syndrome or perioperative liver transplant patients, may also be at a higher risk, but the exact relation has yet to be established.<sup>(8)</sup> A recent Scottish study has also shown a positive association between cumulative dose, as well as development of NSF, and severe renal impairment.<sup>(27)</sup> Collidge et al found that such patients received a higher cumulative dose (0.39 mmol/kg vs. 0.23 mmol/kg; p = 0.008) and underwent more gadolinium-enhanced MR imaging, than their non-affected gadolinium-exposed counterparts.<sup>(27)</sup>

There is no known cure at this present time for NSF.<sup>(6)</sup> Improving renal function (either as a result of transplantation or medical therapy) seems to slow or arrest NSF in some patients.<sup>(24)</sup> The severity and rapidity of cutaneous progression correlated with a poorer prognosis, and the systemic involvement is associated with a more extensive cutaneous disease.<sup>(11)</sup> An estimated 5% or less of patients with NSF develop a rapidly progressive form of

the disease that can prove fatal.<sup>(29)</sup> Many of these patients often have other concomitant morbidities.<sup>(10,11,15,30)</sup>

NSF is not alien to Singapore. Currently, there are already a handful of biopsy-proven cases of NSF in Singapore. The earliest reported case dates as far back as July 2004. Tan et al described this condition in a 45-year-old Indian woman with systemic lupus erythematosus with acute deterioration of renal function and had two weeks of haemodialysis.<sup>(31)</sup> At that time, the relationship between NSF and GBCA was not known. Personal communication between the first author and Tan confirmed that this patient did have three intravenous GBCA-enhanced MR imaging scans of her lumbar spine for an unrelated complaint within a period of three months, three and half months prior to onset of the patient's symptoms. Unfortunately, the exact gadolinium agent was not definitively identified.

Two other skin-biopsy proven cases of NSF have also been reported in Singapore.<sup>(26)</sup> Both patients, (one Chinese and one Malay male patient), suffered from severe chronic renal impairment (either on haemodialysis or had started haemodialysis soon after the MR imaging examination). They each had gadodiamide MR angiography examination, one for the assessment for renal artery stenosis, while the other for lower limb ischaemia, prior to the onset of symptoms of NSF. All three patients received either higher than standard dose (> 0.1 mmol/kg of gadodiamide) or several gadolinium-enhanced MR scans within a short period of time. There is no racial predisposition for this condition. We are also aware of a fourth patient with NSF in Singapore; unfortunately, this patient's clinical background was not made available to us at the time of writing this editorial.

While there remains more questions than answers at this point in time, the epidemiological evidence has prompted the FDA to release public health advisories in June and Dec 2006, with a revised version in May 2007, for use of GBCA in patients with chronic renal failure.<sup>(23)</sup> Our institution performs on average 18,000 MR imaging examinations per year, and about half of these studies are performed with intravenous GBCA. In consultation with our nephrology department, we have adopted several of the FDA recommendations and would like to share our practical approach when encountering a patient, who may need MR imaging with intravenous GBCA, as points of information in this paper.

The evidence so far has linked the development of NSF to a small proportion of patients with severe renal failure, and who had received GBCA. The reason for why some patients develop NSF and others do not is still not understood. There are a few cases reported internationally where no history of gadolinium administration has been documented, but there are significant doubts among experts regarding these claims, since most of these reports were from spontaneous, loosely regulated, self-reporting

online registries. Nearly all commercially-available GBCA have been implicated and we apply caution to the use of all gadolinium-chelate formulations at this point in time.

Attempts should be made to obtain the patient's serum creatinine and glomerular filtration rate (GFR) prior to contrast-enhanced MR imaging. The estimated GFR (eGFR) can then be calculated using the Modification of Diet in Renal Disease (MDRD) equation<sup>(32)</sup> and an online calculator is available at: [www.nephron.com](http://www.nephron.com). It should be reminded that this equation is an estimated value to be used in the setting of chronic renal impairment, and is not entirely accurate in the acute setting, and in patients with liver disease. Nonetheless, the MDRD equation provides a quick reference, and widely-used tool in assessing trends in renal function, when both gadolinium and iodinated contrast are being considered for imaging.<sup>(6)</sup> An eGFR level measured within the last six months for a stable outpatient is generally acceptable.<sup>(33)</sup>

When the eGFR is below 30 ml/min/1.73m<sup>2</sup> (severe renal dysfunction), consideration is made whether MR imaging can be performed without intravenous GBCAs, including additional MR sequences that we may normally omit. Alternative imaging methods, including use of computed tomography or ultrasonography, should also be considered. However, when no alternative method is identified, discussing the risks and benefits of a GBCA-enhanced MR imaging with the referring clinician is recommended. Informed consent is then obtained from the patient. As far as possible, a standard or reduced dose of GBCA is administered.

For patients on haemodialysis, prompt haemodialysis following GBCA administration, in order to enhance GBCA elimination, should be considered. This was suggested by the FDA (June 2006 advisory), which stated that the average gadolinium-based contrast media excretory rates are 78%, 96% and 99% in the first to third haemodialysis sessions, respectively.<sup>(33-35)</sup> The FDA (May 2007 advisory)<sup>(23)</sup> has since toned down this suggestion, as there is no comprehensive evidence to establish the utility of haemodialysis to prevent or treat NSF/NFD. For patients not currently on haemodialysis, the need to initiate haemodialysis after the MR procedure has to be evaluated on an individual basis, since establishing vascular access for the sole purpose of removing GBCA entails certain risks and discomfort. For patients on continuous ambulatory peritoneal dialysis (CAPD), it is recommended that the patient does not have a dry abdomen period for at least 48 hours after GBCA administration. Haemodialysis is also considered for patients on CAPD who may still have a functional vascular access for the procedure.<sup>(5)</sup>

If no GFR or serial serum creatinine trend is available, a short questionnaire is applied to identify patients at risk of having abnormal renal function. It is recommended by

the European Society of Urogenital Radiology to identify patients with a higher risk of abnormal renal function prior to administration of any contrast media eliminated via the renal route.<sup>(33)</sup> The questions are as follows:

1. Have you ever been told you have renal problems?
2. Have you ever been told you have protein in your urine?
3. Do you have high blood pressure?
4. Do you have diabetes mellitus?
5. Do you have gout?
6. Have you ever had kidney surgery?

If the answer to any of the above questions is “Yes”, it is recommended to obtain a serum creatinine sample and to establish the patient’s eGFR before GBCA administration. If the answers to all the questions is “No”, there is a high likelihood (up to 94%) that the serum creatinine will be within normal, and we can proceed with the administration of a GBCA, other than gadodiamide. This is an interim measure and we are working towards a workflow whereby some form of prescreening<sup>(18)</sup> is adopted by the referring clinician, prior to requesting a GBCA-based MR imaging study.

The exact relationship between NSF and GBCA remains unclear, and at present, only epidemiological data suggests a possible causal relation. Knowledge of this condition is rapidly evolving and there is still a great deal that we still do not understand. GBCA is no longer regarded as “safe” for patients with severe chronic renal failure. It is also important to reiterate that NSF has not been described in patients with normal renal function and were administered GBCAs. A screening, or even prescreening, policy should be adopted to identify patients who may be at a higher risk for renal impairment, and hence, NSF after GBCA-enhanced MR imaging. The subsequent management of the patient should be guided by the patient’s serum creatinine level or GFR. When GBCAs are used in high-risk patients, it is important to document the exact contrast agent used and the dose administered. If doubts exist, discussion with your local radiologist is strongly recommended.

## ACKNOWLEDGEMENT

We thank Ms Wan Ching Ming for her assistance in the preparation of this manuscript.

## REFERENCES

1. Cowper SE, Robin HS, Steinberg SM, et al. Scleromyxoedema-like cutaneous diseases in renal-dialysis patients. *Lancet* 2000; 356:1000-1.
2. Cowper SE, Su LD, Bhawan J, Robin HS, LeBoit PE. Nephrogenic fibrosing dermatopathy. *Am J Dermatopathol* 2001; 23:383-93.
3. Grobner T. Gadolinium--a specific trigger for the development of nephrogenic fibrosing dermatopathy and nephrogenic systemic fibrosis? *Nephrol Dial Transplant* 2006; 21:1104-8.
4. Stenver DI. Investigation of the safety of MRI contrast medium Omniscan. Danish Medicines Agency 2006. Available at: [www.dkma.dk/1024/visUKLSArtikel.asp?artikelID=8931](http://www.dkma.dk/1024/visUKLSArtikel.asp?artikelID=8931). Accessed February 19, 2007.
5. Kuo PH, Kanal E, Abu-Alfa AK, Cowper SE. Gadolinium-based MR contrast agents and nephrogenic systemic fibrosis. *Radiology* 2007; 242:647-9.
6. Sadowski EA, Bennett LK, Chan MR, et al. Nephrogenic systemic fibrosis: risk factors and incidence estimation. *Radiology* 2007; 243:148-57.
7. Gibson SE, Farver CF, Prayson RA. Multiorgan involvement in nephrogenic fibrosing dermatopathy: an autopsy case and review of the literature. *Arch Pathol Lab Med* 2006; 130:209-12.
8. Broome DR, Girguis MS, Baron PW, et al. Gadodiamide-associated nephrogenic systemic fibrosis: why radiologists should be concerned. *Am J Roentgenol* 2007; 188:586-92.
9. Daram SR, Cortese CM, Bastani B. Nephrogenic fibrosing dermatopathy/nephrogenic systemic fibrosis: report of a new case with literature review. *Am J Kidney Dis* 2005; 46:754-9.
10. Kucher C, Xu X, Pasha T, Elenitsas R. Histopathologic comparison of nephrogenic fibrosing dermatopathy and scleromyxedema. *J Cutan Pathol* 2005; 32:484-90.
11. Mendoza FA, Artlett CM, Sandorfi N, et al. Description of 12 cases of nephrogenic fibrosing dermatopathy and review of the literature. *Semin Arthritis Rheum* 2006; 35:238-49.
12. High WA, Ayers RA, Chandler J, Zito G, Cowper SE. Gadolinium is detectable within the tissue of patients with nephrogenic systemic fibrosis. *J Am Acad Dermatol* 2007; 56:21-6.
13. Boyd AS, Zic JA, Abraham JL. Gadolinium deposition in nephrogenic fibrosing dermatopathy. *J Am Acad Dermatol* 2007; 56:27-30.
14. Thomsen HS, Morcos SK, Dawson P. Is there a causal relation between the administration of gadolinium based contrast media and the development of nephrogenic systemic fibrosis (NSF)? *Clin Radiol* 2006; 61:905-6.
15. Marckmann P, Skov L, Rossen K, et al. Nephrogenic systemic fibrosis: suspected causative role of gadodiamide used for contrast-enhanced magnetic resonance imaging. *J Am Soc Nephrol* 2006; 17:2359-62.
16. Normann PT, Joffe P, Martinsen I, Thomsen HS. Quantification of gadodiamide as Gd in serum, peritoneal dialysate and faeces by inductively coupled plasma atomic emission spectroscopy and comparative analysis by high-performance liquid chromatography. *J Pharm Biomed Anal* 2000; 22:939-47.
17. Reinton V, Pharm KJ, Berg MG, et al. Pharmacokinetics of gadodiamide injections in patients with moderately impaired renal function. *Acad Radiol*. 1994; 9(suppl 1):S56-S61.
18. Kanal E, Barkovich AJ, Bell C, et al; ACR Blue Ribbon Panel on MR Safety. ACR guidance document for safe MR practices: 2007. *Am J Roentgenol* 2007; 188:1447-74.
19. Leiner T, Herborn CU, Goyen M. Nephrogenic systemic fibrosis is not exclusively associated with gadodiamide. *Eur Radiol* 2007; 17:1921-3.
20. Thakral C, Alhariri J, Abraham JL. Long-term retention of gadolinium in tissues from nephrogenic systemic fibrosis patient after multiple gadolinium-enhanced MRI scans: case report and implications. *Contrast Mol Media Imaging* 2007; 2:199-205.
21. Peak AS, Sheller A. Risk factors for developing gadolinium-induced nephrogenic systemic fibrosis. *Ann Pharmacother* 2007; 41:1481-5.
22. Bellin MF, Vasile M, Morel-Precetti S. Currently used non-specific extracellular MR contrast media. *Eur Radiol* 2003; 13:2688-98.
23. U.S. Food and Drug Administration. Information for Healthcare Professionals Gadolinium-Based Contrast Agents for Magnetic Resonance Imaging (marketed as Magnevist, MultiHance, Omniscan, OptiMARK, ProHance). Department of Health and Human Services 2007. Available at: [www.fda.gov/cder/drug/InfoSheets/HCP/gcca\\_200705.htm](http://www.fda.gov/cder/drug/InfoSheets/HCP/gcca_200705.htm). Accessed September 28, 2007.
24. Cowper SE, Bucala R, Leboit PE. Nephrogenic fibrosing dermatopathy/

- nephrogenic systemic fibrosis--setting the record straight. *Semin Arthritis Rheum* 2006; 35:208-10.
25. Galan A, Cowper SE, Bucala R. Nephrogenic systemic fibrosis (nephrogenic fibrosing dermatopathy). *Curr Opin Rheumatol* 2006;18:614-7.
26. Lim YL, Lee HY, Low SC, et al. Possible role of gadolinium in nephrogenic systemic fibrosis: report of two cases and review of the literature. *Clin Exp Dermatol* 2007; 32:353-8.
27. Collidge TA, Thomson PC, Mark PB, et al. Gadolinium-enhanced MR imaging and nephrogenic systemic fibrosis: retrospective study of a renal replacement therapy cohort. *Radiology* 2007; 245:168-75.
28. Swaminathan S, Ahmed I, McCarthy JT, et al. Nephrogenic fibrosin dermatopathy and high-dose erythropoietin therapy. *Ann Intern Med* 2006; 145:234-5.
29. The International Center for Nephrogenic Fibrosing Dermatopathy Research (ICNFDR). Available at: [www.icnfd.org](http://www.icnfd.org). Accessed October 15, 2007.
30. Weiss AS, Lucia MS, Teitelbaum I. A case of nephrogenic fibrosing dermatopathy/nephrogenic systemic fibrosis. *Nat Clin Pract Nephrol* 2007; 3:111-5.
31. Tan AW, Tan SH, Lian TY, Ng SK. A case of nephrogenic fibrosing dermatopathy. *Ann Acad Med Singapore* 2004; 33:527-9.
32. Lameire N, Adam A, Becker CR, et al; CIN Consensus Working Panel. Baseline renal function screening. *Am J Cardiol* 2006; 98:21K-6K.
33. Thomsen HS; European Society of Urogenital Radiology. European Society of Urogenital Radiology guidelines on contrast media application. *Curr Opin Urol* 2007; 17:70-6.
34. U.S. Food and Drug Administration. Public Health Advisory Update on Magnetic Resonance Imaging (MRI) Contrast Agents Containing Gadolinium and Nephrogenic Fibrosing Dermatopathy. Department of Health and Human Services 2006. Available at: [www.fda.gov/cder/drug/advisory/gadolinium\\_agents\\_20061222.htm](http://www.fda.gov/cder/drug/advisory/gadolinium_agents_20061222.htm). Accessed October 15, 2007.
35. Okada S, Katagiri K, Kumazaki T, Yokoyama H. Safety of gadolinium contrast agent in hemodialysis patients. *Acta Radiol* 2001; 42:339-41.

## 2008 SMJ Best Research Paper Awards

The Singapore Medical Association will be presenting awards for the Best Research Paper published in the Singapore Medical Journal (SMJ) in 2008. All original research papers that are published in the SMJ during the one year period from January 1, 2008 to December 31, 2008 will be considered for this award.

**The following are the judging criteria:**

- **The paper with the most potential impact on clinical practice**
- **Most rigorous study design/research methodologies**
- **Comprehensive data analysis and balanced discussion**
- **Data interpretation**

Distinguished members of the medical profession will be invited to serve on our panel of judges for selecting the winning papers.

The authors of the winning papers selected by our panel of judges will receive cash prizes for the first, second and third places. Prize winners will also receive a commemorative trophy and certificate.

*We thank you for your support of the SMJ. The quality of our journal depends on the quality of your submissions.*