

# Elastic cord-related ocular injury

Wong M H Y, Yang M, Yeo K T

## ABSTRACT

We report a case of an elastic cord-related ocular injury, to increase the public's awareness of the seriousness of this type of injury. A 43-year-old Chinese postman presented with decreased visual acuity in the left eye after being hit by an elastic cord at work. Slit lamp examination revealed pupillary sphincter rupture with iridodonesis and phacodonesis. There was also a traumatic nuclear cataract, gross hyphaema and vitreous haemorrhage. The patient was started on topical steroids and antibiotics. His visual acuity and vitreous haemorrhage improved during subsequent visits. Elastic cord-related ocular injuries have potential sight-threatening consequences. The public should be aware of the possible danger of using elastic cords.

**Keywords:** elastic cord, eye trauma, ocular injury, pupillary sphincter rupture

*Singapore Med J 2008;49(4):e90-e92*

## INTRODUCTION

Elastic cords have been used widely. In the household, they can be used to secure furniture and household appliances. In the workplace, it is used, for example, in the postal service to secure bulky letters and parcels, or in the airline service, to secure luggage. They have also been used with increasing frequency in sports like skiing and wind surfing. There have been reports of severe ocular eye damage caused by direct impact of the recoiling cord. We present a case in our local setting of how the usage of the elastic cord can have sight-threatening consequences. Institutional review board approval was not required.

## CASE REPORT

A 43-year-old Chinese man, working as a postman, presented with decreased visual acuity in the left eye after being hit by an elastic cord at work (Fig. 1). Visual acuity in the left eye registered hand movements only. Visual acuity in the right eye was 6/6. Slit lamp examination of the left eye revealed pupillary sphincter rupture at the one and nine o'clock positions (Fig. 2). There were also iridodonesis and phacodonesis. A traumatic nuclear-sclerotic cataract was noted as well. Anterior chamber red blood cells was 4+ with gross hyphaema of 0.5 mm in height (Fig. 2). Intraocular pressure of the left eye was 4 mmHg and that of the right was 16 mmHg. The difference in intraocular pressure raised the suspicion of a possible



Fig. 1 Photograph shows the elastic cord with a J metal hook.

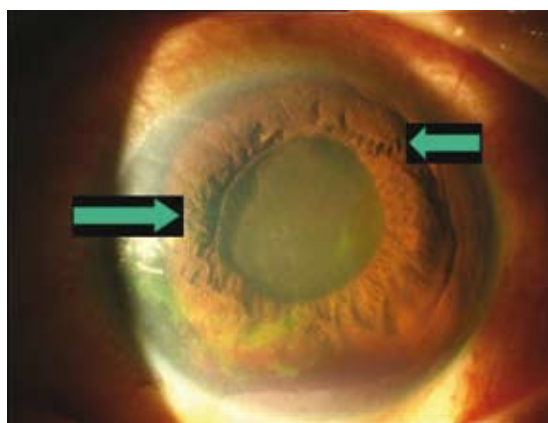


Fig. 2 Anterior segment photograph shows gross hyphaema and pupillary sphincter rupture at the one and nine o'clock positions.

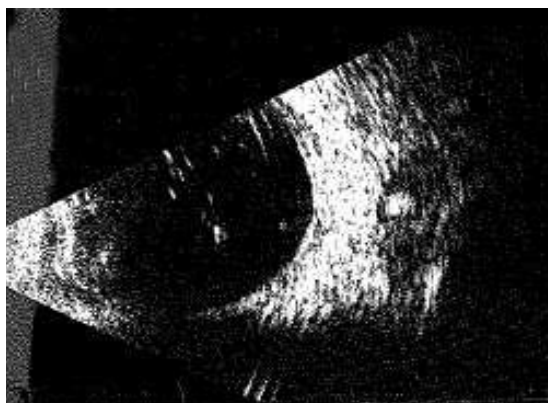

Fig. 3 B-scan US image of the left eye shows vitreous haemorrhage.

globe rupture. The extraocular movement range, however, was retained. Examination of the left fundus showed severe vitreous haemorrhage with no view of the posterior segment at initial presentation. B-scan ultrasonography showed no evidence of any retinal detachment and the outline of the globe was grossly intact (Fig. 3).

The patient was started on topical steroids and

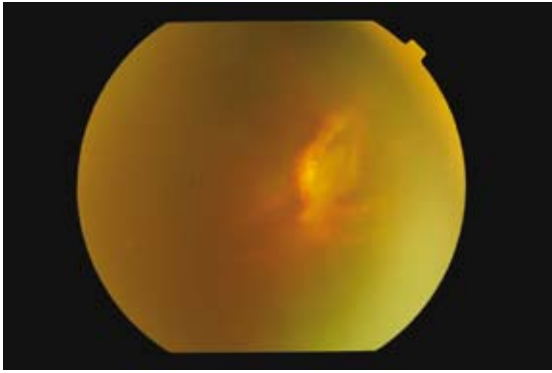
Singapore National Eye Centre,  
11 Third Hospital Avenue,  
Outram Road,  
Singapore 168751

Wong MHY, MBBS  
Medical Officer

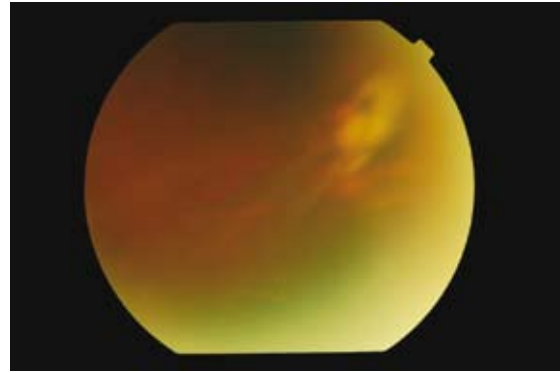
Yang M, MBBS,  
MMed, MRCSE  
Registrar

Yeo KT, FRCSE,  
FRCOphth, FAMS  
Senior Consultant


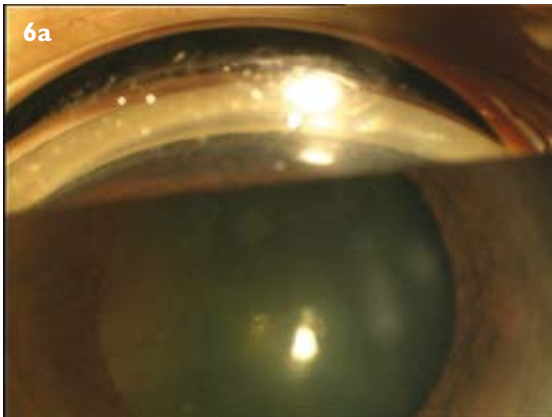
**Correspondence to:**  
Dr Melissa Wong  
Hsing Yi  
Tel: (65) 6227 7255  
Fax: (65) 6227 7290  
Email: melwhy@  
singnet.com.sg



**Fig. 4** Colour fundus photograph shows the retinal break temporally.



**Fig. 5** Colour fundus photograph shows vitreo-retinal traction at the break.



**Fig. 6** (a,b) Gonioscopy photographs show 180 degrees of angle recession.

antibiotics to reduce the inflammation. He was also started on oral ciprofloxacin as prophylaxis in case there was an occult globe rupture. Subsequent follow-up showed an improvement in visual acuity from hand movements to 6/12 over a two-week period. Significant vitreous haemorrhage was still present and the view of the retina was still partially obscured. The gross hyphaema had cleared up. The patient was reviewed regularly at short intervals at the outpatient clinic to monitor for raised intraocular pressure that could result from the hyphaema, traumatic neuropathy, as well as to get a better view of the retina as the vitreous haemorrhage cleared up.

Three weeks after the accident, the patient was noted to have a retinal break temporally (Fig. 4). Laser retinopexy was held off until the media was clearer. There was associated vitreo-retinal traction that was monitored closely (Fig. 5). The patient also had a subluxed mild nuclear sclerotic cataract that did not require any surgical intervention yet, as his best recorded visual acuity was 6/9 and there was no secondary angle closure glaucoma. Currently, two months after the onset of the accident, the patient was found to have 180 degrees of angle recession, with incomplete iridodialysis on gonioscopy (Figs. 6a & b). His intraocular pressure will have to be monitored closely at future follow-ups with the view to start medical therapy. If the pressure is not well controlled, surgical

intervention may be required.

## DISCUSSION

The World Health Organisation counts ocular trauma as one of the major causes of avoidable blindness.<sup>(1)</sup> Elastic cord-related damage induces more severe ocular damage than most other injuries, with a significant number of patients achieving poorer visual outcomes. In a retrospective analysis using the Erlangen Ocular Contusion Registry by Viestenz et al, a final visual acuity of less than 6/30 on the day of discharge was found for 26% of elastic cord-injured patients, and for only 11% of patients with other types of ocular contusion; this difference was statistically significant.<sup>(1)</sup>

It has also been reported by Brouzas et al in a retrospective study of 28 patients with elastic cord ocular injuries, that the most common anterior segment injuries were hyphaema /microhyphaema (71.4%) and corneal abrasions (57.1%). Commotio retinae (60.7%) followed by subretinal hemorrhage (14.3%) were the most common posterior segment findings. The most severe injuries were corneal or scleral lacerations (7.1%), retinal tear (10.7%), retinal detachment (3.6%), lens subluxation (7.1%) and traumatic cataract (7.1%). A few other patients with angle recession went on to develop angle recession glaucoma 10–19 months after the injury. After a period of follow-up

ranging from three to 67 months, the final visual acuity was 20/30 or better in 82.1% of the patients, whereas 3.6% had 20/200 or worse visual acuity.<sup>(2)</sup>

In our local setting, the elastic cord has been in use for many years. The typical elastic cord comprises the elastic portion that has a polyvinylchloride covering as well as a steel J-shaped wire hook at the other end. Severe blunt trauma can take place as a result of the force generated by the elastic recoil of the cord or by direct injury from the J hook. The public should be made aware of the possible potential sight-threatening consequences of the elastic cord and be informed of the safety precautions during its usage. Some authors have suggested incorporating written warnings on the packaging of all elastic cords as

well as using protective eyewear. Others have suggested modifying the design of the cord, such as replacing the elastic cord with a non-elastic strap with an adjustable buckle.<sup>(3)</sup> Perhaps then would there be a reduction in the number of elastic cord-related ocular injuries seen in our accident and emergency departments.

## REFERENCES

1. Viestenz A, Kuchle M. Ocular contusion caused by elastic cords: a retrospective analysis using the Erlangen Ocular Contusion Registry. *Clin Experiment Ophthalmol* 2002; 30:266-9.
2. Brouzas D, Charakidas A, Papagiannakopoulos D, Koukoulomatis P. Elastic cord induced injuries. *Injury* 2003; 34:323-6.
3. Hollander DA, Aldave AJ. Ocular bungee cord injuries. *Curr Opin Ophthalmol* 2002; 13:167-70.