

Gonadal mosaicism 45,X/46,X,psu dic(Y)(q11.2) resulting in a Turner phenotype with mixed gonadal dysgenesis

Gole L A, Lim J, Crolla J A, Loke K Y

ABSTRACT

A two-year-and-eight-month-old girl presented with clitoromegaly and short stature. Two cell lines, 45,X and 46,X, idic(Y)(q11.2), were observed. Cytogenetic and fluorescence *in situ* hybridisation investigations were carried out on her peripheral lymphocytes and gonadal cells, to determine the genotype-phenotype effect with respect to differential tissue distribution, effects of the sex determining region of the Y chromosome, and the break-points in the azoospermia factor region.

Keywords: fluorescence *in situ* hybridisation, gonadal dysgenesis, mosaicism, sex chromosome aberrations, Turner syndrome

Singapore Med J 2008;49(4):349-351

INTRODUCTION

As dicentric chromosomes are inherently unstable, isodicentric Y chromosomes are usually found in association with a monosomic X (45,X) cell line. Consequently, clinical presentations in these patients can range from a classical Turner phenotype, through mixed gonadal dysgenesis, to phenotypically-normal males.^(1,2) Such variability in the sexual phenotype is thought to be related to the tissue distribution and relative proportions in the developing gonads of the respective cell lines, particularly those with functional copies of the SRY gene (sex determining region of the Y chromosome). However, studies on gonadal tissue are hindered by the fact that it is rarely available for analysis, and a more easily-accessible tissue is usually studied. A further factor influencing the phenotype may be the breakpoint in the Yq long arm, resulting in the duplication or absence of the regions bearing genes for azoospermia factor (AZF) a, b and c. We have karyotyped gonadal skin, right and left gonads as well as peripheral lymphocytes to determine the distribution of these two cell lines. Fluorescence *in situ* hybridisation (FISH) probes have been used to detect the SRY, as well as to localise the breakpoint in the Yq11.2

region to determine the presence/absence, as well as the effect of the AZF region on phenotype.

CASE REPORT

A two-year-and-eight-month-old girl was referred with clitoromegaly and short stature (height 81 cm: < third percentile). She was the fifth child of a non-consanguineous marriage with uneventful birth history, and her developmental milestones were normal. Examination of the external genitalia revealed clitoromegaly (phallic length 3 cm; diameter 1 cm), with separate urethral and vaginal orifices (Fig. 1). Pelvic ultrasonography demonstrated a vestigial uterus with a patent vagina, no ovaries and no adnexal mass. Laboratory findings included normal levels of 17-hydroxy progesterone (0.34 nmol/L), thus excluding simple virilising congenital hyperplasia. The serum testosterone was unmeasurable at < 0.14 nmol/L. Laparoscopic exploration revealed a left streak ovary and a right ovotestis. She underwent clitoroplasty and a bilateral gonadectomy. Histopathology showed the left gonad to contain streak ovarian elements, while the right gonad consisted mainly of immature testicular tissue with some rudimentary ovarian tissue in the adjacent connective tissue.

Chromosomal analysis of peripheral blood lymphocytes in our index patient revealed two populations of cells. One cell line (10%) was hypodiploid with only one X chromosome, while the other cell line (90%) was diploid, having one X chromosome and an isodicentric Y with a breakpoint in Yq11.2 (Fig. 2). Fibroblasts from the genital skin were cultured and two cell lines were observed in the percentage of 45,X[72]/46,X,idic(Y)(q11.2)[28]. Gonadal tissue taken from the right gonad showed 45,X[69]/46,X,idic(Y)(q11.2)[31] and the left gonad showed only the 45,X cell line (Fig. 3). For FISH analysis, probes on both the long and short arms of the Y chromosome were used (Wessex Regional Genetics Reference Laboratories, Salisbury, UK and Sanger Centre, Cambridge, UK). The proband's abnormal Y chromosome showed two FISH signals with the Ypter, SRY(Yp11.2), DYZ3(Ycen), RP11-70G12 (Yq11.23), RP11-539D10

Department of Obstetrics and Gynaecology, National University of Singapore, 5 Lower Kent Ridge Road, Singapore 119074

Gole LA, PhD
Clinical Cytogeneticist

Paediatric Endocrinology Service, Department of Paediatrics

Loke KY, MRCP, FRCPCH
Associate Professor, Senior Consultant and Head

Thomson Prenatal Diagnostic Laboratory, Thomson Medical Centre, 339 Thomson Road, Singapore 307677

Lim J, PhD
Clinical Cytogeneticist

Prenatal and Molecular Cytogenetics, Wessex Regional Genetics Laboratory, Salisbury District Hospital, Salisbury SP2 8BJ, The United Kingdom

Crolla JA, PhD
Head

Correspondence to:
Dr Leena Gole
Tel: (65) 6772 4009
Fax: (65) 6872 3056
Email:leenagole@gmail.com

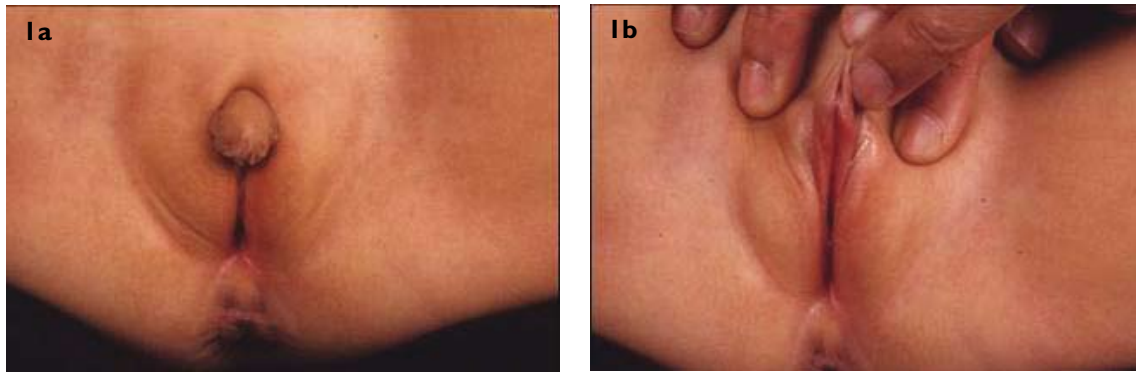


Fig. 1 Photographs of the external genitalia show (a) clitoromegaly, with (b) separate urethral and vaginal orifices.



Fig. 2 GTL-banded karyotype of the proband shows the idic(Y)(q11.23).

(Yq11.23) probes (Fig. 3), but no signal was seen with the probe CTA959A10 (Yq11.23) and DYZ1(Yqh) probe indicating that the breakpoint lies in the 800 kb interval between RP11-539D10 and CTA959A10 in the AZFc region (Figs. 4a & b).

DISCUSSION

Isodicentric Y chromosomes appear to be formed by a single break in one of the Y chromatids, followed by a fusion of the broken ends of sister chromatids and the loss of the acentric fragment during gametogenesis before formation of spermatids. Such rearrangements are generally unstable and an additional 45,X cell line is frequently present.⁽³⁾ This study aimed to establish the influence of sex chromosome mosaicism on the resulting phenotype with respect to differential tissue distribution, effects of the SRY and the breakpoints in the AZF region. The ratio of the Y-bearing cells to the monosomic X cell line in blood and gonadal tissues was highly skewed and not at all representative of each other. The gonadal skin had 28% idicY-bearing cells, the rest being monosomic for the X chromosome. The right gonad, which was an ovotestis, had 31% of idicY cells while the left gonad, which was a streak ovary, had all cells with 45,X and no idicY cells. The peripheral blood lymphocytes showed 90% of cells with an idicY chromosome. The differing representation is understandable as gonads develop from the endoderm, while blood is derived from the mesoderm. As gonadal tissues are not easily available, there are few reports on such comparisons, and most studies correlate phenotype with peripheral lymphocyte karyotypes, which leads to the current uncertainty with predicting the phenotype

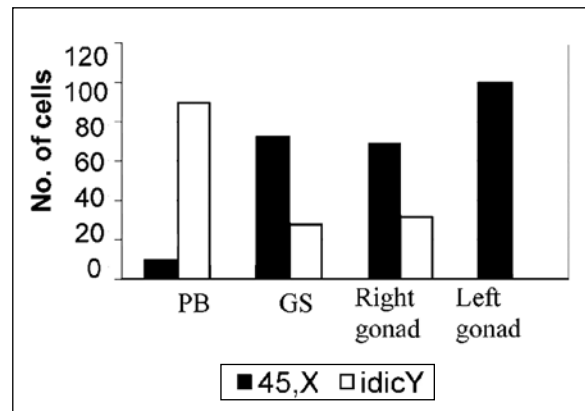


Fig. 3 Bar chart shows the distribution of monosomy X and Y-bearing cells in different tissues in the peripheral blood (PB), gonadal skin (GS), and right and left gonads.

resulting from this mosaic karyotype.^(4,5)

Formation of the testis from the undifferentiated embryonic gonad depends on the presence of the short arm of the Y chromosome, containing SRY-sequences. Testosterone production stimulates development of the Wolffian system and induces male development of the external genitalia, failing which, differentiation proceeds along female lines and Müllerian structures are formed. There seems to be the necessity of a minimal amount of SRY to be present for the undifferentiated gonad to become a testis. Apparently, in our case, the threshold of SRY-containing cells (31%) required for the development of the embryonic gonad into a testis was obviously not adequate to enable complete differentiation of the right gonad into a testis resulting in clitoromegaly. A report by Reddy et al, showed the presence of a testis with only 21% Y-bearing cells.⁽⁶⁾ Another illustrative case, reported by Sugarman et al, described a male individual with mixed gonadal dysgenesis and a 45,X/46,X,dic(Yp) karyotype.⁽⁷⁾ These authors had the opportunity to karyotype cells of the streak gonad on one side, and the normal looking testis on the other side. A 45,X karyotype was found in metaphases of tissue cells derived from the streak gonad, while a 46,X,dic(Yp) karyotype was found in tissue cells from the normal testis on the other side, which obviously had adequate SRY products to differentiate the gonad into

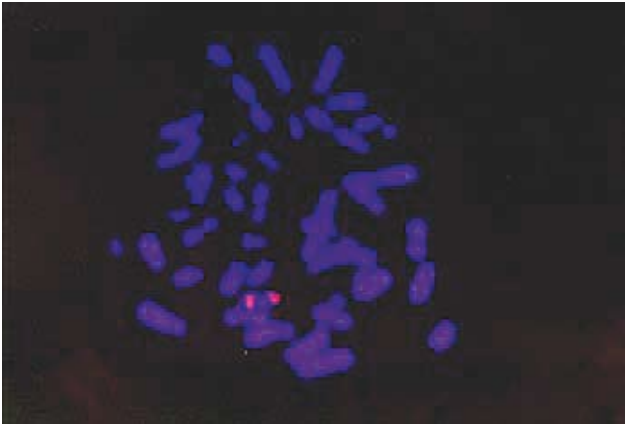


Fig. 4a Isodicentric Y shows two copies of the SRY (red signals).

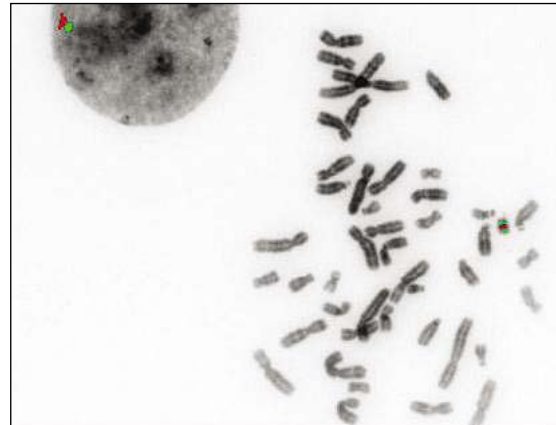


Fig. 4b Y centromere is observed as green signals and RPI1-539D10 is seen as red signals.

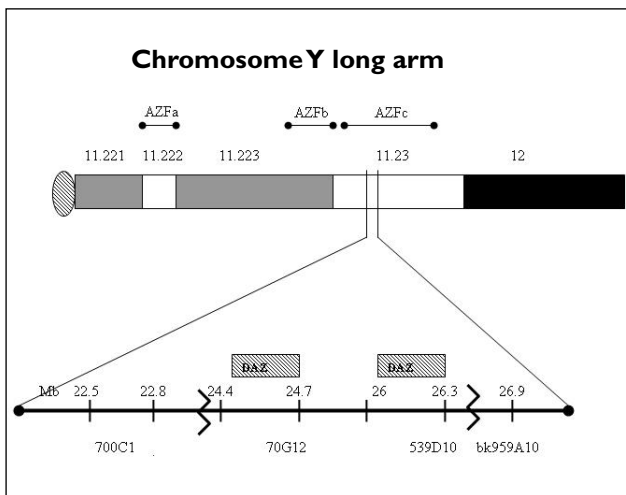


Fig. 5 The breakpoint is observed in the AZFc region. The two shaded boxes show the copies of the DAZ genes as two clusters on the chromosome Y long arm.

a testis. An attempt to refine the breakpoint in the Y long arm using FISH probes was successfully carried out in this patient. The fluorescently-labelled probes RP11-70G12 and RP11-539D10, used in this study, lie within the two clusters of DAZ (deleted in azoospermia) genes, absence of which can cause infertility in males.^(8,9) In our patient, the breakpoint lies between 539D10 and CTA959A10, which is beyond the DAZ gene cluster, indicating presence of the DAZ gene (Fig. 5). However, this would not have any bearing on the proband as she had streak gonads, which were later removed.

In conclusion, the cells predominantly present in the gonads seem to be influencing the phenotypic sex, irrespective of the percentage of Y-bearing cells in the blood or buccal mucosa. The 45,X cell line may exert a more dominant effect on sexual differentiation, only if it is predominant in the gonads. This seems to be supported by a recent article on prenatally diagnosed 45,X/46,X, idic(Y)^(10,11) where the outcome of the cases was a normal male phenotype, despite differing percentages of the X- and Y-bearing cell lines in the peripheral blood. The presence of testes in these individuals obviously suggests that the Y cell line with adequate SRY product

must have been present in the gonadal tissue—enabling differentiation along male lines, though infertility may be a distinct possibility. It is, however, clear that the percentages of the Y-bearing cell line in the peripheral blood remains an unreliable indicator of the sexual phenotype. This is exemplified in our proband where the presence of only the 45,X cell line leads to the formation of ovarian tissue in the left streak gonad, whereas the mosaic presence of the idic(Y) cell line together with the 45,X cell line, leads to formation of testicular tissue in the right streak ovotestis. In our patient, the 90% Y cells in the peripheral blood are not a suitable indicator for the resulting phenotype.

REFERENCES

- Hsu LY. Phenotype/karyotype correlations of Y chromosome aneuploidy with emphasis on structural aberrations in postnatally diagnosed cases. *Am J Med Genet* 1994; 53:108-40.
- Tuck-Muller CM, Chen H, Martinez JE, et al. Isodicentric Y chromosome: cytogenetic, molecular and clinical studies and review of the literature. *Hum Genet* 1995; 96:119-29.
- Quilter CR, Nathwani N, Conway GS, et al. A comparative study between infertile males and patients with Turner syndrome to determine the influence of sex chromosome mosaicism and the breakpoints of structurally abnormal Y chromosomes on phenotypic sex. *J Med Genet* 2002; 39:e80.
- Queipo G, Nieto K, Grether P, et al. Unusual mixed gonadal dysgenesis associated with Müllerian duct persistence, polygonadia, and a 45,X/46,X, idic(Y)(p) karyotype. *Am J Med Genet A* 2005; 136:386-9.
- Marcus-Soekarman D, Hamers G, Mulder AL, et al. Sonographic genital ambiguity in a fetus due to a mosaic 45,X/46,X, idic(Y)(qter-p11.32::p11.32-qter) karyotype. *Prenat Diagn* 2005; 25:279-82.
- Reddy KS, Sulcova V, Ho CK, Conner ED, Khurana A. An infant with a mosaic 45,X/46,X, psu dic(Y) (pter-->q11.2::q11.2-->pter) karyotype and mixed gonadal dysgenesis studied for extent of mosaicism in the gonads. *Am J Med Genet* 1996; 66:441-4.
- Sugarman ID, Crolla JA, Malone PS. Mixed gonadal dysgenesis and cell line differentiation. Case presentation and literature review. *Clin Genet* 1994; 46:313-5.
- Kuroda-Kawaguchi T, Skaletsky H, Brown LG, et al. The AZFc region of the Y chromosome features massive palindromes and uniform recurrent deletions in infertile men. *Nat Genet* 2001; 29:279-86.
- Jenderny J, Schmidt W, Held KR. Presence of the AZF region in a female with an idic(Y)(q11). *Clin Genet* 1998; 54:341-4.
- Willis MJ, Bird LM, Dell'aquila M, Jones MC. Natural history of prenatally diagnosed 46,X, isodicentric Y. *Prenat Diagn* 2006; 26:134-7.
- Bruyère H, Speevak MD, Winsor EJ, et al. Isodicentric Yp: prenatal diagnosis and outcome in 12 cases. *Prenat Diagn* 2006; 26:324-9.