

HYPOTHALAMIC HAMARTOMA: MR IMAGING AND MR SPECTROSCOPIC FEATURES

Dear Sir,

A 7-year-old boy presented with central precocious puberty and abnormal behaviour characterised by episodes of laughing. Magnetic resonance (MR) imaging of the brain revealed a well-defined, non-enhancing mass arising from the hypothalamus, which was isointense to grey matter on T1-weighted (Fig. 1) and moderately hyperintense on T2-weighted (Fig. 2) sequences. Proton MR spectroscopy (MRS) of the mass showed elevated myoinositol peak (Fig. 2). Imaging features were characteristic of hypothalamic hamartoma (HH).

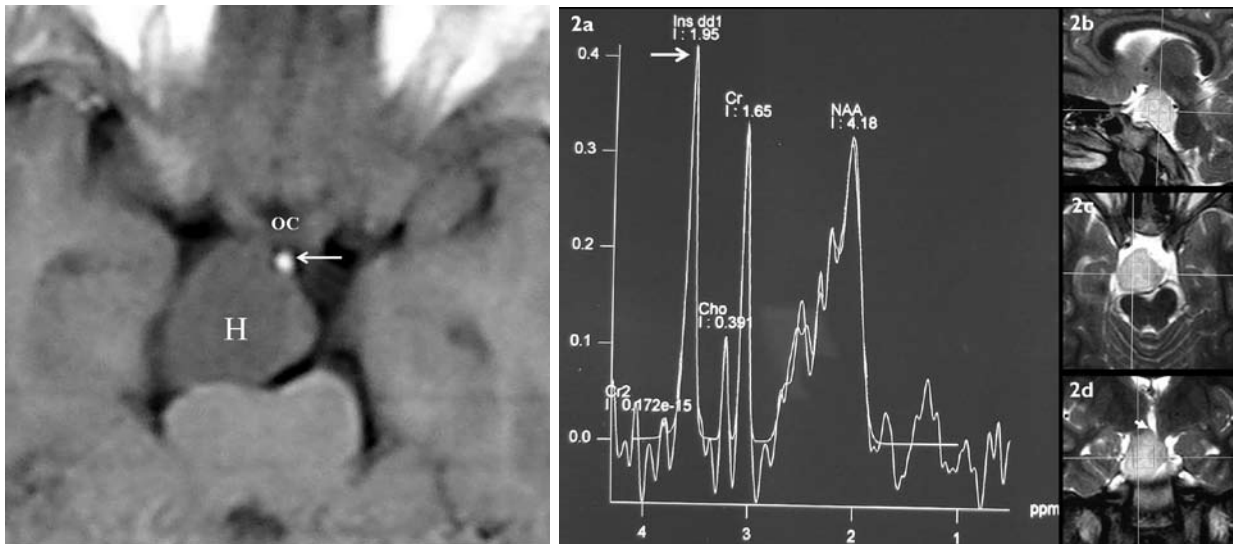


Fig. 1 Axial contrast-enhanced T1-weighted MR image shows the hypothalamic hamartoma (H) in the supra-sellar area posterior to the pituitary stalk (arrow) and the optic chiasma (OC).

Fig. 2 (a) Single-voxel MR spectroscopic study (short TE = 30 msec) shows an elevated myoinositol peak (arrow) from the hamartoma. (b-d) Sagittal, axial, and coronal T2-weighted images show the position of the voxel, the exophytic, hyperintense HH, causing distortion of the floor of the third ventricle (short arrow).

HH is a developmental malformation in the region of tuber cinereum and mamillary bodies that typically manifests in the first or second decade of life. It represents the most commonly detectable lesion in patients with precocious puberty and is associated with gelastic (laughing) seizures. MR imaging findings of a well-defined, sessile or pedunculated hypothalamic mass, isointense to grey matter on T1-weighted and iso/hyperintense on T2-weighted sequences are diagnostic.⁽¹⁾ Short echo MRS has been recently shown to further characterise the lesion by depicting elevated myoinositol peak.⁽²⁾ Hyperintensity on T2-weighted sequences and increased myoinositol reflect increase in the glial tissue in HH, compared with the normal brain.⁽²⁾ Differential diagnosis of HH includes craniopharyngioma, and optic-hypothalamic glioma. However, clinical and MR imaging features allow the accurate diagnosis of HH in most cases.

Yours sincerely,

Ashu Seith
Harsh Kandpal
Rajesh Khadgawat*

Department of Radiodiagnosis
Department of Endocrinology*
All India Institute of Medical Sciences
Ansari Nagar
New Delhi 110029
India

Tel: (91) 98 1020 8551
Fax: (91)11 2686 2663
Email: drharshk@yahoo.com

REFERENCES

1. Shah P, Patkar D, Patankar T, et al. MR imaging features in hypothalamic hamartoma: a report of three cases and review of literature J Postgrad Med 1999; 45:84-6.
2. Freeman JL, Coleman LT, Wellard RM, et al. MR imaging and spectroscopic study of epileptogenic hypothalamic hamartomas: analysis of 72 cases. Am J Neuroradiol 2004; 25:450-62.



1st ASIAN CONFERENCE ON THE SCIENCE OF AGING AND REGENERATIVE MEDICINE

4 - 6 JULY 2008
Grand Copthorne Waterfront Hotel
SINGAPORE

KEY HIGHLIGHTS

- >> More than 25 local and international expert speakers
- >> Hormone Replacement Therapeutics
- >> Mini-symposia on Stem Cell Research and Therapy, Aesthetic Medicine, Integrative Medicine
- >> Practical Guide Workshop on Supplements' Prescription
- >> Certified ABAARM Clinical Training Course in Preventive, Anti-Aging and Regenerative Medicine
30 June - 03 July 2008
- >> Certified ABAARM Clinical Training Course in Aesthetic Medicine
07 - 08 July 2008
- >> ABAARM Part I Written Exam and Tutorials
- >> Approved for Category I AMA/PRA CME Credits
- >> Category 1B SMC CME points TBA

LIMITED SPACES AVAILABLE! REGISTER NOW!

www.antiagingsingapore.com
Contact Us @ +65 6844 8834 OR ask@antiagingsingapore.com

Supporting Organisations:



Supported by:



Held in:

