

Splenic hydatid cyst perforating into the colon manifesting as acute massive lower gastrointestinal bleeding: an unusual presentation of disseminated abdominal echinococcosis

Teke Z, Yagci A B, Atalay A O, Kabay B

ABSTRACT

Hydatid disease can occur in all viscera and soft tissues, although the liver and the lungs are the organs most commonly involved. Isolated splenic involvement with the disease is extremely rare. Splenic hydatid cysts may suppurate, fistulise to adjacent organs, or rupture into the peritoneal cavity. However, acute, massive lower gastrointestinal bleeding due to splenocolic communication resulting from splenic echinococcal cyst has not been previously reported. We present a 77-year-old woman with disseminated abdominal echinococcosis, and active lower gastrointestinal bleeding due to splenocolic fistula resulting from splenic hydatid cyst. She was treated successfully with en-bloc excision of the spleen and splenic flexure of the colon.

Keywords: echinococcosis, gastrointestinal bleeding, hydatid cyst, hydatid disease, splenic hydatidosis, splenocolic fistula

Singapore Med J 2008;49(5):e113-e116

INTRODUCTION

Hydatid disease is endemic in regions where animal husbandry is common.⁽¹⁾ However, with changing patterns of emigration and immigration, cases are being seen in urban centres of the developed world. The pathogen is a tapeworm, *Echinococcus granulosus*, which lives in the intestines of dogs and other mammals, with sheep and humans being the intermediate hosts in the development cycle of hydatid disease. In humans, the liver is the organ most frequently affected, followed by the lungs.⁽²⁾ The traumatic or spontaneous rupture of a hydatid cyst may put the patient's life at risk due to anaphylaxis. If the patient survives, the development of new hydatid cysts may cause a difficult-to-treat situation.

Splenic hydatid disease is rare; its occurrence even

in endemic areas is less than 5% of the total incidence of echinococcosis.⁽³⁾ Splenic hydatid cysts may suppurate, fistulise to adjacent organs or rupture into the peritoneal cavity.⁽⁴⁾ We report a case of splenic hydatid cyst in the context of disseminated abdominal echinococcosis perforating into the colon and presenting as acute, massive lower gastrointestinal bleeding, requiring urgent surgical intervention with splenectomy and partial colectomy. To our knowledge, this is the first reported case of disseminated abdominal echinococcosis and acute, massive lower gastrointestinal bleeding due to splenocolic fistula resulting from a splenic hydatid cyst.

CASE REPORT

A 77-year-old woman presented to the emergency department at our institution with haematochezia. She had been seen at another clinic with a complaint of bright red, bloody stools. A diagnosis of lower gastrointestinal bleeding was established, and the patient was admitted to the hospital for further evaluation and management. The patient's past medical history included hypertension which was controlled with antihypertensive drugs, as well as hysterectomy for uterine myoma 34 years earlier. The patient denied any history of motor vehicle accidents, which might have led to the intraperitoneal rupture of an asymptomatic echinococcal cyst.

On admission, the patient was haemodynamically unstable, hypotensive with a blood pressure of 90/50 mmHg, and a heart rate of 129/min. The patient's temperature was 36.5°C. On physical examination, she had mild tenderness in the left upper quadrant of her abdomen, with no rebound, guarding, mass or hepatosplenomegaly on physical examination. Bowel sounds were hyperactive. Digital rectal examination revealed bright red blood. Haematological examinations showed a haemoglobin level of 6.0 g/dL (normal range 13.6–17.2 g/dL), a haematocrit level of 17.8% (normal range 35.0%–50.3%), and 18,600 leucocytes per μL (normal range 3,600–9,400/ μL) with 85.0% neutrophils. Biochemical studies revealed a serum

Department of
General Surgery,
School of Medicine,
Pamukkale University,
Kinikli,
Denizli 20070,
Turkey

Teke Z, MD
Consultant

Atalay AO, MD
Senior Resident

Kabay B, MD
Associate Professor

Department of
Radiology

Yagci AB, MD
Assistant Professor

Correspondence to:
Dr Zafer Teke
Kuspinar Mah. Emek
Cad. Oyku Sitesi
A-Blok, No. 121,
K:4, D:10,
Denizli 20020,
Turkey
Tel: (90) 542 264 4046
Fax: (90) 258 213 4922
Email: zteke_md@
yahoo.com; zteke_
md@hotmail.com

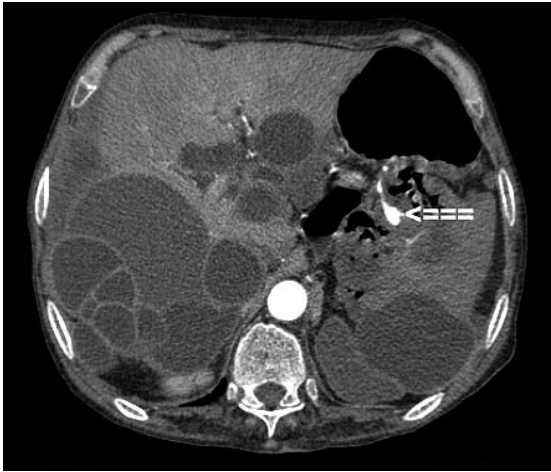


Fig. 1 Contrast-enhanced axial CT image of the upper abdomen shows a ruptured cystic lesion measuring 5.4 cm × 5.6 cm in the inferior pole of the spleen, with an appearance of gas in the cystic cavity and an active extravasation of contrast medium at the level of splenic hilus and colon's splenic flexure (arrow). Note multiple cystic lesions in the liver and spleen.

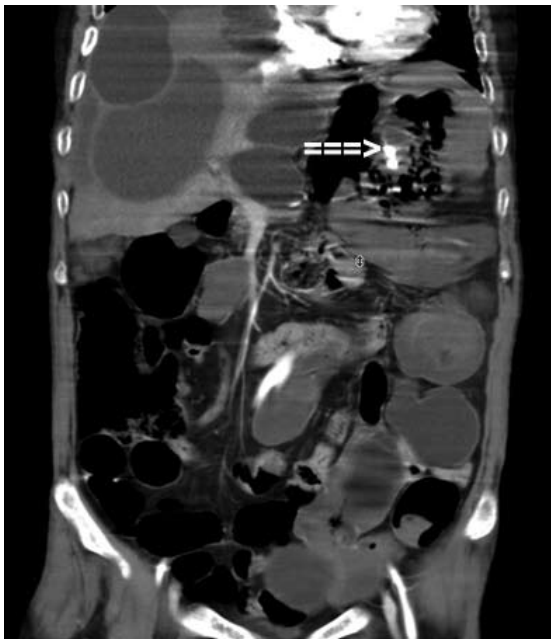


Fig. 2 Contrast-enhanced reconstructed coronal abdominopelvic CT image shows active extravasation of contrast agent from the splenic hilus into the colon's splenic flexure (arrow). This confirms communication between the splenic hydatid cyst and colon. Note multiple cystic lesions in the abdomen and pelvis.

blood urea nitrogen level of 74.0 mg/dL (normal range 6.0–20.0 mg/dL).

Once the patient's vital signs and haemodynamics were stabilised with early and vigorous fluid resuscitation, further diagnostic studies were undertaken. A nasogastric tube was inserted and lavage showed a clear, nonbilious aspirate. Upper gastrointestinal endoscopy revealed no putative site of the bleeding. Colonoscopy was carried out, but it failed to show the source of the bleeding due to active major bleeding. Abdominopelvic contrast-enhanced multiphasic multidetector computed tomography (MDCT)

performed in the arterial phase showed a ruptured cystic lesion measuring 5.4 cm × 5.6 cm in the inferior pole of the spleen (Fig. 1), with an appearance of gas in the cystic cavity, and an extravasation of contrast medium at the level of splenic hilus and colon's splenic flexure (Fig. 2). Hyperdense material filling the left colon and multiple cystic lesions in the abdominopelvic region were also established in the MDCT.

A diagnosis of splenocolic fistula resulting from splenic hydatid cyst due to disseminated abdominal echinococcosis was made; emergency surgical intervention was performed to control the active bleeding and to decrease the risk of secondary intraperitoneal perforation of the splenocolic communication. Emergency laparotomy was performed through a midline incision, and surgical exploration revealed disseminated abdominopelvic hydatid cysts. A hydatid cyst, which was located in the inferior pole of the spleen, had manifestly invaded the colon's splenic flexure. An en-bloc excision of the spleen and splenic flexure of the colon was performed. A gross examination of the resected specimen was conducted intraoperatively. When cystotomy was performed, a partial detachment of the germinative membrane, and many daughter vesicles with varying sizes in the cystic cavity, was detected (Fig. 3). After evacuation of the cyst, a fistula between the splenic hydatid cyst and the colon's splenic flexure, approximately 1 cm in diameter, was established (Fig. 4). The resected colonic specimen was filled with coagulum. Pathological examination confirmed the classic laminated cyst wall encircling many scolices with a double layer of hooklets; this is consistent with *Echinococcus granulosus* infection. The postoperative course was uneventful. The patient was discharged on the seventh postoperative day and prescribed three 28-day cycles of albendazole therapy.

DISCUSSION

Hydatid disease continues to be a major health problem worldwide, mainly in sheep- and cattle-raising areas of the world. Hydatid cysts can develop anywhere in the human body, but the liver is the most frequently involved organ (52%–77%), followed by the lungs (10%–40%). Most of the patients present no overt clinical symptoms. However, hydatid disease may cause life-threatening conditions. Among the major complications of abdominal echinococcal cysts, intrathoracic or intraabdominal rupture, communicating rupture into the biliary tree, primary or secondary infections, extrinsic compression of the bile ducts, systemic anaphylactic reactions, and secondary peritoneal or pleural hydatidosis are the most frequent and life-threatening complications.⁽⁵⁾ Rupture into the peritoneal cavity can lead to anaphylaxis or the development of new hydatid cysts.⁽⁶⁾ The rate of

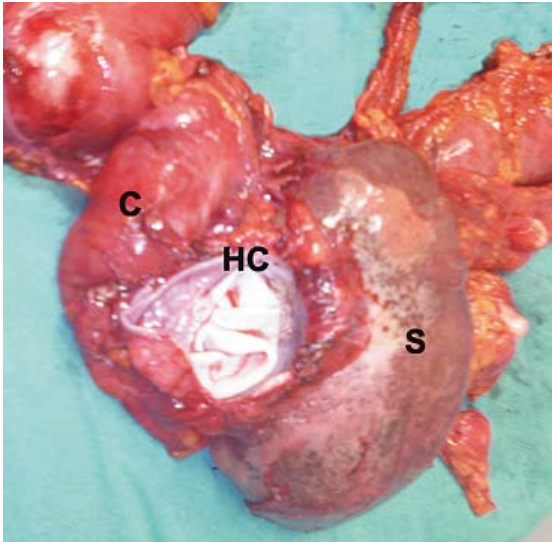


Fig. 3 Intraoperative photograph shows the gross appearance of the resected specimen from the anterior side. Note the germinal layer of the hydatid cyst.
S: spleen; C: colon; HC: hydatid cyst.

development of disseminated abdominal echinococcosis after traumatic or spontaneous intraabdominal rupture of hydatid cysts is not completely known, since all descriptions in the medical literature come from individual case reports.⁽⁷⁾

Abdominal hydatid cysts, especially those in the liver, have the capacity for fistula formation, mainly in the biliary ducts, and thus present one of the classic complications which the general surgeon is confronted with during a hydatid disease operation. The gastrointestinal complications of hydatid infestation are less frequently seen, as it seems that the walls of the digestive tract offer a major resistance to the formation of communications between the cystic cavity and the gastrointestinal lumen. The aetiopathogenesis of echinococcal cysts in the spleen is uncommon. Once it reaches the systemic circulation by passing through the liver and lung, the hexacanth embryos will be trapped in the splenic capillaries.⁽⁸⁾ As the hydatid cyst grows, it may cause compression of the segmentary vessels of the spleen, which results in extensive pericystic splenic atrophy. In addition, the hydatid cyst may entirely replace the splenic parenchyma. The process of chronic aseptic pericystic inflammation causes adhesions to nearby structures, and thus a fistulisation between the cyst and adjacent organs, such as the stomach, pancreas, left colon, left kidney or bronchus, may develop.

Echinococcal cysts of the spleen may be asymptomatic for years before diagnosis. The patients usually complain of mild discomfort or pain in the left hypochondrium. An infection or intraperitoneal rupture of the hydatid cyst leads to severe pain. Splenic hydatid cysts may rarely perforate into the stomach, colon, thorax, or fistulise to the skin. The passage of hydatid membranes in the stools (hydatidenteria or hydatidorrhoea) is certainly a specific

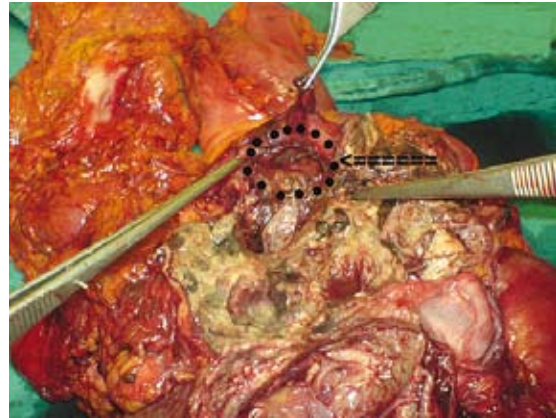


Fig. 4 Intraoperative photograph shows the gross appearance of the resected specimen after evacuation of the cystic cavity. The dotted circle indicates the orifice of splenic fistula, which is approximately 1 cm in diameter.

sign of rupture and gastrointestinal communication. Presumably, haematochezia results from evacuation of the splenic pulp from the infarcted spleen into the colon. The case presented in this report was admitted to our emergency department with acute, massive lower gastrointestinal bleeding causing hypovolaemic shock and limiting the findings on colonoscopic examination. Upon review of the medical literature, there was no report of an association between a splenic hydatid cyst and active lower gastrointestinal bleeding.

Hydatid disease can be easily diagnosed preoperatively with radiological studies, including ultrasonography (US) and CT. However, US or CT findings of splenic echinococcal cysts are not specific. Conditions that produce appearances similar to those that occur during other splenic cystic lesions must be ruled out, such as an abscess, an epidermoid cyst, a pseudocyst or a cystic neoplasm on US or CT.⁽⁹⁾ Clinicians often encounter difficulty when considering the differential diagnosis of splenic hydatid disease. The patient's personal history, the presence of calcification of the cyst wall, and especially the presence of daughter cysts in a large cystic lesion or concomitant cystic lesions in the liver or other organs, are helpful for diagnosing splenic hydatidosis.⁽¹⁰⁾ In this case, we chose CT as the first-line diagnostic tool, and made the differential diagnosis by demonstrating the concomitant cystic lesions in the liver and the pelvic organs.

Acute lower gastrointestinal bleeding may be more easily diagnosed thanks to the development of modern radiological imaging, such as MDCT. This is a technical innovation in vascular imaging that can produce noninvasive, spectacular multiplanar reconstructions of the abdominal vessels and organs using modified CT scanning techniques.⁽¹¹⁾ MDCT may be preferable to catheter

angiography or technetium-99m labelled red blood cell scintigraphy as the first-line imaging investigation for acute lower gastrointestinal bleeding, if endoscopy fails to locate the site of lower gastrointestinal bleeding. We chose MDCT with multiplanar reconstructions after a failed colonoscopy. This scanning technique showed us the extravasation of contrast medium from the splenic hilus into the colon's splenic flexure, and also abdominopelvic multiple cystic lesions. The source of the active major bleeding was found, and the final diagnosis was confirmed as splenocolic fistula resulting from a splenic hydatid cyst. This observation suggests that MDCT may have an important role in the management of selected patients with acute and clinically significant lower gastrointestinal bleeding.

The surgical treatment of disseminated abdominal hydatidosis poses a formidable challenge for the surgeon. Total resection of the cysts is the treatment of choice. However, this is not always possible. Conservative methods, such as cyst enucleation, deroofting of the cyst with omentoplasty or external drainage, may be applied when the cysts are infected or their locations and size do not allow their safe resection.^(7,12) Free intraperitoneal hydatid cysts can be easily resected because they usually do not stick tightly to other organs. In our patient, only splenic echinococcal cysts could be resected with total splenectomy. The other cysts were not removed, because the size, location and number of the cysts did not allow a more radical approach, given the compromised general condition of the patient.

Patients with splenic hydatid cysts frequently present challenging therapeutic problems. Treatment of splenic hydatidosis is mainly surgical, although there is considerable controversy as to the best type of surgical approach. Partial splenectomy is a risky operation because it is difficult to have vascular control when incising the splenic tissue. Unroofing the cyst wall leaves behind a residual cavity, which carries the risk of postoperative infection.⁽⁸⁾ For the above reasons and the possibility of multiple splenic cysts, total splenectomy should be the method of choice, especially in the presence of a communication between the spleen and nearby organs, such as the stomach, colon and diaphragm. However, partial splenectomy with omentoplasty may be reserved for cases with unresectable cysts tightly adherent to adjacent structures. We performed total splenectomy

with the resection of the splenic flexure with primary colonic anastomosis, with no procedure-related morbidity and mortality. After the splenectomy, the patient was given prophylactic vaccination against *Streptococcus pneumoniae*, *Haemophilus influenzae* type b and *Neisseria meningitidis*, and was started on a two-year course of prophylactic penicillin. No post-splenectomy infection was encountered. Since disseminated echinococcosis is an absolute indication for antihelminthic drug therapy, the patient was also given albendazole (10 mg/kg/day) for three months.

To our knowledge, there have been no other case reports of acute, massive lower gastrointestinal bleeding due to splenocolic fistula resulting from a splenic hydatid cyst. Nevertheless, when it is difficult to identify the source of lower gastrointestinal bleeding in a patient with splenic hydatidosis, a splenocolic fistula resulting from a splenic echinococcal cyst should be considered in the differential diagnosis.

REFERENCES

1. Bilge A, Sözüer EM. Diagnosis and surgical treatment of hepatic hydatid disease. *HPB Surg* 1994; 8:77-81.
2. Eckert J, Deplazes P. Biological, epidemiological, and clinical aspects of echinococcosis, a zoonosis of increasing concern. *Clin Microbiol Rev* 2004; 17:107-35.
3. Amir-Jahed AK, Fardin R, Farzad A, Bakshandeh K. Clinical echinococcosis. *Ann Surg* 1975; 182:541-6.
4. Gregg RO, Halsey WS. Echinococcal cyst of spleen. *NY State J Med* 1973; 73:693-4.
5. Sayek I, Tirnaksiz MB, Dogan R. Cystic hydatid disease: current trends in diagnosis and management. *Surg Today* 2004; 34:987-96.
6. Sözüer EM, Ok E, Arslan M. The perforation problem in hydatid disease. *Am J Trop Med Hyg* 2002; 66:575-7.
7. Gunay K, Taviloglu K, Berber E, Ertekin C. Traumatic rupture of hydatid cysts: a 12-year experience from an endemic region. *J Trauma* 1999; 46:164-7.
8. Bourgeon R, Catalano H, Pantin JP. [L'Échinococcose splénique]. *J Chir (Paris)* 1960; 80:608-32. French.
9. Dachman AH, Ross PR, Murari PJ, Olmsted WW, Lichtenstein JE. Nonparasitic splenic cysts: a report of 52 cases with radiologic-pathologic correlation. *Am J Roentgenol* 1986; 147:537-42.
10. Safioleas M, Misiakos E, Manti C, Katsikas D, Skalkeas G. Diagnostic evaluation and surgical management of hydatid disease of the liver. *World J Surg* 1994; 18:859-65.
11. Lim CM, Shridhar I, Tan L, Cheah WK. Contrast CT in localization of acute lower gastrointestinal bleeding. *Asian J Surg* 2006; 29:92-4.
12. Sato N, Namieno T, Takahashi H, et al. A long-surviving patient with recurrences of hepatic alveolar echinococcosis after traumatic intra-abdominal rupture. *J Gastroenterol* 1996; 31:885-8.