

Unusual parapharyngeal lesion: aberrant thyroid gland

Feisal T K T, Prepageran N, Shahrizal T, Zulkiflee A B

ABSTRACT

An ectopic location of the thyroid gland usually occurs in the midline, starting anywhere from the tongue to the diaphragm. The occurrence of an ectopic thyroid gland in a non-midline site is extremely rare. We report a 32-year-old Malay woman with an aberrant thyroid gland presenting as a parapharyngeal lesion. She had a normally functioning thyroid gland. An ectopic thyroid should be considered as one of the differential diagnoses in the parapharyngeal mass.

Keywords: aberrant thyroid gland, ectopic thyroid, neck swelling, parapharyngeal lesion, thyroid gland

Singapore Med J 2008;49(5):e137-e138

INTRODUCTION

Parapharyngeal lesions usually arise from anatomical structures within the parapharyngeal space. The prestyloid space lesions frequently arise from salivary gland neoplasms, while poststyloid space lesions are commonly neurogenic in origin. We present a case of an unusual parapharyngeal lesion, i.e. an aberrant thyroid in the presence of a normal functioning thyroid gland, which is extremely rare.

CASE REPORT

A 32-year-old Malay woman presented with a slowly progressive painless swelling of the right neck for two years, with lethargy and occasional difficulty in breathing. The swelling gradually became firm over the years. There were no complaints of dysphagia, no constitutional or hyperthyroid symptoms. She was otherwise well with no other medical problems. There was no family history of thyroid disorders or malignancies. On examination, she was comfortable, and no dyspnoea or stridor was observed. There was an obvious firm, nontender immobile mass noted on the right side of the neck, which measured about 5 cm × 2 cm. The right pharyngeal wall was displaced medially by the mass. Only the right cervical lymph node was palpable, and it was nontender. Baseline blood investigations, which included a full blood count, renal profile and random blood glucose, were normal.

Computed tomography (CT) of the neck prior to admission had shown a mass in the parapharyngeal region. Magnetic resonance (MR) imaging of the neck and thorax showed a heterogenous mass with multiple areas of necrosis, seen at the right carotid bifurcation (Figs. 1 &

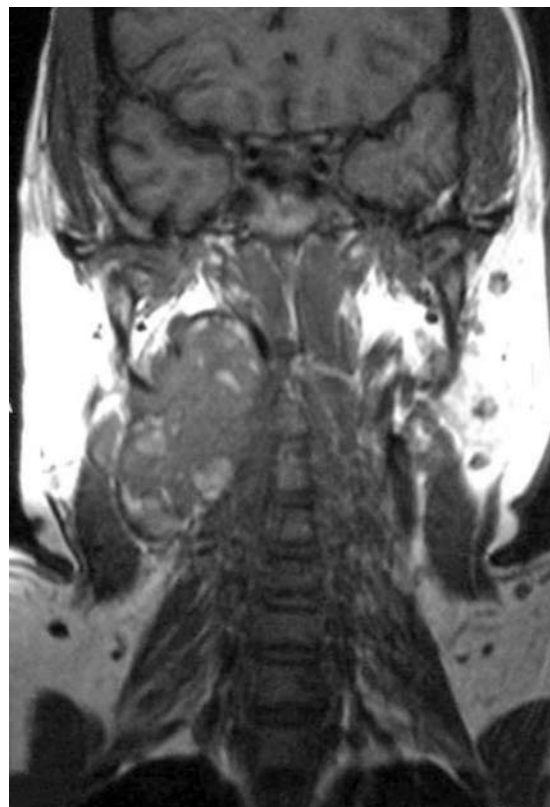

Fig. 1 Coronal T1-W MR image shows the ectopic thyroid tissue in the right parapharyngeal space at the level of the bifurcation of the common carotid artery.

2). The mass measured 5.5 cm × 2.2 cm axially and 6.0 cm cranio-caudally. The right parapharyngeal space was obliterated at the level of the hard palate (Fig. 3). The left parapharyngeal space was clear. There was also bilateral cervical lymphadenopathy noted. Following admission, an ultrasound-guided fine-needle aspiration cytology was performed to rule out a right carotid body tumour. Histology showed mainly thyroid type epithelial cells with background foamy macrophages, which suggested cystic degeneration in a colloid goitre. MR imaging and CT revealed a normal-looking thyroid in the normal pretracheal space.

A week later, a transcervical excision of the tumour was performed. The lesion was found to be adherent to the right common and external carotid arteries anteriorly, and to the right jugular veins posteriorly. The parapharyngeal extension of the mass was adherent to the right pterygoid muscles and the right internal carotid artery. There were three enlarged right cervical lymph nodes. Histological diagnosis of the tumour mass showed normal thyroid tissue with no malignancy noted. The enlarged lymph nodes showed reactive follicular hyperplasia. Postoperative

Department of
Otolaryngology,
University of Malaya
Medical Centre,
University of Malaya,
Kuala Lumpur 50603,
Malaysia

Feisal TKT, MBCh,
MS
Lecturer and Specialist

Prepageran N,
MBBS, FRCS
Consultant and
Associate Professor

Shahrizal T,
MBCh, MS
Lecturer and Specialist

Zulkiflee AB, MBBS
Trainee Lecturer and
Registrar

Correspondence to:
Dr Mohd Zulkiflee
Abu Bakar
Tel: (60) 3 7959 2062
Fax: (60) 3 7955 6554
Email: ab_zulkiflee@
yahoo.com

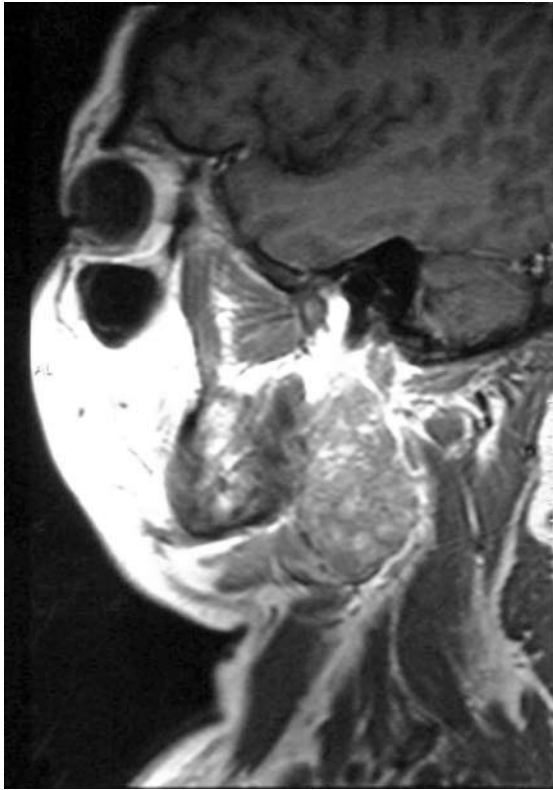


Fig. 2 Sagittal T1-W MR image shows the thyroid tissue extending posteriorly and laterally to the prevertebral muscle.

tests, immediately after surgery and six weeks later, for thyroid function, thyroid autoantibodies (which included thyroid peroxidase and antithyroglobulin), and serum calcium, were within normal limits.

DISCUSSION

A pair of anlagen is involved in the morphogenesis of the thyroid gland. These lateral thyroid anlagen should derive from the ultimo-branchial body, a descending diverticulum of the fourth pharyngeal pouch. They should become incorporated into the median thyroid anlagen to contribute a small proportion of the final thyroid parenchyma. Although the existence of the lateral thyroid anlagen has been a topic of controversy, its existence may explain the occurrence of nonmidline ectopic thyroid tissue in the neck.⁽¹⁾ Ectopia of the lateral anlagen in an unusual site may develop into an ectopic thyroid gland in the parapharyngeal space.⁽²⁾ To our knowledge, we are aware of only three published reports of ectopic thyroid in the pharynx.⁽²⁻⁴⁾

This patient had an ectopic parapharyngeal thyroid gland in the presence of a normal functioning thyroid. Her main presenting complaint had been a painless right neck swelling, which was slowly increasing in size. Following complete excision, no further intervention was planned as the tumour proved to be a benign thyroid tissue by histological diagnosis. It is important to exclude malignancy because a differential diagnosis of lateral ectopic thyroid is metastasis from a primary thyroid carcinoma.⁽⁵⁾

The treatment of ectopic thyroid depends on its location, size and on the presence of symptoms or

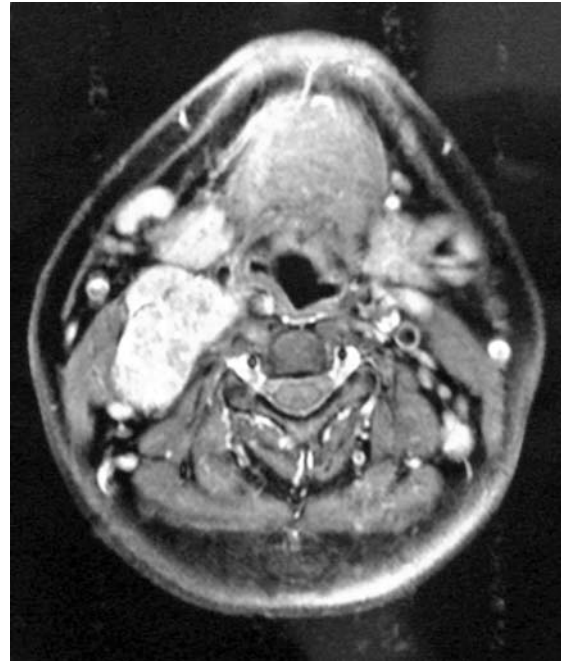

Fig. 3 Axial T2-W MR image shows that the parapharyngeal space is obliterated, pushing the tracheal wall medially, which may explain the patient's symptom of occasional dyspnoea.

complications. In a case of a nonfunctioning ectopic thyroid in the presence of a normal thyroid gland, the indication for surgery would depend on the patient's symptoms. Surgical excision was warranted in this patient as the mass effect by the tumour had caused dyspnoea and displaced the right nasopharynx. The transcervical approach to the tumour in this case allowed the surgeon a wider access to the parapharyngeal region for complete excision of the tumour mass. Postoperatively, the patient was biochemically euthyroid, thus rendering thyroid replacement unnecessary. This case illustrates the variable anatomical location of an ectopic thyroid, which should be considered in the differential diagnoses of neck tumours.

ACKNOWLEDGEMENTS

We would like to thank Prof R Raman, Prof K Gopala, and Prof J Amin, as well as our colleagues, for their continuous guidance and support. Special thanks to Dr Rahmat Omar for his photographic contribution.

REFERENCES

1. Gray H, Williams PL, ed. *Gray's Anatomy: The Anatomical Basis of Medicine and Surgery*. 38th ed. London: Churchill Livingstone, 1995.
2. Soscia A, Guerra G, Cinelli MP, et al. Parapharyngeal ectopic thyroid: the possible persistence of the lateral thyroid anlage. *Clinical case report. Surg Radiol Anat* 2004; 26:338-43.
3. Basak S, Basak O, Odabasi O, Düzcan E. Pharyngeal thyroid: a case report. *Br J Oral Maxillofac Surg* 1999; 37:61-3.
4. Shvartsman A Ia, Tolchinskiĭ V V, Meshcheriakova I u Ia. [Case of an aberrant thyroid gland in the peripharyngeal space]. *Vestn Otorinolaringol* 1978; 66-7. Russian.
5. Clay RC, Blackman SS Jr. Lateral aberrant thyroid: metastasis to lymph nodes from primary carcinoma of the thyroid gland. *Arch Surg* 1944; 48:223-8.