

# Unusual cause of seizures in Singapore: neurocysticercosis

Foo S S, Selvan V S, Clarke M J, Shen E J E

## ABSTRACT

Neurocysticercosis is the commonest cause for adult onset of seizures in developing countries, and is relatively uncommon in Singapore. However, with the influx of foreign workers from developing countries, we need to consider it as a differential diagnosis in our approach to adult-onset seizures in this group of patients. We describe a neurocysticercosis occurring in a 22-year-old Indian man who presented with a single episode of generalised tonic-clonic seizures. Magnetic resonance imaging of the brain showed a well-defined, hypointense lesion in the cortical and subcortical regions of the left frontal lobe with adjacent vasogenic oedema. Following contrast administration, a well-defined ring enhancement was noted, with suggestion of some internal enhancement. Imaging findings were suggestive of neurocysticercosis. Follow-up magnetic resonance imaging of the brain two weeks after treatment showed lesion resolution.

**Keywords:** adult-onset seizures, central nervous system infection, neurocysticercosis, *Taenia solium*, tapeworm infection

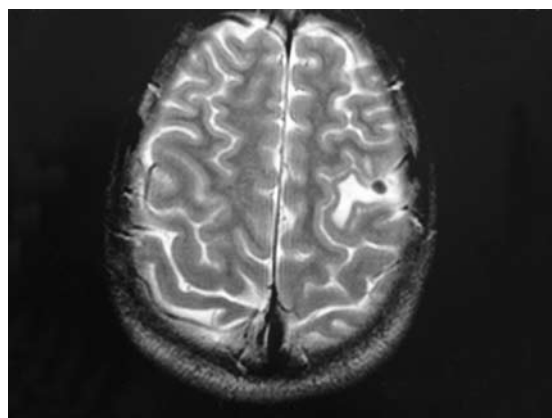
*Singapore Med J 2008;49(6):e147-e150*

## INTRODUCTION

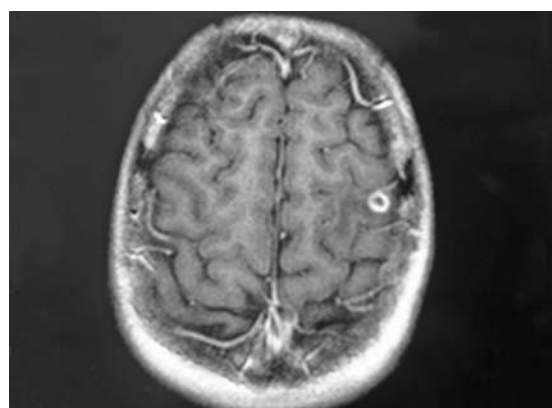
Adult-onset seizure is a common diagnostic challenge. Neurocysticercosis is found in many areas but is relatively uncommon in Singapore as a cause of adult-onset seizures. However, with the increasing number of immigrants from endemic areas, as well as the increasing prevalence of air travel, it should be considered as one of the differential diagnoses for adult-onset seizures.

## CASE REPORT

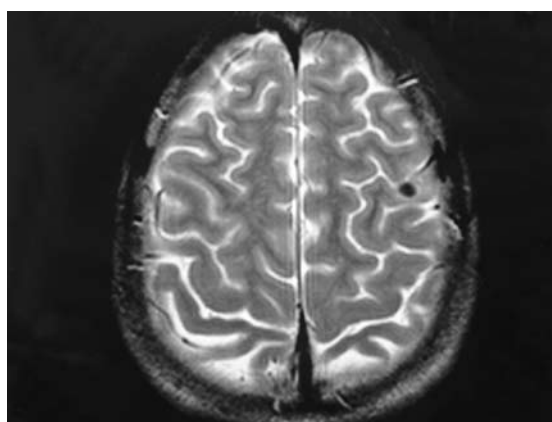
A 22-year-old Indian man presented with a single episode of generalised tonic-clonic seizures, and was otherwise asymptomatic. He had no relevant past or family history and was a nonsmoker who did not drink alcohol. He came from India but had no recent travel history. Physical examination (in particular, the neurological exam) was unremarkable. Investigations revealed an elevated leucocyte count at  $17.760 \times 10^6/L$ , with predominant neutrophilia. Electrolytes were normal. Electroencephalogram was normal. During his inpatient treatment, he underwent



**Fig. 1** Axial T2-weighted MR image of the brain shows a well-defined, hypointense lesion in the cortical and subcortical regions of the left frontal lobe with adjacent vasogenic oedema.



**Fig.2** Contrast-enhanced axial T1-weighted MR image of the brain shows a sharply-defined ring enhancement.



**Fig.3** Post-treatment axial T2-weighted image of the brain at two weeks shows resolution of the vasogenic oedema.

two further generalised tonic-clonic seizures, after which he was commenced on sodium valproate.

Contrast-enhanced computed tomography (CT) of his brain showed a small calcified focus within the

Department of  
Medicine,  
Alexandra Hospital,  
378 Alexandra Road,  
Singapore 159964

Foo SS, MBBS, MRCP  
Registrar

Selvan VS, MBBS, MD,  
MRCP  
Associate Consultant

Shen EJE, MBBS,  
FRACP  
Consultant

Department of  
Diagnostic Radiology

Clarke MJ, FRANZCR  
Consultant

**Correspondence to:**  
Dr V Senthamil Selvan  
Tel: (65) 6379 3461  
Fax: (65) 6379 3540  
Email: selvan\_senthamil@alexhosp.com.sg

**Table I. Diagnosis of neurocysticercosis.<sup>(3)</sup>****Absolute criteria:**

1. Histological demonstration of parasite from biopsy of the brain or spinal cord lesion.
2. Cystic lesions showing scolex on CT or MR imaging. The scolex is visualised as a bright nodule within the cyst, producing the "hole-with-dot" imaging.
3. Direct visualisation of subretinal parasites by fundoscopic examination.

**Major criteria:**

1. Lesions highly suggestive of neurocysticercosis on neuroimaging studies. These include cystic lesions without scolex, single or multiple ring- or nodular-enhancing lesions, and parenchymal round calcifications. Parenchymal cysts usually measure about 5–20 mm in diameter and are rounded. The common sites include the cerebral cortex or basal ganglia, and are less commonly found in the brainstem and cerebellum. The main differential diagnosis is low grade astrocytomas and cystic cerebral metastases, tuberculomas, pyogenic brain abscesses and mycotic granulomas. Parenchymal calcifications are also found in neurocysticercosis. The differential diagnosis for parenchymal calcifications would include metabolic disorders, vascular malformations, intracranial neoplasms, congenital anomalies, and a variety of infections. Another common neuroimaging finding in neurocysticercosis is the presence of intracranial lesions in different evolutive stages and the presence of two different highly-suggestive lesions are considered as two major diagnostic criteria.
2. Positive serum enzyme-linked immunoelectrotransfer blot (EITB) assay for the detection of antibodies to *T. solium* glycoprotein antigens. Many of the serology assays for human cysticercosis are limited in value because of poor sensitivity and specificity. The current assay of choice is EITB using partially-purified antigenic extracts. This assay has a documented specificity approaching 100% and a sensitivity of 94%–98% for patients with two or more cystic or enhancing lesions. The limitations of the assay included false negative results in patients with single intracranial cysticerci, in which fewer than 50% tested positive, and low sensitivity of specific antibody assays in patients with only calcified cysticerci. Positive assay results also included cysticercus infection in tissues other than neural, thus was not specific for neurocysticercosis.
3. Resolution of intracranial cystic lesion after treatment with albendazole or praziquantel.
4. Spontaneous resolution of small single enhancing lesions.

**Minor criteria:**

1. Lesion compatible with neurocysticercosis on neuroimaging. CT or MR imaging showing hydrocephalus or abnormal enhancement of the leptomeninges, and myelograms showing multiple filling defects in the column of contrast medium.
2. Clinical manifestation suggestive of neurocysticercosis. Seizures, focal neurological signs, intracranial hypertension, and dementia.
3. Positive CSF enzyme-linked immunosorbent assay (ELISA) for anticysticercal antibodies or antigens. Serum ELISA for anticysticercal antibodies and antigens has been disappointing. Higher sensitivity has been achieved with CSF ELISA. However, it is still limited by low specificity as it can also be positive in the presence of other CNS infections.
4. Cysticercosis outside CNS. The above included histologically-confirmed subcutaneous or muscular cysticercosis, plain radiograph films showing "cigar-shaped" soft-tissue calcifications, or direct visualisation of cysticerci in the anterior chamber of the eye.

**Epidemiological criteria:**

1. Evidence of a household contact with *Taenia solium* infection.
2. Individuals coming from or living in an area where cysticercosis is endemic.
3. History of frequent travel to disease-endemic areas.

left frontal lobe associated with a small amount of vasogenic oedema. Lumbar puncture results, including cerebrospinal fluid (CSF) examination, CSF acid-fast bacilli (AFB) smear and tuberculosis polymerase chain reaction were unexceptional. Mantoux test was 9 mm and early morning nasogastric aspirate for AFB smear was negative. The patient developed loose stools and three stool specimens showed ova of hookworm. Due to the abnormality seen on CT of the brain, a magnetic resonance (MR) imaging of the brain was performed; this showed a well-defined, hypointense lesion in the cortical and subcortical regions of the left frontal lobe with adjacent vasogenic oedema on T2-weighted images (Fig. 1). Following contrast administration, sharply-defined ring enhancement was noted and there was a suggestion of internal enhancement (Fig. 2). No significant pressure effects were noted. The above findings were suggestive of neurocysticercosis.

The patient was treated with mebendazole for hookworm

infection. He was given prednisolone 30 mg o.m. for three days and albendazole for neurocysticercosis. He was discharged well with no further seizures. On follow-up, the patient remained asymptomatic and seizure-free. Follow-up MR imaging of the brain two weeks after treatment showed resolution of the vasogenic oedema on T2-weighted images (Fig. 3).

**DISCUSSION**

Neurocysticercosis is a common cause of acquired epilepsy and hydrocephalus in the developing countries of Central and South America, sub-Saharan Africa, and East and South Asia.<sup>(1,2)</sup> Imported cases of cysticercosis have also been reported in nonendemic countries. Neurocysticercosis is caused by the larvae of the tapeworm, *Taenia solium*. It is the most common parasitic infection of the central nervous system. The *Taenia solium* has a complex life cycle that requires two hosts. Humans are the only known hosts for the adult

cestodes, and both pigs as well as humans can act as intermediate host for the larval form or cysticercus. Infection in humans can occur via: (1) ingestion of improperly-cooked infected pork, resulting in ingestion of viable cysticerci; (2) ingestion of food contaminated with *Taenia solium* eggs and (3) faecal-oral route in individuals harbouring the intestinal cestode. Once the eggs are ingested by humans, the embryos are released in the small intestine and the bowel wall is invaded. They are then disseminated haematogeneously to other tissues and develop into cysticerci over a period of three weeks to two months. There are four stages of cysticerci in the central nervous system, namely: Stage one: the vesicular stage refers to viable cysticerci with slight inflammatory changes in the surrounding tissues. The parasites have a transparent membrane, clear vesicular fluid and larva or scolex. Stage two: the colloidal stage occurs after cysticidal treatment or successful immune response. The transparent vesicular fluid in the vesicular stage is replaced by a viscous and turbid fluid, and the scolex dies. It is surrounded by a thick collagen capsule and surrounding brain parenchyma shows an intense astrocytic gliosis associated with microglial proliferation, diffuse oedema, neuronal degenerative changes and perivascular cuffing of lymphocytes. Stage three: the granular nodular stage results when the wall of the cyst thickens and the scolex is transformed into coarse mineralised granules. Stage four: at the last stage, also known as the calcified stage, the parasite becomes a mineralised nodule. The lesion seen on MR imaging of the brain in our patient is likely that of the colloidal stage.

Symptoms usually arise from an inflammatory response against the brain parenchymal cyst or from perilesional oedema around the calcified cysticercal granulomas. Patients commonly present with seizures; these are most often generalised tonic-clonic or simple partial seizures. Patients can also present with focal neurological findings resembling that of a brain tumour. Patients may also present with a cysticercosis-related stroke, caused by inflammatory changes in the wall of intracranial arteries in the local vicinity of the cysticerci. This is usually a focal process characterised by thickening of the adventitia, fibrosis of the media, and endothelial hyperplasia and may affect intracranial vessels of different sizes. Other presentations include: (1) hydrocephalus resulting from arachnoiditis, granular ependymitis or ventricular cysts, and (2) decreased visual acuity or visual field defects due to eye involvement.

The diagnosis for neurocysticercosis has remained difficult as the clinical manifestations are nonspecific, neuroimaging findings are not pathognomonic, and serological tests have low sensitivity and specificity. A panel of experts during a consensus meeting in Peru in

2000, agreed upon common criteria for the diagnosis of neurocysticercosis.<sup>(3)</sup> The proposed criteria (Table I)<sup>(3)</sup> were based on four categories, which were stratified according to their diagnostic strength — absolute, major, minor, and epidemiological. Absolute criteria allow unequivocal diagnosis of neurocysticercosis, major criteria strongly suggest the diagnosis but cannot be used alone to confirm the disease, minor criteria are frequent but nonspecific manifestations of the disease, and epidemiological criteria refer to circumstantial evidence that favour the diagnosis of cysticercosis.

A patient has definitive neurocysticercosis when he has one absolute criterion or two major criteria with one minor and one epidemiological criterion. A probable diagnosis is made when the following criteria is met: one major with two minor, one major with one minor and one epidemiological, or three minor with one epidemiological criteria.

The treatment for neurocysticercosis depends on the number and location of lesions, viability of parasites and clinical symptoms.<sup>(4,5)</sup> In an asymptomatic patient with incidental findings of a nonviable cysticercus lesion in the brain, antiparasitic treatment is not proven to show any benefit.<sup>(4)</sup> In symptomatic neurocysticercosis, treatment can include symptomatic therapy, specific antiparasitic therapy and surgery. The treatment needs to be individualised as some clinical forms of neurocysticercosis carry a higher risk of complication or death. Pharmacological treatment can include antiparasitic drugs, antiepileptic drugs and anti-inflammatory drugs. Surgical procedures, such as open surgery for large cysts or cysts in ventricles, were previously the mainstay of treatment before the advent of antiparasitic drugs. Surgical therapy includes ventriculoperitoneal shunt insertion and excision of certain cyst, based on size, location and complications.

Albendazole and praziquantel are currently the choice of antiparasitic drugs.<sup>(5)</sup> Antiparasitic drugs are not routinely used for all cases of neurocysticercosis. The role of antiparasitic drugs in a single enhancing lesion remains ambiguous.<sup>(2)</sup> For intraparenchymal neurocysticercosis with a viable cyst, the recommended dose for albendazole is 15 mg/kg/day for seven days or more with oral dexamethasone (0.1 mg/kg/day) for at least the first week of treatment. This regimen is associated with destruction of some cysts with reduction of seizures by 40%. An alternative antiparasitic agent is praziquantel, which it can be given as a single day regimen of three doses 25 mg/kg at two-hour intervals or a 15-day regimen of 50–100 mg/kg/day. However, the serum level of praziquantel can be reduced when given concurrently with dexamethasone, and it also has a slightly lower cysticidal efficacy compared to

albendazole.<sup>(5)</sup> There is no evidence in treating dead, calcified cysts with antiparasitic agents. Their role in degenerating cysticerci is also controversial.

Some experts argue that routine use of antiparasitic agents in single enhancing lesions result in faster radiological resolution, whereas others claim that antiparasitic agents should be reserved for cases in which antiepileptic therapy cannot be adequately monitored or risks of adverse outcomes from seizures are high. In cases with multiple cysts or cysticercal encephalitis, the risk of neurological deterioration with an inflammatory response due to antiparasitic agent therapy, may outweigh the benefit of treatment. In such cases, measures should be taken to manage the oedema or raised intracranial hypertension, such as with ventricular shunts and dexamethasone prior to antiparasitic treatment. The management of neurocysticercosis also differ depending on the location and type of cyst. Subarachnoid neurocysticercosis is associated with many complications, including mass effect, communicating hydrocephalus, vasculitis with strokes and basilar meningitis. Hence, many experts would treat subarachnoid neurocysticercosis with antiparasitic agents, with steroids as a supplement to reduce complications from any inflammatory reaction to the antiparasitic therapy. There are no controlled trials in the management of subarachnoid neurocysticercosis. However, there was a case series that showed a combination of antiparasitic agents with pretreatment corticosteroids and surgical shunt improved prognosis compared to older studies.<sup>(5)</sup>

The mainstay of treatment for seizures due to neurocysticercosis remains antiepileptic drugs with or without antiparasitic drugs. The investigators of a double-blinded, placebo-controlled trial, involving 120 patients with living cysticerci in the brain and seizures treated with antiepileptic drugs, recommended treatment with

albendazole. The patients in the study were randomly assigned to receive either 800 mg of albendazole per day and 6 mg of dexamethasone per day for 10 days, or two placebos. The results showed more of the intracranial cystic lesions resolved in the albendazole group, when compared with the control group, and a significant reduction in seizures with generalisation.<sup>(6)</sup> The appropriate duration of treatment with antiepileptic drugs remains uncertain. The presence of residual calcification in the brain, and patients with both recurrent seizures and multiple cysts before albendazole therapy, are risk factors for seizure relapse after withdrawal of antiepileptic drugs.<sup>(7)</sup>

Neurocysticercosis was previously a rare cause of seizures in Singapore. Diagnosis can only be made if there is clinical suspicion of the disease. With increased ease of travelling and increasing numbers of migrants, neurocysticercosis may become a more common cause of seizures in Singapore.

## REFERENCES

1. Del Brutto OH, Santibañez R, Noboa CA, et al. Epilepsy due to neurocysticercosis: analysis of 203 patients. *Neurology* 1992; 42:389-92.
2. Del Brutto OH. The use of albendazole in patients with single lesions enhanced on contrast CT. *N Engl J Med* 1993; 328:356-7.
3. Del Brutto OH, Rajshekhar V, White AC Jr, et al. Proposed diagnostic criteria for neurocysticercosis. *Neurology* 2001; 57:177-83.
4. García HH, White AC Jr, Nash TE, et al. Current consensus guidelines for treatment of neurocysticercosis. *Clin Microbiol Rev* 2002; 15:747-56.
5. Garcia HH, Del Brutto OH, Nash TE, et al. New concepts in the diagnosis and management of neurocysticercosis (*Taenia Solium*). *Am J Trop Med Hyg* 2005; 72:3-9.
6. Garcia HH, Pretell EJ, Gilman RH, et al. A trial of antiparasitic treatment to reduce the rate of seizures due to cerebral cysticercosis. *N Engl J Med* 2004; 350:249-58.
7. Del Brutto OH. Prognostic factors for seizure recurrence after withdrawal of antiepileptic drugs in patients with neurocysticercosis. *Neurology* 1994; 44:1706-9.