

CME Article

Ultrasonographical diagnosis of acute gynaecological pain

Tan B P, Ong C L

ABSTRACT

Acute pelvic pain is a common presentation in women. There are a myriad of causes, both gynaecological and non-gynaecological in origin. Ultrasonography is well-established as the primary initial investigation of choice. Familiarity with the imaging features of the commonly-associated conditions aids in the rapid diagnosis, and immediate management of the patient. This article provides a pictorial review of the common gynaecological causes of pelvic pain.

Keywords: acute pelvic pain, adnexal torsion, ectopic pregnancy, pelvic inflammatory disease, ultrasonography

Singapore Med J 2008; 49(6): 511-516

INTRODUCTION

Acute pelvic pain accounts for 10%–40% of all gynaecological visits in the USA.⁽¹⁾ Most studies define acute pain as having a duration of ≤ 3 –6 months. Pain lasting six months or more is classified as chronic in nature. Transvaginal ultrasonography (TVUS) is the mainstay of imaging evaluation at initial presentation. Its strengths include absence of radiation, rapid availability of machines in hospitals, and excellent visualisation of the pelvic organs. Improvements made in image quality have facilitated the rapid and accurate diagnosis of the majority of gynaecological causes of acute pelvic pain. The ability to confirm the presence of a gynaecological lesion is a valuable one, since it allows for definitive management, which may include surgical intervention. Should there not be a cause evident on TVUS, efforts could be directed towards looking for a non-gynaecological cause. Occasionally, surgical pathologies, such as acute appendicitis or diverticulitis, may manifest themselves on the scan.

PELVIC INFLAMMATORY DISEASE

Pelvic inflammatory disease involves a wide spectrum of diseases which include endometritis, salpingitis, perioophoritis and tubo-ovarian abscess. The clinical presentation frequently includes pain, fever and purulent vaginal discharge. The main imaging feature is a thickened tubular adnexal structure representing an inflamed fallopian tube (Fig. 1). The appearance of the oedematous walls and endosalpingeal folds has been described as the “cogwheel sign”.⁽²⁾ If its ends are blocked, the fallopian tube dilates and fills up with fluid (hydrosalpinx), and may

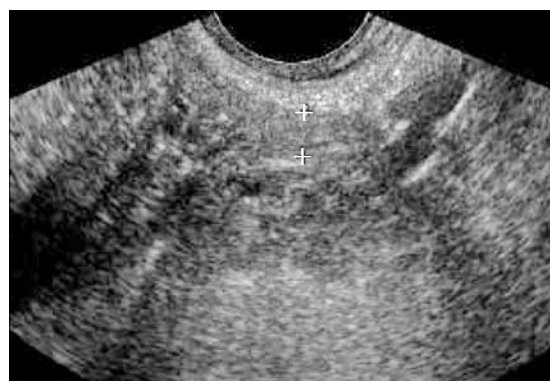


Fig. 1 TVUS image of salpingitis in pelvic inflammatory disease. The thickened tubular structure (marked out by calipers) in the right adnexa represents an inflamed fallopian tube.

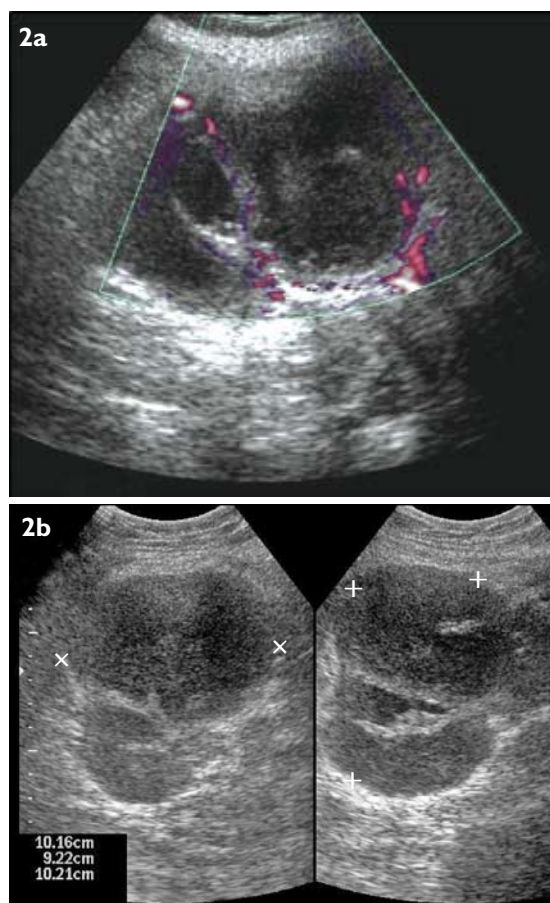


Fig. 2 TVUS image of a complex right adnexal structure shows (a) internal septations that represent an ovarian abscess. (b) The adjacent tubular structure is a pyosalpinx with the distended fallopian tube containing low-level internal echoes (pus).

contain blood (haematosalpinx) or pus (pyosalpinx) (Fig. 2b). Other features include increased adnexal volume, periovarian inflammation in the form of indistinct ovarian margins, increased echogenicity of adnexal fat and increased vascularity.⁽³⁾ Disease progression leads to development of a tubo-ovarian complex or abscess (Fig. 2)

Department of
Diagnostic Imaging,
KK Women's and
Children's Hospital,
100 Bukit Timah
Road,
Singapore 229899

Tan BP, MBBS,
FRCR
Registrar

Ong CL, MBBS,
FRCR
Senior Consultant

Correspondence to:
Dr Bien-Peng Tan
Tel: (65) 6357 8111
Fax: (65) 6357 8112
Email: bienpeng@
gmail.com

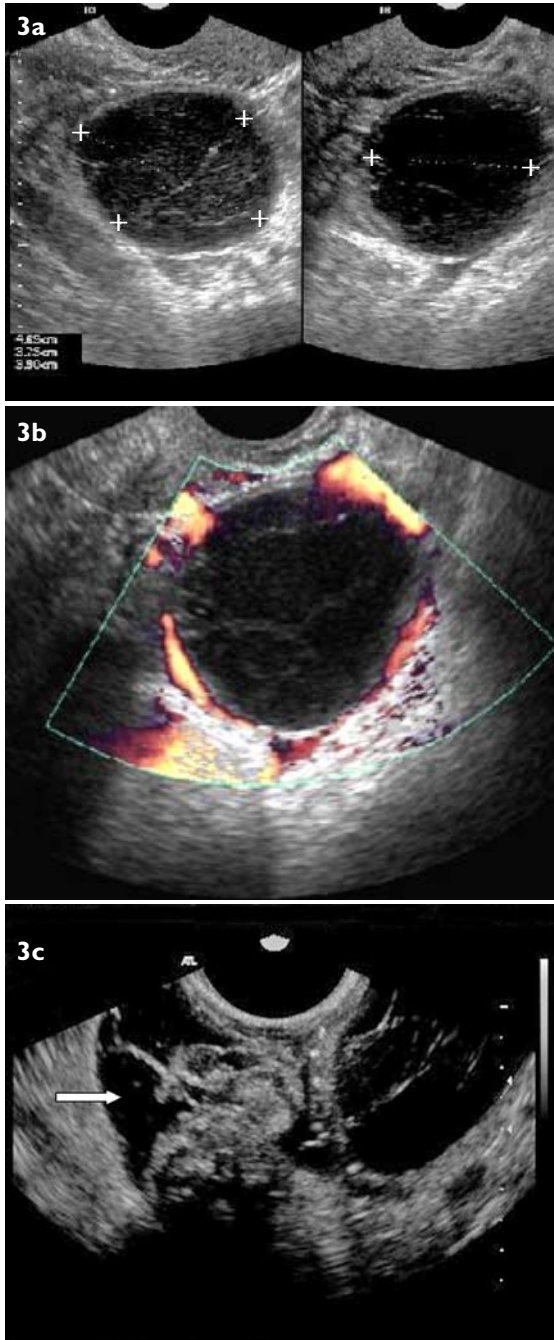


Fig. 3 TVUS image of a haemorrhagic corpus luteum shows (a) "spidery" internal reticular strands, low-level internal echoes on grey-scale ultrasonography (US), and (b) a vascular rim on colour Doppler US. (c) Following rupture, the cyst is seen together with varying amounts of adnexal fluid (arrow).

characterised by multiple thick-walled, dilated fluid-filled structures.⁽³⁾ The presence of fluid-debris and air-fluid levels are also recognised features. Drainage of the pelvic abscess via ultrasonographic guidance then becomes a useful option.

OVARIAN CYST ACCIDENT

An ovarian cyst is a common occurrence, and in premenopausal patients, they are often the result of failure of involution of a follicle or corpus luteum. Pressure on the

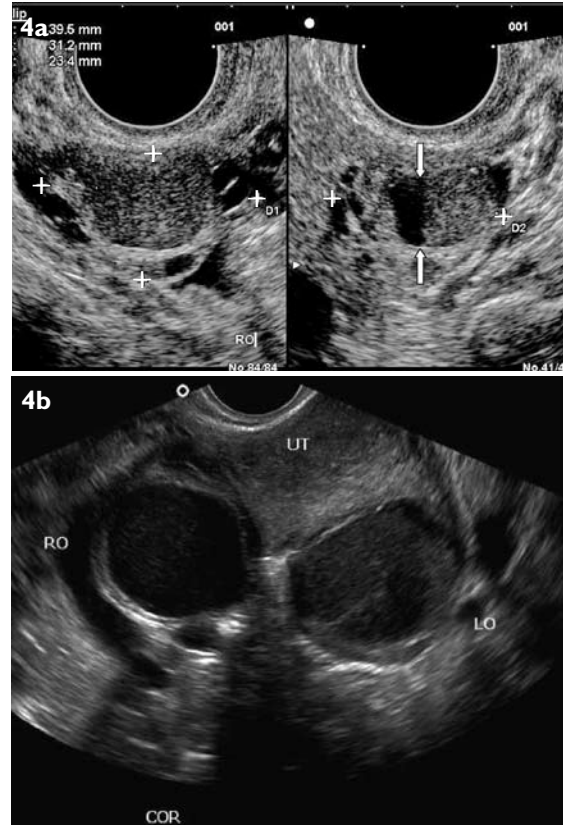


Fig. 4 TVUS image of endometrioma. (a) Endometrioma mimics a haemorrhagic cyst with typical features of homogeneous internal echoes (ground glass appearance). Note the fluid-fluid level (arrows) within. (b) When bilateral, they may be in close contact and are termed "kissing ovaries".

cyst by the probe eliciting tenderness could indicate it as a cause of the pain.⁽⁴⁾ A haemorrhagic ovarian cyst is common and it can appear diffuse, contain a fluid-debris level, or present with a reticular "spider web" appearance⁽⁵⁾ (Fig. 3). This frequently resolves spontaneously and may be followed-up in 6–8 weeks to confirm resolution.⁽⁴⁾ Occasionally, cyst rupture occurs with an acute onset of pain. A collapsed cyst and echogenic blood in the pelvis may then be readily detected on TVUS. An endometrioma (Fig. 4) is more often associated with chronic pain. However, haemorrhage into an endometrioma can lead to severe acute pain.⁽⁴⁾ Endometriomas are less likely to undergo torsion as they are often fixed and hence less mobile.⁽⁴⁾

ADNEXAL TORSION

Adnexal torsion can involve the ovaries or fallopian tubes or both. It is a surgical emergency that requires prompt diagnosis and definitive surgical treatment. Ovarian torsion arises from partial or complete rotation of the ovarian pedicle about its axis. This impairs lymphatic and venous drainage and subsequently, arterial supply to the ovary.⁽⁶⁾ Ovarian torsion is known to occur more often on the right side.⁽⁷⁾ Predisposing factors include ovarian enlargement due to ovarian cysts, which could occur from hyperstimulation or the presence of a benign ovarian

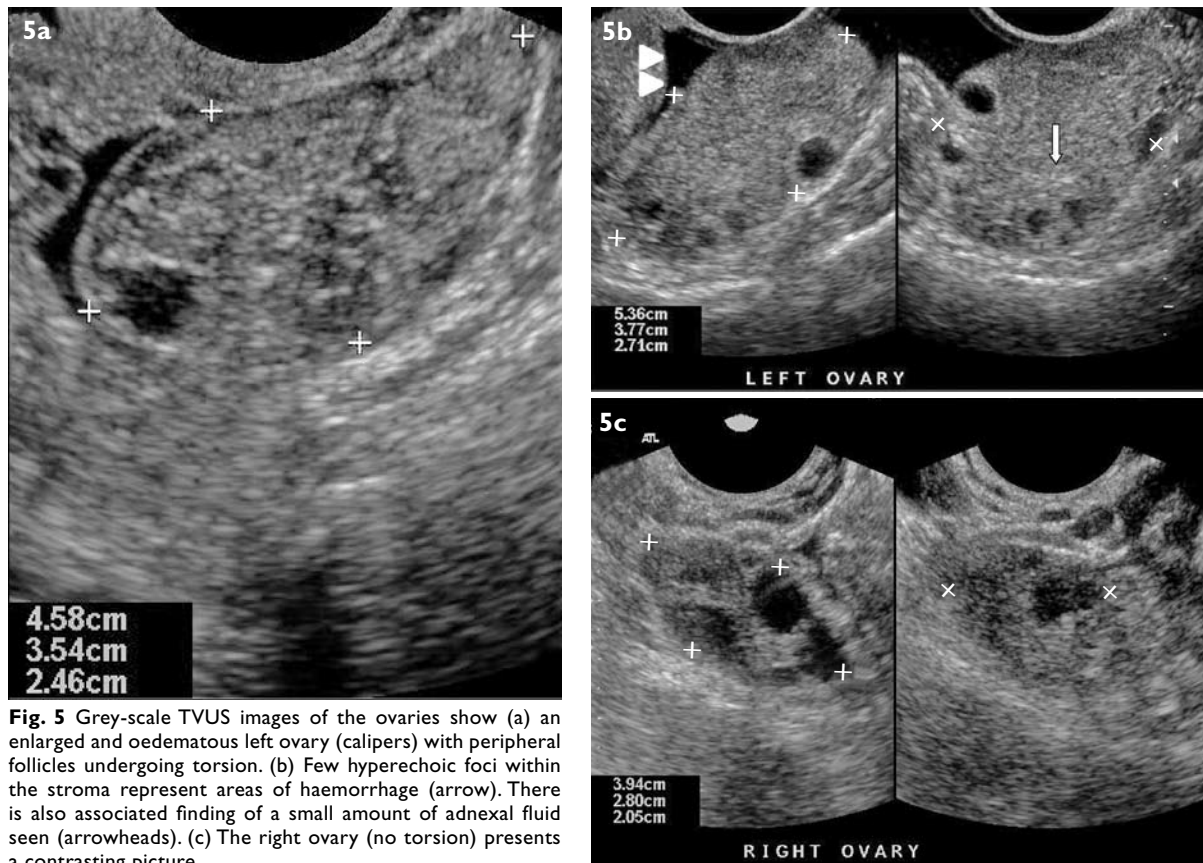


Fig. 5 Grey-scale TVUS images of the ovaries show (a) an enlarged and oedematous left ovary (calipers) with peripheral follicles undergoing torsion. (b) Few hyperechoic foci within the stroma represent areas of haemorrhage (arrow). There is also associated finding of a small amount of adnexal fluid seen (arrowheads). (c) The right ovary (no torsion) presents a contrasting picture.

neoplasm. Complex cystic masses are present more often in the prepubertal than pubertal population with adnexal torsion,⁽⁸⁾ with the latter having enlarged ovaries that predispose to torsion.

Ultrasonographic grey-scale features of torsion vary depending on the degree of ischaemia, infarction and duration.⁽⁹⁾ A commonly-described finding is heterogeneous echogenicity of the enlarged ovarian stroma with peripheral follicles (Fig. 5). Hyperechoic foci within the stroma may result from haemorrhage, and cystic areas could develop soon after infarction. Free fluid within the pelvis and surrounding the ovaries may also be observed (Fig. 5). In cases of subtorsion, where the twisting is less than 360°, dilatation of the periovarian vessels may be the only clue, as the ovary may demonstrate normal features.⁽¹⁰⁾

Visualisation of a twisted vascular pedicle (Fig. 6) has been described as the definitive sign in the diagnosis of adnexal torsion.⁽¹¹⁾ This twisted vascular pedicle corresponds to the broad ligament, fallopian tube, and adnexal and ovarian branches of the uterine artery and vein.⁽¹²⁾ On grey-scale imaging, this has a variable appearance, generally consisting of vessels wrapped around a central axis. This may appear hypoechoic or hyperechoic, and can mimic other conditions. As the ovary has dual arterial supply, some degree of torsion may occur even with arterial flow on Doppler interrogation,

since only one vessel may be occluded in early torsion.⁽⁸⁾ Other studies⁽¹¹⁻¹³⁾ show that viability of the ovary can be predicted based on the presence of both arterial and venous blood flow. Absence of arterial blood flow alone is a predictor of ovarian nonviability.

ECTOPIC PREGNANCY

Ectopic pregnancy is defined as any pregnancy occurring outside the uterine cavity. The vast majority of ectopic pregnancies (95%) occur within the fallopian tube, and the rest (5%) are found in ovarian, cervical, interstitial (cornual) and abdominal locations.⁽⁸⁾ Live embryos found outside the uterus are seen in only 8%–26% of ectopic pregnancies and remain the only pathognomonic finding.⁽³⁾ TVUS has a pivotal role and is usually performed in conjunction with serum beta-human chorionic gonadotrophin measurements. The visualisation of an intrauterine pregnancy virtually excludes the presence of an ectopic pregnancy, although a heterotopic pregnancy at 1/7,000 is by far an exceedingly rare occurrence.⁽¹⁴⁾

The most common finding of ectopic pregnancy in the adnexa is a round or elongated extraovarian mass seen in 89%–100% of cases (Fig. 7). This is followed by a “tubal ring”, which is a sac-like structure with a thick rind formed by a gestational sac within a fallopian tube (40%–68% of cases) (Fig. 8). The occurrence of this sign with a positive urine pregnancy test has a reported specificity of 92.2%–

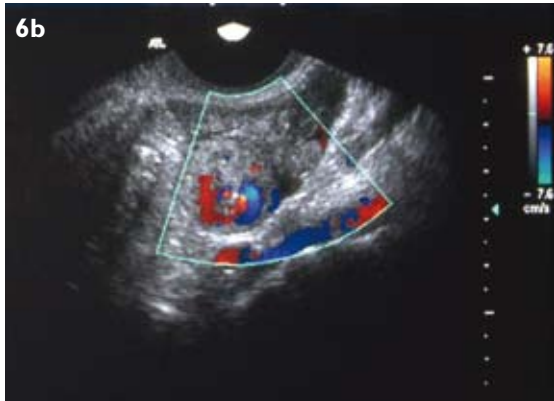
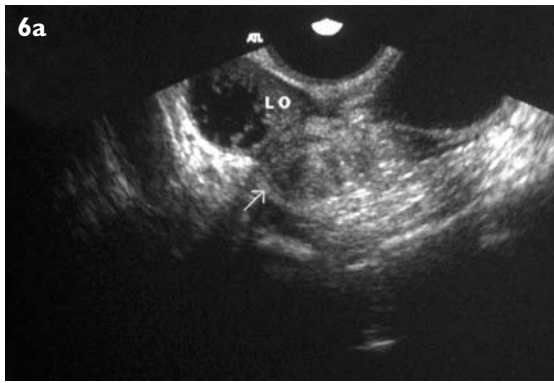


Fig. 6 (a) Grey-scale TVUS image shows a torsional right adnexa (arrow) containing a hypoechoic "whirl" of vessels. (b) This is well-demonstrated with colour Doppler TVUS imaging as the "whirlpool sign". A small amount of adnexal fluid is also present.

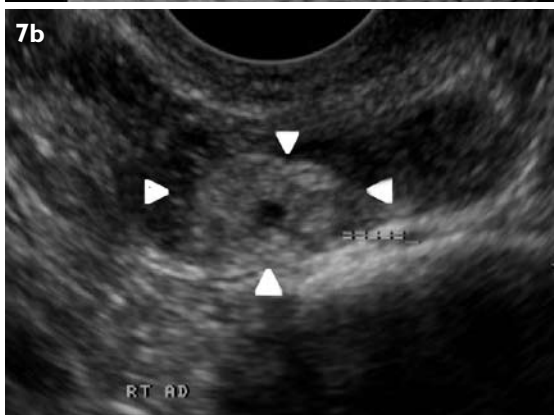
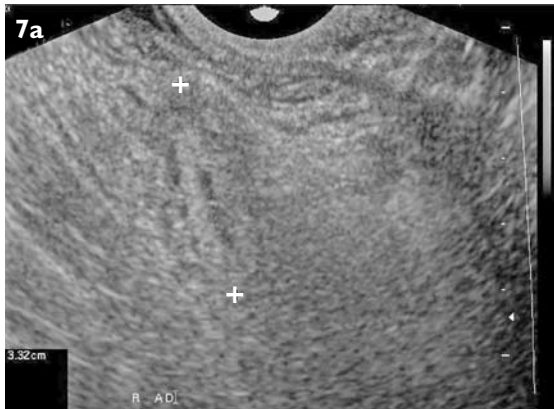

Fig. 7 TVUS images show (a) a nonspecific solid echogenic ovoid mass in the right adnexa (calipers) which was separate from the right ovary. This was eventually found, on laparoscopy, to be a ruptured ectopic pregnancy. (b) Another ruptured tubal ectopic pregnancy with an echogenic trophoblastic ring (arrowheads) surrounded by fluid.

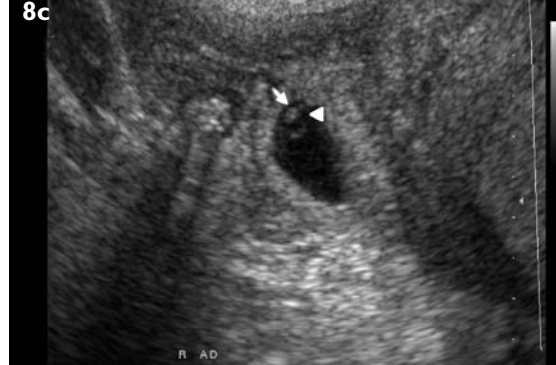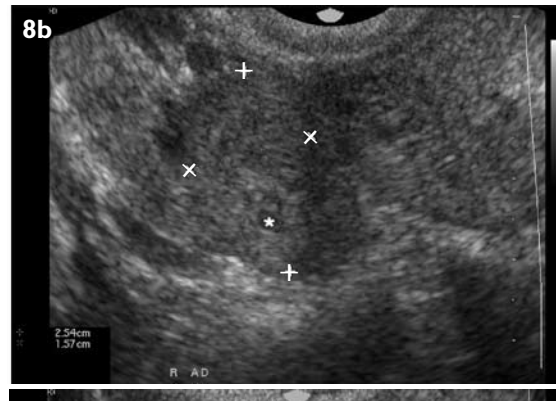
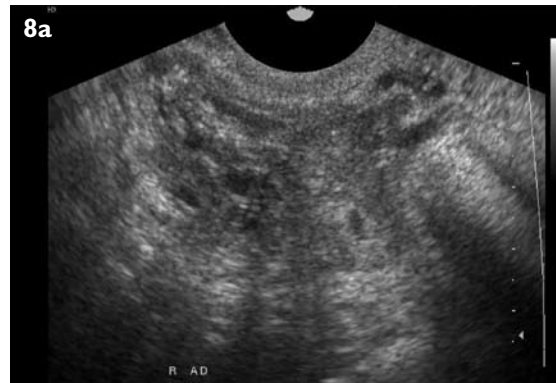


Fig. 8 (a,b) TVUS images show a right "adnexal ring" that is formed by a gestational sac (asterisk) within the fallopian tube. (c) An enlarged view shows the yolk sac (arrowhead) and foetal pole (arrow).

98.8%.⁽¹⁴⁾ The presence of vascularity helps differentiate it from a blood clot or haematosalpinx,⁽¹⁵⁾ but not from a corpus luteum cyst, which shares the commonly-described "ring of fire" appearance on colour Doppler US.

Differentiating an exophytic corpus luteum cyst from an ectopic pregnancy is thus difficult, given the former's varied appearances depending on the presence and age of the haemorrhagic complication. It has been suggested that the relative hypoechoic appearance of the wall of the corpus luteum cyst helps in distinguishing it from a tubal ectopic pregnancy.⁽¹⁶⁾ Alternatively, if gently tapping on the ovary with the transducer elicits independent movement of the ovary, a tubal ectopic pregnancy is less likely, given the low incidence of ovarian pregnancies⁽¹⁷⁾ (0.15%–3% of all ectopic pregnancies). A study by Atri comparing resistive indices of the corpus luteum cyst and tubal ectopic pregnancies showed that values < 0.39 and

> 0.7 have a specificity of 100% and a positive predictive value of 100% for ectopic pregnancy.⁽¹⁸⁾ Other findings indicative of ectopic pregnancy include the presence of free pelvic fluid or blood clots in the pelvis; these are important additional signs to look out for. Interstitial pregnancy may be diagnosed when the endometrial lining is seen extending to the margins of the interstitial gestational sac.⁽¹⁹⁾

MISCELLANEOUS CAUSES

Other miscellaneous causes of acute gynaecological pelvic pain include pain from torsion of a pedunculated fibroid. A degenerating fibroid undergoing acute necrosis may also be responsible for acute pelvic pain. Hypoechoic areas within the fibroid would be a feature to look out for.

CONCLUSION

With the many causes of acute pelvic pain, the use of US can be crucial in the initial assessment for rapid and accurate diagnosis; several of these causes require prompt surgical intervention. TVUS is a readily available tool in most institutions and is well-established as the imaging modality of choice.

REFERENCES

1. Klock S. Psychosomatic issues in obstetrics and gynecology. In: Ryan KJ, Barbieri RL, eds. *Gynecology Principles and Practice*. St Louis, MO: Mosby, 1995: 399-402.
2. Bellah RD, Rosenberg HK. Transvaginal ultrasound in a children's hospital: is it worthwhile? *Pediatr Radiol* 1991; 21:570-4.
3. Bau A, Atri M. Acute female pelvic pain: ultrasound evaluation. *Semin Ultrasound CT MR* 2000; 21:78-93.
4. Okaro E, Valentin L. The role of ultrasound in the management of women with acute and chronic pelvic pain. *Best Pract Res Clin Obstet Gynaecol* 2004; 18:105-23.
5. Parsons AK. Imaging the human corpus luteum. *J Ultrasound Med* 2001; 20:811-9.
6. Salem S. Gynecologic ultrasound. In: Rumack CM, Wilson SR, Charboneau JW, Johnson JM, eds. *Diagnostic Ultrasound*. 3rd ed. St Louis, MO: Mosby, 2005: 562.
7. Holschneider CH. Surgical disease and disorders in pregnancy. In: DeCorney A, Nathan L, eds. *Current Obstetric and Gynecologic Diagnosis and Treatment*. 9th ed. New York: McGraw-Hill, 2003.
8. Stark JE, Siegel MJ. Ovarian torsion in prepubertal and pubertal girls: sonographic findings. *Am J Roentgenol* 1994; 163:1479-82.
9. Rosado WM Jr, Trambert MA, Gosink BB, Pretorius DH. Adnexal torsion: diagnosis by using Doppler sonography. *Am J Roentgenol* 1992; 159:1251-3.
10. Shalev J, Maschiach R, Bar-Hava I, et al. Subtorsion of the ovary: sonographic features and clinical management. *J Ultrasound Med* 2001; 20:849-54.
11. Lee EJ, Kwon HC, Joo HJ, Suh JH, Fleischer AC. Diagnosis of ovarian torsion with color Doppler sonography: depiction of twisted vascular pedicle. *J Ultrasound Med* 1998; 17:83-9.
12. Vijayaraghavan SB. Sonographic whirlpool sign in ovarian torsion. *J Ultrasound Med* 2004; 23:1643-9.
13. Fleischer AC, Stein SM, Cullinan JA, Warner MA. Color Doppler sonography of adnexal torsion. *J Ultrasound Med* 1995; 14:523-8.
14. Hann LE, Bachman DM, McArdle CR. Coexistent intrauterine and ectopic pregnancy: a reevaluation. *Radiology* 1984; 152:151-4.
15. Atri M, Leduc C, Gillett P, et al. Role of endovaginal sonography in the diagnosis and management of ectopic pregnancy. *Radiographics* 1996; 16:755-74.
16. Frates MC, Visweswaran A, Laing FC. Comparison of tubal ring and corpus luteum echogenicities: a useful differentiating characteristic. *J Ultrasound Med* 2001; 20:27-31.
17. Webb EM, Green GE, Scoutt LM. Adnexal mass with pelvic pain. *Radiol Clin North Am* 2004; 42:329-48.
18. Atri M. Ectopic pregnancy versus corpus luteum cyst revisited: best Doppler predictors. *J Ultrasound Med* 2003; 22:1181-4.
19. Ackerman TE, Levi CS, Dashefsky SM, Holt SC, Lindsay DJ. Interstitial line: sonographic finding in interstitial (cornual) ectopic pregnancy. *Radiology* 1993; 189:83-7.

SINGAPORE MEDICAL COUNCIL CATEGORY 3B CME PROGRAMME
Multiple Choice Questions (Code SMJ 200806B)

	True	False
Question 1. The following are ultrasonographical features of pelvic inflammatory disease:		
(a) Thickened tubular adnexal structure representing an inflamed fallopian tube.	<input type="checkbox"/>	<input type="checkbox"/>
(b) Dilated fallopian tube with oedematous endosalpingeal folds.	<input type="checkbox"/>	<input type="checkbox"/>
(c) Decreased echogenicity of ovarian fat.	<input type="checkbox"/>	<input type="checkbox"/>
(d) Decreased adnexal vascularity.	<input type="checkbox"/>	<input type="checkbox"/>
Question 2. Concerning ovarian cyst accidents:		
(a) Pressure on the cyst with the ultrasound probe could elicit tenderness.	<input type="checkbox"/>	<input type="checkbox"/>
(b) A comet tail artefact is frequently seen.	<input type="checkbox"/>	<input type="checkbox"/>
(c) A reticular "spider web" appearance is commonly seen in haemorrhagic cysts.	<input type="checkbox"/>	<input type="checkbox"/>
(d) They do not resolve spontaneously.	<input type="checkbox"/>	<input type="checkbox"/>
Question 3. In adnexal torsion:		
(a) It involves only the ovaries.	<input type="checkbox"/>	<input type="checkbox"/>
(b) It is predisposed by ovarian neoplasm.	<input type="checkbox"/>	<input type="checkbox"/>
(c) Visualisation of a twisted vascular pedicle is a definitive sign.	<input type="checkbox"/>	<input type="checkbox"/>
(d) Absence of venous blood flow alone is a predictor of ovarian nonviability.	<input type="checkbox"/>	<input type="checkbox"/>
Question 4. Regarding ectopic pregnancies:		
(a) 95% occur in the fallopian tubes.	<input type="checkbox"/>	<input type="checkbox"/>
(b) Live embryos outside of the uterus are seen in the majority of cases.	<input type="checkbox"/>	<input type="checkbox"/>
(c) Visualisation of an intrauterine pregnancy excludes the diagnosis of an ectopic pregnancy.	<input type="checkbox"/>	<input type="checkbox"/>
(d) It may be differentiated easily from a corpus luteum cyst.	<input type="checkbox"/>	<input type="checkbox"/>
Question 5. The following are ultrasonographical features of an ectopic pregnancy:		
(a) "Ring of fire" appearance on colour Doppler ultrasonography.	<input type="checkbox"/>	<input type="checkbox"/>
(b) Presence of free pelvic fluid.	<input type="checkbox"/>	<input type="checkbox"/>
(c) Round or ovoid mass in the adnexa.	<input type="checkbox"/>	<input type="checkbox"/>
(d) Sac-like structure with a thick rind, or "tubal ring".	<input type="checkbox"/>	<input type="checkbox"/>

Doctor's particulars:

Name in full: _____

MCR number: _____ Specialty: _____

Email address: _____

SUBMISSION INSTRUCTIONS:

(1) Log on at the SMJ website: www.sma.org.sg/cme/smj and select the appropriate set of questions. (2) Select your answers and provide your name, email address and MCR number. Click on "Submit answers" to submit.

RESULTS:

(1) Answers will be published in the SMJ August 2008 issue. (2) The MCR numbers of successful candidates will be posted online at www.sma.org.sg/cme/smj by 15 August 2008. (3) All online submissions will receive an automatic email acknowledgment. (4) Passing mark is 60%. No mark will be deducted for incorrect answers. (5) The SMJ editorial office will submit the list of successful candidates to the Singapore Medical Council.

Deadline for submission: (June 2008 SMJ 3B CME programme): 12 noon, 25 July 2008.