

# Recurrent paediatric supratentorial extraventricular ependymoma associated with genetic mutation at exon 4 of p53 gene

Ghani A R I, Abdullah J M, Ghazali M, Ahmad F, Ahmad K A K, Madhavan M

## ABSTRACT

Recurrent supratentorial extraventricular ependymoma in a four-year-old Malay boy treated twice surgically in combination with cranial radiotherapy is reported. He presented with symptoms of raised intracranial pressure and a history of focal seizure. Computed tomography of the brain showed a left supratentorial extraventricular cystic lesion causing a mass effect. The tumour histology was ependymoma (WHO grade II). The clinical course, radiological characteristics and management of this tumour are discussed. Molecular genetic analysis of p53 and p27 genes revealed substitution of nucleotide G to C at location nucleotide 12139, exon 4 of gene p53. No alteration was detected at exon 5–6 and 8 of p53 gene and exon 1 and 2 of p27 gene.

**Keywords:** extraventricular ependymoma, paediatric cerebral tumour, supratentorial ependymoma, tumour genetic analysis

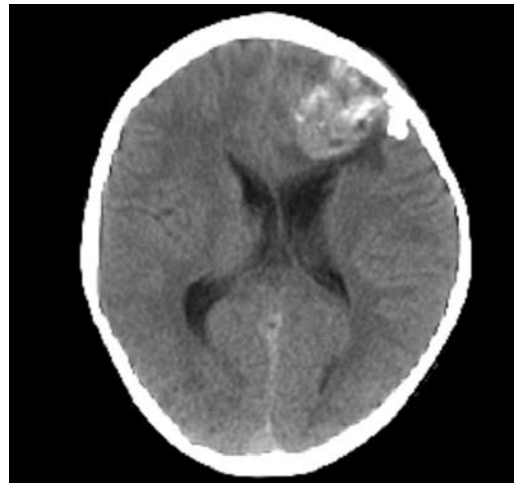
*Singapore Med J 2008; 49(7): e192-e194*

## INTRODUCTION

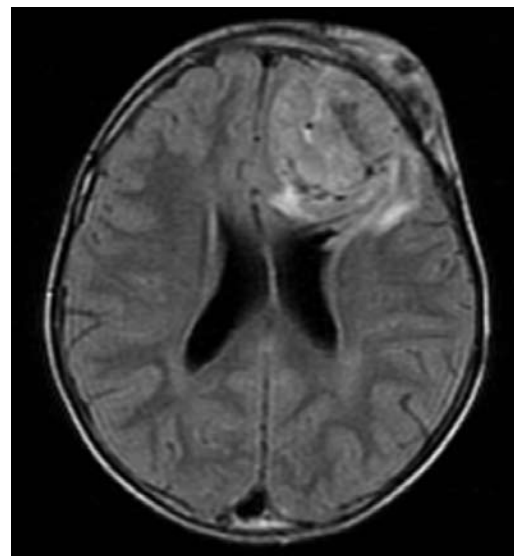
Cerebral supratentorial ependymomas are relatively uncommon tumours in paediatric patients, compared to infratentorial ependymomas.<sup>(1)</sup> Supratentorial ependymomas occur more frequently in adult patients than in paediatric patients. Despite their relative rarity, ependymomas have attracted great interest and have been the topic of multiple retrospective series evaluating the efficacy of surgery, radiotherapy, and chemotherapy, as well as the prognostic importance of factors such as tumour location, age and histological features. We describe a relatively rare case of supratentorial extraventricular ependymoma twice treated surgically, and followed by cranial radiotherapy.

## CASE REPORT

A four-year-old Malay boy presented with acute onset



**Fig. 1** Axial CT image of the brain shows the extraventricular lesion prior to the first craniotomy.



**Fig. 2** Contrast-enhanced axial T1-W MR image shows the recurrent extraventricular tumour.

of right-sided focal seizure which lasted about two minutes. One week prior to admission, the parent also noticed that the patient had a right-sided facial weakness and episodes of vomiting. There was no history of headache or body weakness. Neurological examination revealed bilateral papilloedema and a right-sided upper motor neuron facial nerve palsy.

Department of  
Neurosciences,  
School of Medical  
Sciences,  
Universiti Sains  
Malaysia,  
Kubang Kerian,  
Kota Bharu 16150,  
Malaysia

Ghani ARI, MS  
Lecturer

Abdullah JM, PhD  
Professor and Head

Ghazali M, BSc  
Science Officer

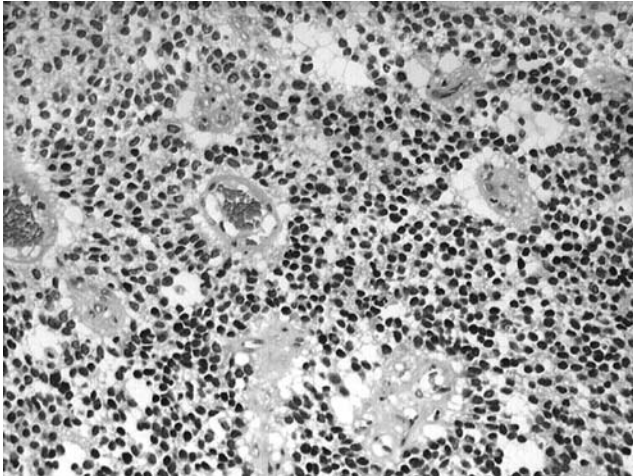
Ahmad F, BSc  
MSc Student

Ahmad KAK, BSc  
MSc Student

Department of  
Pathology

Madhavan M, MMed  
Lecturer

**Correspondence to:**  
Dr Ab Rahman Izaini  
Ghani  
Tel: (60) 9 766 4240  
Fax: (60) 9 764 8613  
Email: deptneuroscien  
cesppspum@yahoo.  
com

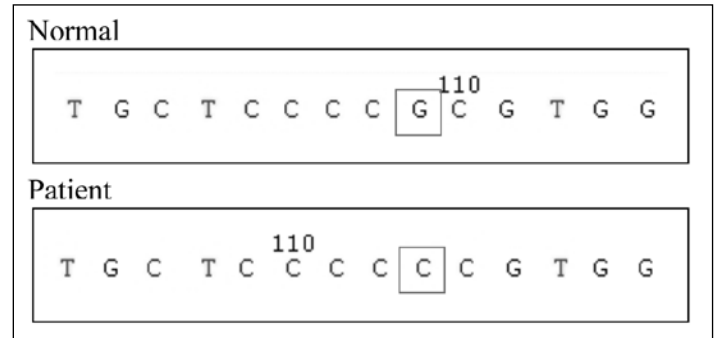

**Fig. 3** Photomicrograph of monomorphic tumour cells show characteristic perivascular pseudorosette formations. (Haematoxylin & eosin, × 10)

The sensorimotor and gait assessments were normal. Computed tomography (CT) of the brain showed a well-defined, cystic, rim-enhancing hypodense lesion in the left frontoparietal region. The lesion caused a mass effect with compression of the ipsilateral ventricle, subfalcine and uncal herniation (Fig. 1). Subsequently, he underwent a left frontotemporoparietal craniectomy and complete resection of the extraventricular tumour. The tumour was predominantly cystic with some areas of solid component, causing compression of the adjacent brain.

The histopathology specimen showed round to oval polygonal tumour cells arranged in sheets and cords. The cells form perivascular rosettes and some ependymomal rosettes (Fig. 2). There were also areas of haemorrhage, necrosis and multiple foci of dystrophic calcification. The overall histopathology was consistent with ependymoma (WHO grade II). Postoperatively, the patient progressed well without any new neurological deficit. He was then treated with cranial radiotherapy. He was reoperated ten months later, after a follow-up magnetic resonance (MR) imaging of the brain showed a recurrent tumour at the same extraventricular site. The brain tumour sample was obtained from the patient when he underwent surgery twice at Hospital Universiti Sains Malaysia in Kubang Kerian, Kelantan, Malaysia. Informed consent was obtained from the patient for genetic investigation, as this study had been approved by Research Development and Human Ethics Committee of School of Medical Sciences, Universiti Sains Malaysia.

Genomic DNA was extracted from the frozen brain tumour tissues using commercially available kits, DNeasy® Tissue Kit (QIAGEN GmbH, Germany) according to the protocol suggested by manufacturer. The DNA sequence regions of each gene were amplified



**Fig. 4** Partial sequence chromatography of the PCR-amplified product of exon 4 of p53 gene.

by polymerase chain reaction (PCR). In determining the potential genetic variation roles in supratentorial extraventricular ependymoma of p53 and p27 genes, samples were subjected to PCR by using two pairs of primers, which were restricted to exon 4–6, 8 of p53 gene and exon 1a, 1b, 2 of p27 gene. Amplified products of all regions were then purified by using GeneClean® II kit (BIO 101, Vista, CA, USA) and followed by cycle sequencing with BigDye® Terminator v3.1 Cycle Sequencing Kit (Applied Biosystems, Foster City, CA, USA) and Ethanol/EDTA precipitation. All PCR products were processed with sequencing using ABI PRISM® 3100 Genetic Analyzer (Applied Biosystems, Foster City, CA, USA). Our DNA sequencing results done twice on both tumour samples taken after the first and second surgeries revealed a substitution of nucleotide G to C at the location of 12139 in exon 4 of p53 gene. However, there was no alteration found in exon 1a, exon 1b and exon 2 of p27 gene and exon 3–6 and exon 8 of p53 gene.

## DISCUSSION

Ependymomas comprise 8%–10% of all brain tumours occurring in patients younger than 20 years of age, with a peak incidence between two and three years of age.<sup>(1)</sup> More than 90% of childhood ependymomas arise within the cranium; two-thirds occur infratentorially and one-third supratentorially. Approximately half the supratentorial tumours arise from the wall of the third ventricle; the remaining arise in the area remote from the ventricular wall, presumably from foetal rests of the ependymal cells. Therefore, it is possible that these tumours occur in locations distant from the ventricular system. Supratentorial extraventricular ependymoma is usually a slow-growing tumour that is often large at discovery. Despite their magnitude in the cerebral hemisphere, symptoms are relatively mild until a later stage of presentation. Symptoms of raised intracranial pressure such as headache and vomiting are common, whereas lateralising signs such as limb weakness and

seizure are less common.

Ependymoma typically occurs in the fourth ventricle or the central spinal canal. However, it is one of the differential diagnosis of supratentorial parenchymal tumour, particularly if MR imaging shows a heterogeneous mass. CT and MR imaging may show a well-demarcated, heterogeneous, intraventricular or extraventricular mass lesion. The lesion is typically large, cystic and calcified. Supratentorial ependymomas have a higher tendency of calcifications, greater than 80%, whereas 50% of infratentorial ependymomas are calcified. Macroscopically, ependymomas are relatively well-circumscribed, greyish or red in colour, lobulated, gritty, firm and frequently vascular. A microscopical diagnostic feature of ependymoma is the presence of rosettes, representing the tumour's attempt to recapitulate an ependyma-lined central canal. Most also contain perivascular pseudorosettes, in which a blood vessel is surrounded by an eosinophilic halo composed of radiating processes of the cells, which are oriented toward it. With respect to grading, there is considerable variation in the way ependymoma are graded. Several systems have been used in the past, but the current system is that of the World Health Organisation (WHO) classification which separates ependymoma into ependymoma (WHO grade II), anaplastic ependymoma (WHO grade III), myxopapillary ependymoma (WHO grade I), and subependymoma (WHO grade I).

Radical surgical removal, including an additional area of at least 1 cm of the peritumour white matter when the tumour lies superficially in non-eloquent brain cortex, is recommended for this pathology. This total extirpation together with a discrete "safety margin" is proposed in view of the risk of recurrence that could be as high as 35%–45% despite its benign nature. It appears that tumour resectability is the most important factor associated with recurrence. The reason for it is because this tumour is mainly not encapsulated and possesses a rather rough surface like a cauliflower or placenta. Villous fragments may then easily break off from the main mass during surgery and remain *in situ* to cause a future relapse. This risk is greater in cystic tumours, like in this case. Adjunct radiation therapy is recommended in every malignant ependymoma or partially-resected ependymoma, as well as for extraventricular ependymoma that are cystic or located near eloquent brain areas even after apparently radical excision. For benign lesions, local irradiation is sufficient,

whereas whole-brain irradiation with local boost is advisable for malignant cases. The dose of radiation for the treatment of ependymoma is normally in the range of 4,500 to 5,600 cG. Prophylactic craniospinal irradiation of supratentorial ependymoma in children is not recommended. Adjuvant chemotherapy does not demonstrate any benefit.

In this study, we found mutation in exon 4 of p53 gene and no mutation of p27 in our samples, suggesting that this gene could be the cause for its recurrence.<sup>(2,3)</sup> A recent paper published in Science explains why this tumour might originate from heterotopic ependymal cell rests, either in the cortex or in the subarachnoid space via a lateral ventricular extension.<sup>(4)</sup> Aberrant ependymal cell rests can be misplaced in various parts of body during the embryonal period. The second possible pathogenic hypothesis would be to consider that the tumour represents a primitive neuroectodermal tumour which would have differentiated ependymal from precursors.<sup>(5)</sup>

In conclusion, we described a relatively rare case of recurrent supratentorial extraventricular ependymoma of childhood. Based on the literature available regarding this pathology, total excision is the primary treatment for tumours located in the non-eloquent area, followed by adjuvant radiotherapy. Prophylactic craniospinal irradiation was not indicated, considering the low risk of spinal metastasis in supratentorial ependymoma and the potential risk of spinal irradiation such as cognitive impairment, marrow suppression and gastrointestinal upset. It is rational to perform routine surveillance cranial MR imaging at regular intervals to detect asymptomatic recurrence, because recurrences are often local and amenable to surgery. p53 gene mutation is an important analysis to predict recurrence and therefore, patients with this mutation require close follow-up.

## REFERENCES

1. Figarella-Branger D, Civatte M, Bouvier-Labit C, et al. Prognostic factors in intracranial ependymomas in children. *J Neurosurg* 2000; 93:605-13.
2. Fink KL, Rushing EJ, Schold SC Jr, Nisen PD. Infrequency of p53 gene mutations in ependymomas. *J Neurooncol* 1996; 27:111-5.
3. Korshunov A, Timirgazi V, Golanov A. Prognostic value of aberrant p53 immunoreactivity for the recurrence of ependymoma: An analysis of 76 cases. *Neuropathology* 1999; 19:380-5.
4. Curtis MA, Kam M, Nannmark U, et al. Human neuroblasts migrate to the olfactory bulb via a lateral ventricular extension. *Science* 2007; 315:1243-9.
5. Morest DK, Silver J. Precursors of neurons, neuroglia, and ependymal cells in the CNS: what are they? Where are they from? How do they get where they are going? *Glia* 2003; 43:6-18.