

The Sengstaken-Blakemore tube: uses and abuses

Seet E, Beevee S, Cheng A, Lim E

ABSTRACT

Due to its complications including oesophageal and gastric ulceration and perforation, the Sengstaken-Blakemore tube is used far less commonly in this new millennium where endoscopic intervention is available. We discuss in a 53-year-old Indian woman an unusual life-saving use of the Sengstaken-Blakemore tube in preventing fatal exsanguination from an aorto-oesophageal fistula, as well as rare but devastating consequences of the insertion and residence of the Sengstaken-Blakemore tube, including acute airway obstruction and broncho-oesophageal fistula.

Keywords: airway obstruction, aorto-oesophageal fistula, broncho-oesophageal fistula, Sengstaken-Blakemore tube

Singapore Med J 2008; 49(8): e195-e197

INTRODUCTION

The Sengstaken-Blakemore tube (SBT), which was originally described in 1950,⁽¹⁾ is a multiluminal plastic tube with two inflatable balloons. It is introduced into the oesophagus with the distal balloon inflated in the stomach. Distension of the proximal balloon is used as an oesophageal tamponade to arrest suspected bleeding from varices. Generally, it is used in emergencies where bleeding from varices are difficult to control in an exsanguinating patient.

CASE REPORT

A 53-year-old Indian woman, with comorbidities of type II diabetes mellitus, hypertension, hyperlipidaemia, peripheral vascular disease and osteoarthritis of bilateral knee joints, was admitted with knee pain and swelling after trauma to the left knee joint. The orthopaedic problem was treated non-surgically with rest and analgesia. During her inpatient stay, the woman developed two initial episodes of haematemesis. An oesophagogastrroduodenoscopy revealed a duodenal ulcer. The patient underwent sclerotherapy on the first instance, followed by laparotomy and under-running of the ulcer after the second haematemesis episode.

On the third postoperative day in the high-dependency unit, the patient complained of chest pain,

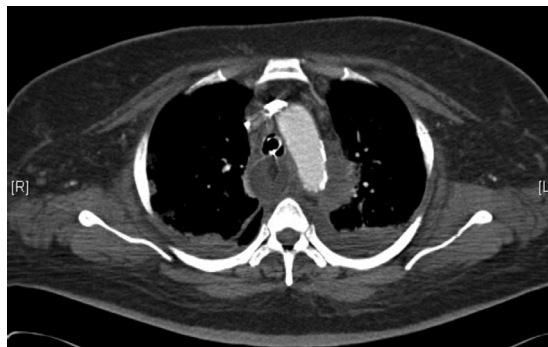

Fig. 1 Axial CT image shows a haematoma around the aortic arch.

followed by a third episode of unrelenting catastrophic haematemesis. This led to cardiovascular collapse. A SBT (Ch.18 RüSCH Weichgummi Sengstaken-Blakemore) was used empirically to arrest the haemorrhage to allow successful resuscitation from hypovolaemic shock and pulseless electrical activity. The patient was intubated, ventilated and transfused with blood products. Initially presumed to have an upper gastrointestinal haemorrhage secondary to either a bleeding gastroduodenal ulcer or oesophageal varices, the patient underwent emergency surgery. Intraoperatively, the SBT was deflated and removed in preparation for a gastroscopy. This led to massive exsanguination necessitating the reinsertion of the SBT and rapid reinflation of both the oesophageal and gastric balloons with 150–200 ml of water.

Subsequently, ventilation of the patient became compromised with diminishing tidal volumes (baseline of 500 ml reduced to < 200 ml) and increasing airway pressures (> 50 cm water). Auscultation revealed near-absent air entry in the left lung. The initial impression was right endobronchial intubation. However, despite withdrawing the endotracheal tube to an appropriate level, ventilation failed to improve. Urgent fiberoptic bronchoscopy revealed extraluminal compression of the left main bronchus, likely by the oesophageal balloon of the SBT. The pressure in the oesophageal balloon was reduced cautiously with subsequent improvement of ventilation. The surgeons performed a laparotomy and gastrectomy, but failed to control the

Department of
Anaesthesia and
Surgical Intensive
Care,
Alexandra Hospital,
378 Alexandra Road,
Singapore 159964

Seet E, MBBS,
MMed
Associate Consultant

Beevee S, MBBS,
MMed
Consultant

Department of
Surgery

Cheng A, MBBS,
FRCSE, FRACS
Senior Consultant

Lim E, MBBS,
MRCSE, MMed
Registrar

Correspondence to:
Dr Edwin Seet
Tel: (65) 9848 2030
Fax: (65) 6379 3149
Email: seetedwin@
gmail.com

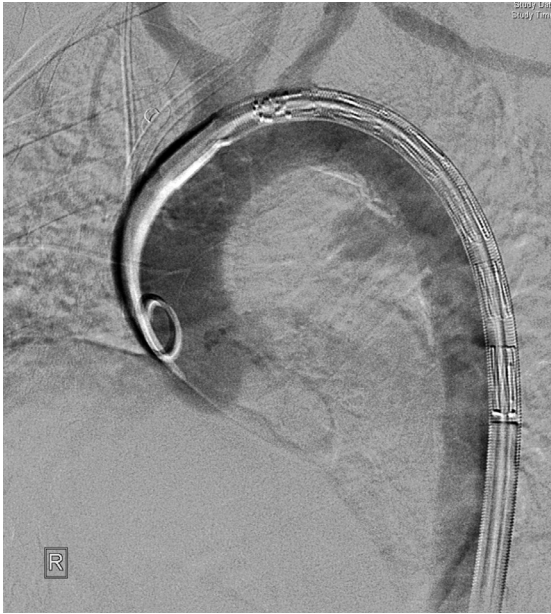


Fig. 2a Pre-stenting aortogram.

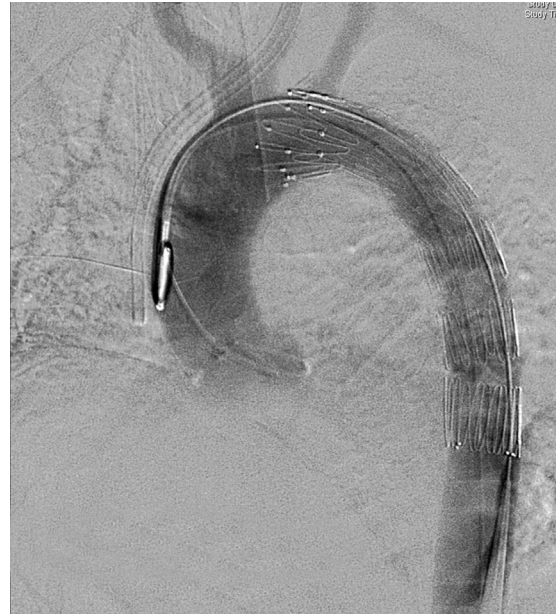

Fig. 2b Post-stenting aortogram.

bleeding. The SBT was left *in situ* to arrest bleeding from the unknown oesophageal source.

Postoperatively, a computed tomography (CT) scan of the abdomen and thorax was performed with aortography. This revealed a saccular aneurysm under the aortic arch and a likely diagnosis of an aortoesophageal fistula (AEF) (Fig. 1). An endovascular stent was deployed by the radiologist and cardiothoracic surgeon (Figs. 2a & b). After confirmation that there was no further bleeding from the fistula, the SBT was deflated and removed. In total, the SBT was inflated and resided in the oesophagus for 30 hours.

The patient's recovery thereafter was stormy. Three weeks after the SBT insertion, the patient developed bilateral pneumonia and an air leak during positive pressure mechanical ventilation. Bilious fluid was continuously aspirated from the endotracheal tube. Flexible and rigid bronchoscopy confirmed the presence of a large (15 mm diameter) fistula in the posterior aspect of the left main bronchus in connection with the oesophagus (Fig. 3). This bronchooesophageal fistula (BEF) was likely secondary to pressure necrosis and tissue breakdown from the inflated balloon of the SBT. Subsequently, the patient underwent endoscopic-guided oesophageal stenting (covered expandable metallic stent, Boston Scientific, MA, USA), left main bronchial stenting (Fig. 4), and fistula occlusion using prolene mesh/fibrin tissue glue/histoacryl. There was significant but unsustainable improvement of the air leak from the palliative procedures. The patient succumbed to severe sepsis and bilateral pneumonia before definitive surgery could be carried out.

DISCUSSION

AEFs occur infrequently, but the consequences are often catastrophic. They constitute a minority of approximately 10% of all aortoenteric fistulas.⁽²⁾ Chiari in 1914 described the syndrome of AEF as a triad of: midthoracic pain or dysphagia, followed by a "herald" haemorrhage, and then fatal haematemesis.⁽³⁾ Because it is rarely suspected and exsanguination is rapid, the majority of patients with AEFs die before a definitive diagnosis is made.⁽⁴⁾ In similar fashion, our patient presented with chest pain and two episodes of self-limiting haematemesis, followed by a third episode of massive unrelenting haematemesis. Spontaneous cessation of the "herald" haemorrhage may be due to temporary occlusion of the fistula due to arterial wall spasm, intravascular hypotension, or occlusion of the fistula by periaortic haematoma.

SBTs are indicated primarily for the control of oesophageal variceal bleeding. In addition, the gastrooesophageal balloon tamponade effect of the SBT has been reported to control bleeding in AEFs, and may be life-saving.^(5,6) In this instance, the SBT was inserted empirically to arrest the haemorrhage before the definitive diagnosis of an AEF was made, without which, the patient would have sustained a fatal haematemesis. This measure allowed the clinicians time for a diagnosis to be made and an endovascular aortic stent to be deployed to occlude the fistulous defect. A similar case was previously reported by Assink et al.⁽⁶⁾

The use of the SBT is not without problems.⁽⁷⁾ Commonly-described complications include aspiration pneumonitis occurring in 10%–20% of cases,^(8,9)

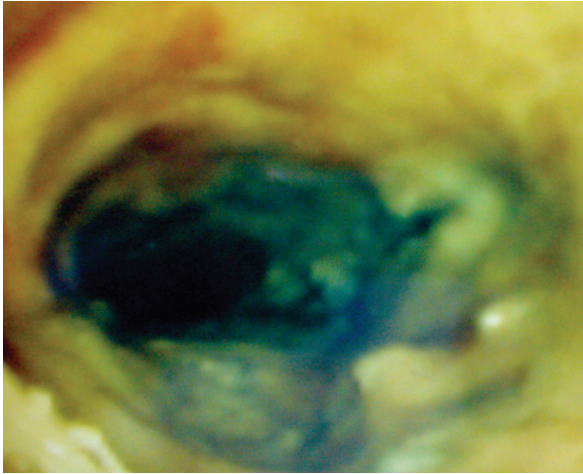


Fig. 3 Bronchoscopic photograph shows the left main bronchus fistula after ingestion of methylene blue.

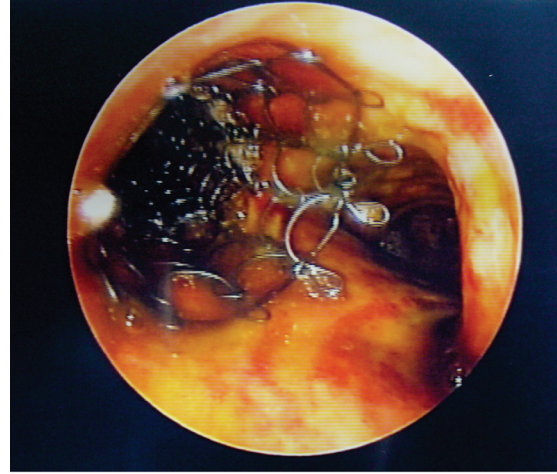


Fig. 4 Bronchoscopic photograph shows the covered metallic stent in the left main bronchus.

oesophageal perforation⁽¹⁰⁾ and mucosal ulceration.⁽¹¹⁾ We report two unusual complications (“abuses”) arising from the use of the SBT in our patient in the immediate and later stages of her management. Kelly et al reported how an incorrectly-positioned SBT can compromise ventilation when the over-inflated gastric balloon compresses on the trachea resulting in poor bilateral chest expansion.⁽¹²⁾ In our case, the oesophageal balloon was over-inflated, resulting in extrinsic compression on the left main bronchus and diminished air entry in the left lung. This masqueraded as an endobronchial intubation. Urgent fiberoptic bronchoscopy aided in making the diagnosis of the airway obstruction due to SBT.

The patient presented with an air-leak syndrome from a BEF two to three weeks after the insertion of the SBT. The same high oesophageal balloon pressures required to arrest bleeding from the AEF may adversely have caused reduced perfusion and ischaemic damage to the tracheobronchial tree. This effect in the background of ongoing systemic hypotension and sepsis may have resulted in the development of the BEF. This case demonstrates the less well-known life-saving uses of the SBT in the immediate management of upper gastrointestinal bleeds and AEFs. It also highlights rare but potentially life-threatening complications of the intervention in causing airway obstruction and possibly resulting in BEFs. Clinicians should be cognizant of these possible complications and its prevention.⁽¹³⁾ Some rules to follow on its insertion would be to ensure the gastric balloon sits in the fundus of the stomach and be inflated with 100–

250 ml of air or water, while the oesophageal balloon is inflated to a pressure of 20–50 mmHg.

REFERENCES

1. Sengstaken RW, Blakemore AH. Balloon tamponade for the control of hemorrhage from esophageal varices. *Ann Surg* 1950; 131:781-9.
2. Sinar AR, Demaria A, Kataria YP, Thomas FB. Aortic aneurysm eroding the esophagus: Case report and review. *Dig Dis Sci* 1977; 22:252-4.
3. Chiari H. [Injury of the esophagus with perforation of the aorta produced by a foreign body]. *Berl Klin Wochenschr* 1914; 51:7-9. German.
4. Amin S, Luketich J, Wald A. Aortoesophageal fistula case report and review of literature. *Dig Dis Sci* 1998; 43:1665-71.
5. Wu MH, Lai WW. Aortoesophageal fistula induced by foreign bodies. *Ann Thoracic Surg* 1992; 54:155-6.
6. Assink J, Vierhout BP, Snellen JP, et al. Emergency endovascular repair of an aortoesophageal fistula caused by a foreign body. *J Endovasc Ther* 2005; 12:129-33.
7. Vlavianos P, Gimson AES, Westaby D, Williams R. Balloon tamponade in variceal bleeding: Use and misuse. *BMJ* 1989; 298:1158-9.
8. Avgerinos A, Armonis A. Balloon tamponade technique and efficacy in variceal haemorrhage. *Scand J Gastroenterol* 1994; 29(Suppl 207):11-6.
9. Pinto-Marques P, Romaozinho JM, Ferreira M, Amaro P, Freitas D. Esophageal perforation – associated risk with balloon tamponade after endoscopic therapy. Myth or reality? *Hepatogastroenterology* 2006; 53:536-9.
10. Chong CF. Esophageal rupture due to Sengstaken-Blakemore tube misplacement. *World J Gastroenterol* 2005; 11:6563-5.
11. Chien JY, Yu CJ. Images in clinical medicine. Malposition of a Sengstaken-Blakemore tube. *N Engl J Med* 2005; 352:e7.
12. Kelly DJ, Walsh F, Ahmed S, Synnott A. Airway obstruction due to a Sengstaken-Blakemore tube. *Anesth Analg* 1997; 85:219-21.
13. McCormick PA, Burroughs AK, McIntyre N. How to insert a Sengstaken-Blakemore tube. *Br J Hosp Med* 1990; 43:274-7.