

# Bronchobiliary fistula successfully treated surgically

Chong C F, Chong V H, Jalihal A, Mathews L

## ABSTRACT

**Bronchobiliary fistula is a rare condition, arising as a complication of hydatid disease of the liver, hepatic tuberculosis, hepatic malignancy, chronic pancreatitis, hepatic trauma or surgery. Patients characteristically present with recurrent biliptysis, and in the chronic stage, develops bronchiectasis of the affected segment of the lung. Conservative treatment is directed at non-surgical approaches of relieving biliary obstruction to allow for normal flow of bile into the duodenum via endoscopy or percutaneous routes. However in complicated cases which failed conservative non-surgical therapy, surgical intervention is usually required. We report a 29-year-old Malay man who presented with chronic biliptysis from a bronchobiliary fistula resulting from occlusion of a biliary stent inserted to treat intrahepatic biliary strictures. This was successfully treated surgically with a right medial lobectomy and interposition of a piece of viable tissue between the fistula stump on the dome of the diaphragm and the remaining lung.**

**Keywords:** biliary stenting, biliptysis, bronchiectasis, bronchobiliary fistula, lobectomy

*Singapore Med J 2008;49(8):e208-e211*

## INTRODUCTION

Bronchobiliary fistula is a rare condition, arising as a complication of hydatid disease of the liver, hepatic tuberculosis (TB), hepatic malignancy, chronic pancreatitis, hepatic trauma or surgery.<sup>(1-5)</sup> Patients with bronchobiliary fistula characteristically present with recurrent biliptysis, and in the chronic stage, develop bronchiectasis of the involved segment of the lung.<sup>(6)</sup> Medical or non-surgical therapy is directed at relieving pressure in the biliary system and allowing for free drainage of bile into the duodenum with endoscopic retrograde cholangiopancreatography (ERCP) and biliary stenting or via percutaneous methods which can resolve the fistula in most patients.<sup>(7-9)</sup> However in some patients, particularly those with bronchiectatic



**Fig. 1** Photograph shows the frothy bilious fluid coughed up by the patient.

segment of the lung or failed non-surgical therapies, surgical intervention is usually required.<sup>(4,6,7,10)</sup> We described a 29-year-old Malay man presenting with chronic biliptysis from a bronchobiliary fistula, secondary to biliary obstruction from an occluded biliary stent inserted previously for multiple biliary strictures. This was successfully treated surgically with a right medial lobectomy and interposition of a piece of viable tissue between the fistula stump on the dome of the diaphragm and the remaining lung.

## CASE REPORT

A 29-year-old Malay man was admitted in February 2006 with fever and a productive cough of a copious amount (> 500 ml) of greenish frothy fluid (Fig. 1). He had several previous admissions since November 2003 for recurrent right middle lobe pneumonia with greenish sputum, which resolved with antibiotic therapy. He was also under regular review by the gastroenterologist for multiple biliary strictures secondary to nodular hepatic calcifications (Fig. 2a). Percutaneous biopsies of the hepatic lesions confirmed calcified old granulomas but negative for acid-fast bacilli (AFB). However, despite this, the hepatic calcifications were thought to be secondary to healed hepatic TB. The biliary strictures were managed with repeated biliary stenting. Computed tomography (CT) in 2005 showed a bronchiectatic medial pulmonary lobe. Biochemical analysis of the greenish frothy fluid confirmed bilirubin with a level of more than

Department of  
General Surgery,  
Thoracic Unit,  
RIPAS Hospital,  
Bandar Seri  
Begawan BA 1900,  
Brunei Darussalam

Chong CF, MBBS,  
FRCSE, MD  
Consultant

Gastroenterology  
Unit,  
Department of  
General Medicine

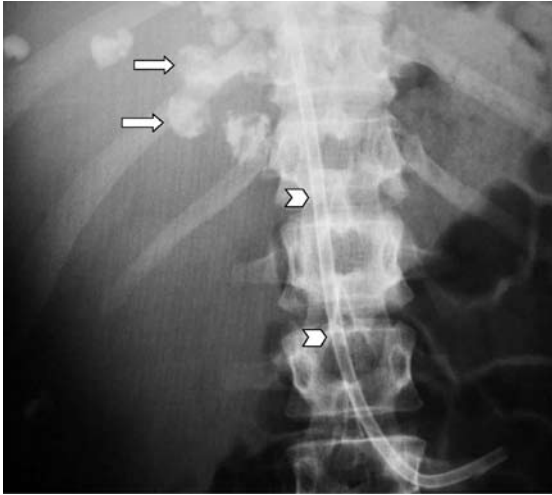
Chong VH, MBChB,  
MRCP, FAMS  
Consultant

Jalihal A, MBBS,  
MD, DM  
Associate Consultant

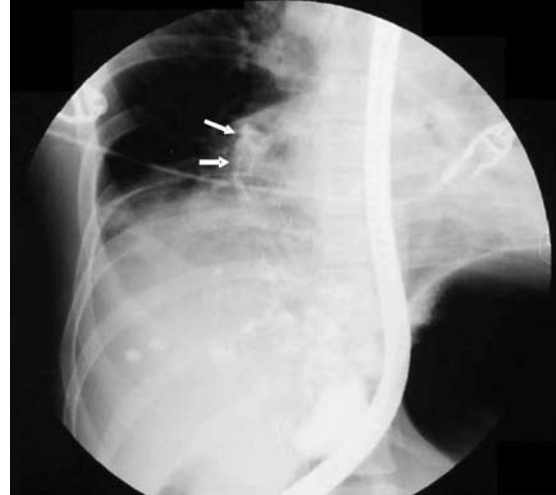Division of  
Respiratory  
Medicine,  
Department of  
General Medicine

Mathews L, MRCP  
Consultant

**Correspondence to:**  
Dr Chee Fui Chong,  
Tel: (673) 224 2424  
ext 270  
Fax: (673) 233 3270  
Email: chong\_chee\_fui@hotmail.com



**Fig. 2a** Radiograph shows multiple nodular hepatic calcifications (white arrows) with indwelling biliary stent (arrowheads).



**Fig. 2b** ERCP image shows the bronchobiliary fistula between segment 8 of the liver and the right middle lobe (white arrows).

1,600 mg/dL. A diagnosis of bronchobiliary fistula was made. The patient was kept fasted and started on an intravenous infusion of synthetic somatostatin (Stilamin) to reduce biliary secretion.

The patient underwent an urgent ERCP under conscious sedation with oxygen supplementation. The biliary stent was found to be occluded and was removed. A retrograde cholangiogram confirmed the fistula tract communicating between the biliary system of segment eight of the liver with the right middle lobe of the lung (Fig. 2b). However, during the procedure, the patient became agitated, with subsequent oxygen desaturation and hypotension. He was intubated immediately with a single lumen tube and the procedure terminated. Urgent chest radiograph showed patchy consolidation of the left upper lobe due to bile aspiration (Fig. 3). He was transferred to the surgical intensive care unit, and the single lumen endotracheal tube was replaced with a double lumen endotracheal tube.

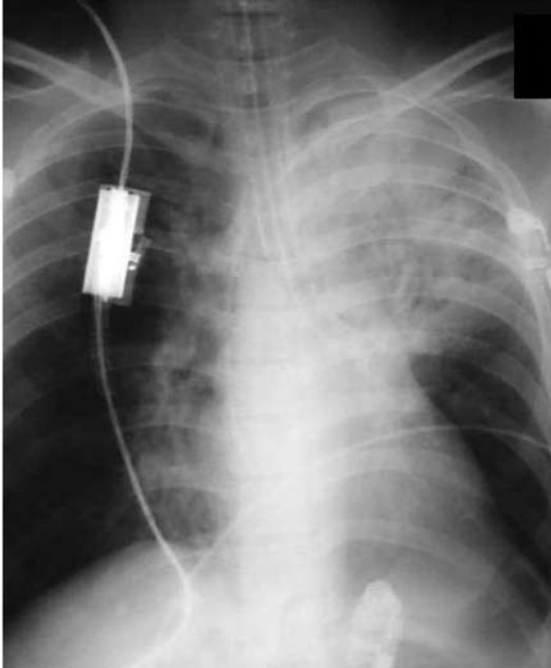
With positive pressure ventilation, it was felt that the fistula was unlikely to close and there was still a potential risk of further aspiration to the remaining lobes upon extubation of the patient. Hence, a decision was made for urgent surgical intervention. He underwent an emergency right thoracotomy the same evening. The inferior surface of the middle lobe of the right lung was found to be firmly adherent to the cardiophrenic angle of the diaphragm. The lobe was firm and showed greyish hepatization. A middle lobectomy was performed with a cuff of firm pulmonary tissue left attached at the cardiophrenic angle of the diaphragm. The fistula tract was not visible but bile could be seen exuding from the cut surface of the lung. The cuff was oversewn with 2/0 vicryl suture to completely suture

off the fistula. A cuff of tissue complete with parietal pleura and intercostals muscle was dissected free from the anterior chest wall near the fistula stump with the medial end still attached with its own blood supply. This was used to seal off the fistula from the rest of the thoracic cavity and lung by sewing the tissue around the stump. Two large bore (32Ch) chest drains were inserted and the thoracic cavity was thoroughly washed with warm normal saline. The thoracotomy wound was closed routinely, and the double lumen tube was replaced with a single lumen endotracheal tube at the end of surgery.

The patient was transferred back to the surgical intensive care unit where he underwent flexible bronchoscopy. Bile was found coming out of the left upper lobe bronchus, and a thorough lavage and suction of his left upper lobe was done. Post-procedure chest radiograph showed complete resolution of the left upper lobe consolidation. He was extubated 48 hours later and made an uneventful recovery. Following discharge, he was reviewed a month later and found to be well with no further episode of biliptysis. His chest radiograph was completely clear. He has been regularly reviewed by the gastroenterologist who has adopted a “watch and wait” policy with regard to the patient’s intrahepatic biliary strictures.

## DISCUSSION

Bronchobiliary fistula is a rare entity that was first reported as a complication of hepatic or pulmonary echinococcus infection, but has subsequently been reported as a complication of hepatic TB infection, malignancy, trauma, liver resection, biliary lithiasis and chronic pancreatitis.<sup>(1-5)</sup> Congenital bronchobiliary fistula has also



**Fig. 3** Chest radiograph shows patchy consolidation of the left upper lobe following bile aspiration.

been reported due to congenital abnormalities of the diaphragm or bronchobiliary tree.<sup>(11,12)</sup> Bronchobiliary fistula resulting from iatrogenic biliary stent migration has also been previously reported.<sup>(13)</sup> Although this patient was investigated for hepatic TB because of the diffuse nodular calcification, liver biopsy only showed calcified old granuloma without caseation and was negative for AFB. Despite this, we felt that the underlying aetiology was still TB infection. As there was no evidence of active disease, anti-TB treatment was not started. It is possible that this patient may have contracted hepatic TB previously but is now inactive. The aetiology of this patient's bronchobiliary fistula was probably due to occlusion of the biliary stent resulting in a build-up of bilious pressure distal to the stent with subsequent erosion into the bronchial tree.

The diagnosis of bronchobiliary fistula can be very difficult, as indicated by this case where the patient has been treated for recurrent right middle lobe pneumonia and bronchiectasis for almost two years. Patients with bronchobiliary fistula can present with one of two clinical syndromes: either acute fulminating bronchiolitis or chronic intermittent episodes of expectoration of bile-stained sputum.<sup>(9)</sup> Making a diagnosis of bronchobiliary fistula from the latter will require a high index of suspicion and observation of biliptysis. However, massive biliptysis (Fig. 1), as was the case here, indicates a diagnosis of a fistulous connection between the bronchus and biliary tree. The presence of bile in the sputum can be easily and quickly

identified using a urinary dipstick or biochemical analysis of the sputum for bilirubin. To confirm the fistula tract, various invasive and noninvasive radiological methods have been described, such as ERCP or percutaneous transhepatic cholangiography, particularly in cases with dilated intrahepatic ducts or noninvasive methods like hepatobiliary iminodiacetic acid (HIDA) scan or cholescintigraphy, CT and magnetic resonance cholangiography.<sup>(9,12)</sup>

Somatostatin or analogues have been used for many gastrointestinal conditions usually used to reduce secretion. Somatostatin has been shown to reduce bile secretion in biliary obstruction secondary to hepatic tumours, and is commonly used in acute pancreatitis to reduce both pancreatic and bile secretion.<sup>(14)</sup> Its use in cases of bronchobiliary fistula has not been reported before, and in our case, was mainly based on the clinical decision to reduce bile secretion through the bronchobiliary fistula. Due to the higher atmospheric pressure gradient in the bronchial tree, biliptysis does not occur unless there is an obstruction to the normal drainage of bile through the biliary system. Hence, the initial management of the patient with bronchobiliary fistula is usually with a non-surgical approach at relieving the obstruction in the biliary system. This is usually achieved through ERCP with dilatation of biliary strictures and insertion of biliary stents, which will allow free drainage of the bile through the usual route via the biliary system into the duodenum.<sup>(7-9)</sup> The use of percutaneous biliary decompression and nasobiliary drainage have also been reported to be successful in resolving bronchobiliary fistula.<sup>(7-9)</sup> In the majority of cases, the fistula resolved once biliary drainage through the bile duct was re-established. Thus, the initial management in this case was to remove the occluded biliary stent with a view to placing a new stent to divert the biliary drainage away from the bronchobiliary fistula. Unfortunately, the patient aspirated bile into his left upper lobe during the procedure, requiring intubation and this procedure was abandoned.

Embolisation of the bronchobiliary fistula tract using cyanoacrylate glue through bronchoscopy has recently been reported as an alternative non-surgical approach in a patient who has failed other non-surgical treatments and was medically unfit for surgical intervention.<sup>(15)</sup> Alternatively, closure of the tract may be attempted via the ERCP route. However the long-term result of using cyanoacrylate glue in the bronchial airways is questionable in terms of adverse tissue reaction with foreign body granuloma formation and subsequent possibility of bronchiectasis.

Surgery is considered in cases where other

approaches have failed or when there are complications from the underlying disease.<sup>(7)</sup> The principles of surgical intervention would be two-fold: first, to relieve any biliary obstruction and permit continuous free drainage of bile into the digestive tract usually through the creation of Roux-en-Y choledochojejunostomy; and second, to drain all abscesses and to excise the fistula tract together with the diseased lung segment or to completely obliterate the fistula tract.<sup>(7,10)</sup> However, in this case, because of the complication of bile aspiration into the left upper lobe, and since the right middle lobe was completely bronchiectatic, an emergency right thoracotomy and middle lobectomy were performed, with complete obliteration of the fistula tract by sealing it off from the rest of the thoracic cavity with an interposed tissue pedicle. This approach has also been previously described by Chua et al.<sup>(10)</sup>

A more extensive approach would be to perform a thoracophrenotomy and removal of the fistula tract completely, particularly in cases where the aetiology of the bronchobiliary fistula is due to both pulmonary and hepatic hydatid disease.<sup>(16)</sup> We recommend the former procedure, particularly in patients who are unwell, as the results achieved are just as good. Certainly the underlying causes will also need to be dealt with. Currently, this patient is being followed-up by the gastroenterologist and recent magnetic resonance cholangiography did not reveal any dilated intrahepatic biliary ducts. As he is well and has no jaundice, a “watch and wait” policy was adopted by the gastroenterologist for his hepatic problem. With regard to the bronchobiliary fistula, the follow-up chest radiograph taken a month later was completely clear, and he has not complained of any further respiratory symptoms.

## REFERENCES

- Gerazounis M, Athanassiadi K, Metaxas E, Athanassiou M, Kalantzi N. Bronchobiliary fistulae due to echinococcosis. *Eur J Cardiothorac Surg* 2002; 22:306-8.
- Kim YS, Rhim H, Sung JH, et al. Bronchobiliary fistula after radiofrequency thermal ablation of hepatic tumor. *J Vasc Interv Radiol* 2005; 16:407-10.
- Eck BD, Passinaut WJ. Bronchobiliary fistula. A rare complication of chronic pancreatitis. *Int J Pancreatol* 1996; 20:213-6.
- Brunaud L, Sebbag H, Bresler L, Tortuyaux JM, Boissel P. Left hepatic duct injury and thoracobiliary fistula after abdominal blunt trauma. *Hepatogastroenterology* 2000; 47:1227-9.
- Oettl C, Schima W, Metz-Schimmerl S, et al. Bronchobiliary fistula after hemihepatectomy: cholangiopancreatography, computed tomography and magnetic resonance cholangiography findings. *Eur J Radiol* 1999; 32:211-5.
- Vimalraj V, Jeswanth S, Selvakumar E, et al. A case of recurrent biliptysis. *J Thorac Cardiovasc Surg* 2007; 133:1662-3.
- Jung SI, Goo JM, Han JK, et al. Recurrent bronchobiliary fistula: unsuccessful management with repeated insertion of metallic biliary stent. *J Vasc Interv Radiol* 2003; 14:1577-9.
- Partrinou V, Dougenis D, Kritikos N, Polydorou A, Vagianos C. Treatment of postoperative bronchobiliary fistula by nasobiliary drainage. *Surg Endosc* 2001; 15:758.
- Schwartz ML, Coyle MJ, Aldrete JS, Keller FS. Bronchobiliary fistula: complete percutaneous treatment with biliary drainage and stricture dilation. *Radiology* 1988; 168:751-2.
- Chua HK, Allen MS, Deschamps C, Miller DL, Pairolero PC. Bronchobiliary fistula: principles of management. *Ann Thorac Surg* 2000; 70:1392-4.
- DiFiore JW, Alexander F. Congenital bronchobiliary fistula in association with right-sided congenital diaphragmatic hernia. *J Pediatr Surg* 2002; 37:1208-9.
- Hourigan JS, Carr MG, Burton EM, Ledbetter JC. Congenital bronchobiliary fistula: MRI appearance. *Pediatr Radiol* 2004; 34:348-50.
- Dasmahapatra HK, Pepper JR. Bronchopleurobiliary fistula. A complication of intrahepatic biliary stent migration. *Chest* 1988; 94:874-5.
- Andersen HB, Petronijevic L, Giese B, Mygind T, Burcharth F. Somatostatin reduces bile secretion and loss of bile constituents in patients with external biliary drainage. *HPB Surg* 1996; 9:229-33.
- Goldman SY, Greben CR, Setton A, et al. Bronchobiliary fistula successfully treated with n-butyl cyanoacrylate via a bronchial approach. *J Vasc Interv Radiol* 2007; 18:151-5.
- Athanassiadi K, Kalavrouziotis G, Loutsidis A, Bellenis I, Exarchos N. Surgical treatment of echinococcosis by a transthoracic approach: a review of 85 cases. *Eur J Cardiothorac Surg* 1998; 14:134-40.