

Accessory origin of the piriformis muscle

Ravindranath Y, Manjunath K Y, Ravindranath R

ABSTRACT

Incidental finding of an accessory slip of the piriformis muscle in the gluteal region is reported. Following routine dissection of the gluteal region in three formalin-fixed cadavers, an accessory slip of the piriformis was observed. The accessory slip was cleaned, attachments were identified, and dimensions were measured in two parts as fleshy and tendinous parts with a graduated scale to the nearest millimetre. The accessory slip was innervated by a small twig from the sciatic nerve. Having considered the available literature, the accessory slip of piriformis is rare, and if found, could be a cause for the undiagnosed chronic pain in the back and gluteal region, as this accessory slip may compress the sciatic nerve.

Keywords: accessory slip piriformis, anatomical muscle variations, bifid piriformis, piriformis muscle, piriformis syndrome

Singapore Med J 2008; 49(8): e217-e218

INTRODUCTION

Variations are principally due to the variable genetic composition, which is an inheritance carried over from an ancestral origin. Most of the anatomical variations are benign. These muscular variations are due to the errors of embryological development. According to Galen and Vesalis, anatomical variations are the results of an imperfect or unnatural development.⁽¹⁾

CASE REPORT

Following routine dissection of the gluteal region, an accessory slip of the piriformis was noted in three male adult formalin-fixed cadavers. In two cases, the fleshy part of the accessory slip originated from the sacrotuberous ligament, and in the third case, from the sacrotuberous ligament and the fascia overlying the gluteus medius. The tendinous part of the muscle inserted into the main tendon of the piriformis unilaterally on the left side in one cadaver, and bilaterally in the other two cadavers. The direction of the fleshy fibres was found to be downwards and lateral, and the tendinous part of the fleshy belly of

the accessory slip tapered downwards and merged with the main tendinous part of the piriformis muscle in all the three cases. The accessory slip was found to be innervated by a small twig from the sciatic nerve. The main trunk of the sciatic nerve was found deep to the accessory slip. The average length and width of the fleshy and tendinous part were measured using calipers to the nearest mm. The size of the fleshy belly was found to range 3.7–6.5 cm in length and 2–3 cm in width, while the length of the tendinous part was found to range 0.9–1.7 cm in length.

DISCUSSION

The piriformis is the key muscle of the gluteal region, as it occupies the central position of the region. The vessels and nerves typically emerge above and below the muscle, therefore these neurovascular structures are in close relation with this muscle. Thus, any anatomical variation of this muscle may be of clinical importance. The piriformis originates from the pelvic surface of the sacrum at the level of the second to fourth sacral segments. It passes through the greater sciatic foramen which it largely fills, and forms a rounded tendon that inserts into the medial side of the upper border of the greater trochanter. It is innervated by the first and second sacral nerves.⁽²⁾

Among the reported variations, in 10% of the cases, the piriformis muscle was perforated by the sciatic nerve.⁽²⁾ In the present study, the sciatic nerve was related deep to the accessory slip and was found to innervate the same by a small twig. Anomalous or aberrant slips of muscles may arise in the buttock, close to the piriformis and may cause coccygodynia and sciatic pain due to the abnormal relation between the aberrant slip and sciatic nerve.⁽³⁾ These were also observed in the present study. Accessory slip of the piriformis could be one of the main reasons for the undiagnosed pain in the buttock leading on to the piriformis syndrome.⁽⁴⁾

Most of the previous authors have reported entrapment of the sciatic nerve by the bipartite, duplicated, piriformis muscle leading to piriformis syndrome.⁽⁵⁻⁸⁾ However, opinions differ by other authors in a study of 65 cadavers for anatomical variations,

**Department of
Anatomy,
St John's Medical
College,
Bangalore 560036,
India**

Ravindranath Y,
MBBS, MD
Assistant Professor

Manjunath KY,
MBBS, MS
Professor

Ravindranath R,
MBBS, MS
Professor

Correspondence to:
Dr Yogitha
Ravindranath
Tel: (91) 80 2552 5653
Fax: (91) 80 2552 0777
Email: yogi3110@
gmail.com

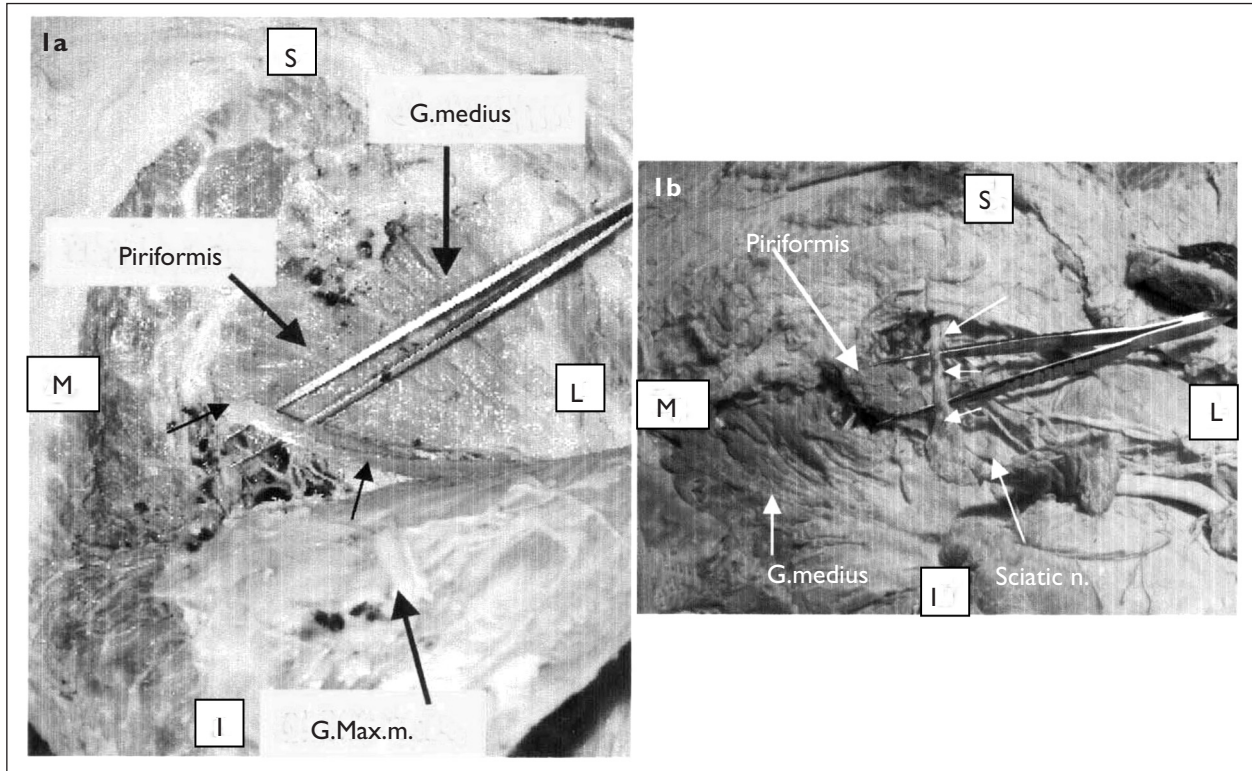


Fig.1 Photographs show (a) the accessory slip of the piriformis muscle (arrowhead) originating from the sacrotuberous ligament. The fibres of the slip are directed downwards and laterally and inserts into the main tendon of the piriformis muscle. (b) the main piriformis muscle is reflected and the three small arrows indicate the accessory slip of the piriformis.

G.medius: gluteus medius muscle; G.Max.m: gluteus maximus muscle; Sciatic n: sciatic nerve; S: superior; M: medial; I: inferior; L: lateral

where only one specimen showed a bipartite piriformis muscle, with the two components of the sciatic nerve being separate. Thus, anatomical variations causing piriformis syndrome are rare.⁽⁹⁾ On developmental grounds, these variations are considered to be due to the persistence of an undifferentiated group of mesenchymal cells.⁽¹⁰⁾

In conclusion, to our knowledge, not many cases of accessory piriformis muscles have been previously reported. Hence, the present report of these three cases is of anatomical and surgical interest. Under circumstances of undiagnosed pain in the gluteal region, an accessory slip of the piriformis muscle should be considered as a possible cause. Computed tomography and magnetic resonance imaging may be useful to confirm this diagnosis.

REFERENCES

1. Straus T. Vesalius and the problem of variability. *Bull Hist Med*

1943; 14:609-33.

2. Williams PL, Bannister LH, Berry MM, et al. The muscular system. In: Gray's Anatomy. 38th ed. London: Churchill Livingstone, 1995: 877.
3. Hollinshead HW. Anatomy for Surgeons. 3rd ed. Philadelphia: Harper & Row, 1982: 667.
4. Pandey S, Pandey AK. Clinical Orthopaedic Diagnosis. 2nd ed. New Delhi: Jaypee Brothers Medical, 2000: 177.
5. Saadeh FA. A bifid piriformis muscle with dual insertion. *Gegenbaurs Morphol Jahrb* 1988; 134:185-7.
6. Ozaki S, Hamabe T, Muro T. Piriformis syndrome resulting from an anomalous relationship between the sciatic nerve and piriformis muscle. *Orthopedics* 1999; 22:771-2.
7. Kirici Y, Yzar F, Ozan H. The neurovascular and muscular anomalies of the gluteal region: an atypical pudendal nerve. *Surg Radiol Anat* 1999; 21:393-6.
8. Chen WS. Bipartite piriformis muscle: an unusual cause of sciatic nerve entrapment. *Pain* 1994; 58:269-72.
9. Benzon HT, Katz AJ, Benzon HA, Iqbal MS. Piriformis syndrome anatomic considerations, a new injection technique, and a review of the literature. *Anesthesiology* 2003; 98:1442-8.
10. Carlson MB. Human Embryology & Developmental Biology. 2nd ed. St Louis: Mosby, 1999: 180-1.