

# Optic neuritis in Singapore

Lim S A, Goh K Y, Tow S, Fu E, Wong T Y, Seah A, Tan C, Cullen J F

## ABSTRACT

**Introduction:** Optic neuritis (ON) is the commonest optic neuropathy encountered in the younger group of patients from the Singapore Neuro-Ophthalmology Study Group. Previous surveys in Asia and our study suggest that ON in Singapore differs from that in Western populations where the majority of cases are associated with multiple sclerosis (MS).

**Methods:** Patients satisfying our entry criteria for ON seen between September 2002 and June 2004 were enrolled in the study. The data collected was recorded in a central database and analysed two years later.

**Results:** The majority (60 percent) of our patients had anterior ON with optic disc swelling (papillitis), were idiopathic in 49.1 percent, and associated with MS in only 25.5 percent. Bilateral cases comprised 16.4 percent of our series and were usually of the anterior variety and mostly idiopathic, although it is still essential to rule out secondary causes. Recurrent ON is indicative of an underlying disease process.

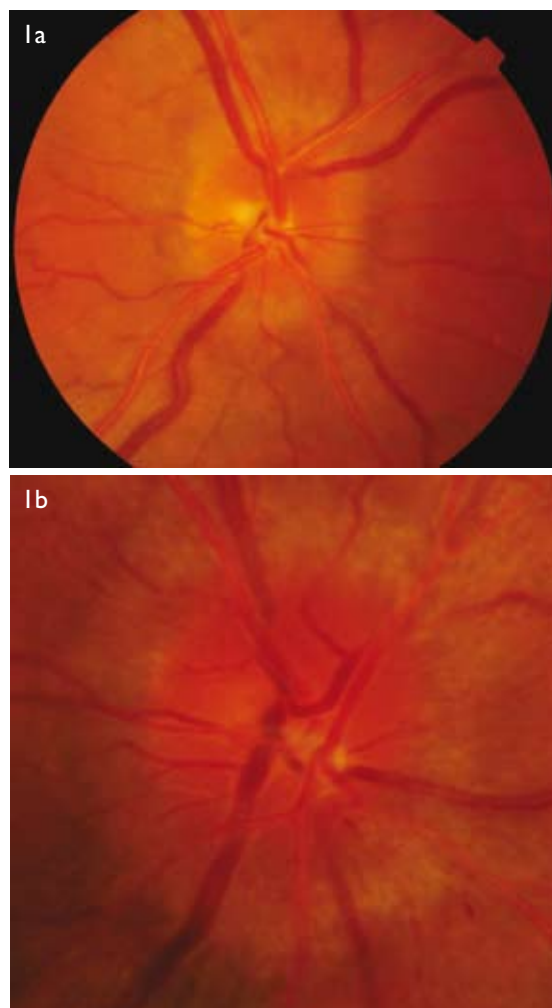
**Conclusion:** The pattern of ON as seen in Singapore differs from that reported in Caucasian studies and from the seminal Optic Neuritis Treatment Trial. We found a higher incidence of optic disc swelling, i.e. anterior ON (papillitis) and a lesser association with MS, visual recovery is similarly good but our recurrence rate is lower.

**Keywords:** optic disc swelling, idiopathic optic neuritis, multiple sclerosis, optic neuritis, papillitis, retrobulbar optic neuritis

*Singapore Med J 2008;49(9):667-671*

## INTRODUCTION

Optic neuritis (ON) is a potentially blinding, inflammatory, demyelinating condition affecting the optic nerve.<sup>(1)</sup> In Singapore, it is the commonest cause of an optic neuropathy in younger patients, with ischaemic optic neuropathy being the commonest overall.<sup>(2)</sup> In Western populations, ON is most frequently associated with multiple sclerosis (MS).<sup>(3)</sup> The Optic Neuritis Treatment Trial (ONTT),<sup>(4)</sup> a multicentre collaborative study carried out between 1988 and 1991 in the United States, has



**Fig. 1** Anterior ON (papillitis). (a) Photograph shows mild disc swelling and hyperaemia. (b) Photograph shows severe disc swelling and hyperaemia.

provided the seminal data on the natural history and clinical profile of ON, but its figures from a 85% Caucasian cohort may not be relevant to the multiethnic population in Singapore. Earlier reports from Japan,<sup>(5)</sup> Taiwan<sup>(6)</sup> and Singapore<sup>(7)</sup> have indeed suggested that ON is different in Asian patients in respect of its clinical profile, and has a much less frequent association with MS. In this report, we describe the pattern of ON in Singapore.

## METHODS

The Singapore Neuro-Ophthalmology Study Group (SNOSG) conducted a prospective, population-based investigation of neuro-ophthalmology cases (old and new) seen between September 2002 and June 2004 in our public

Neuro-Ophthalmology Service, Tan Tock Seng Hospital, 11 Jalan Tan Tock Seng, Singapore 308433

Lim SA, FRCSE Consultant

Goh KY, FRCSE Senior Consultant

Neuro-Ophthalmology Service, Singapore National Eye Centre, 11 Third Hospital Avenue, Singapore 168751

Tow S, FRCSE Senior Consultant

Fu E, FRCSG Visiting Consultant

Wong TY, FRCSE, PhD Senior Consultant

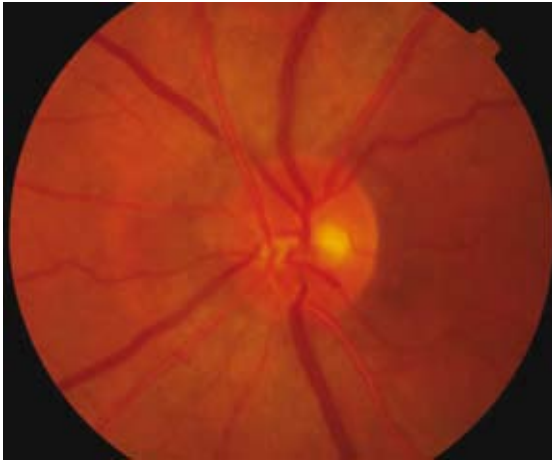
Seah A, MRCP Visiting Consultant Neurologist

Cullen JF, FRCS Senior Consultant

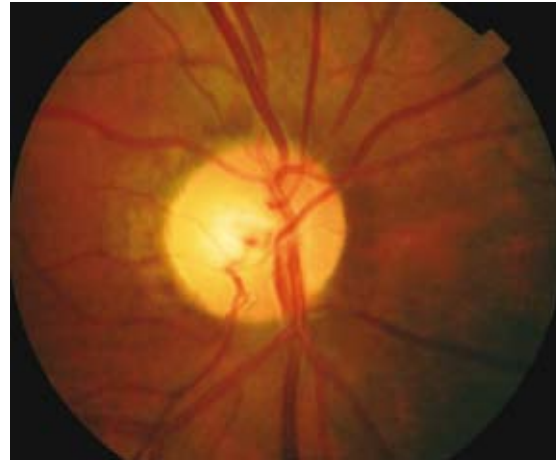Neuro-Ophthalmology Service, National University Hospital, 5 Lower Kent Ridge Road, Singapore 119074

Tan C, FRCSE Consultant

Correspondence to: Dr James F Cullen Tel: (65) 9044 6911 Fax: (65) 6226 3395 Email: jbarrycullen@yahoo.com



**Fig. 2** Photograph shows a normal optic disc as seen during the first six weeks of retrobulbar ON.



**Fig. 3** Photograph shows a pale optic disc (optic atrophy) as seen in late anterior and/or retrobulbar ON.

hospital subspecialty clinics at Tan Tock Seng Hospital, Singapore National Eye Centre, National University Hospital and Changi General Hospital. Patients were, in most instances, referred from general ophthalmology clinics either on the same day for urgent cases, or given an appointment for the next available specialty clinic.

The data forms were completed by the consultant neuro-ophthalmologists at their respective clinics and at monthly intervals the research coordinator collected the data forms for data entry at a central location. The investigators met regularly to perform interim analysis of the data and to adjudicate inconsistencies and questionable diagnoses. To prevent repeated entry of cases, the forms were duplicated, with one set retained in the patient's records. Each case was coded according to the International Classification of Diseases, Ninth Revision Clinical Modification (ICD-9). For the purposes of this particular study, ON was subcoded as follows: (a) ON, unspecified (ICD-9, 377.30); (b) anterior ON or papillitis (ICD-9, 377.31); and (c) retrobulbar ON (ICD-9, 377.32).

For inclusion of patients with the diagnosis of ON in our database, they had to fulfil the following four criteria:

- (1) Sustained unilateral or bilateral decreased visual acuity of  $\leq$  four weeks' duration as measured by the Snellen chart.
- (2) Demonstrated unilateral or bilateral loss of colour vision on Ishihara plates.
- (3) Have a relative afferent papillary defect, unless symptoms were symmetrical and bilateral.
- (4) Demonstrated a visual field defect by confrontation or by automated or manual testing.

In addition, the presence of optic disc swelling indicated anterior ON or papillitis (Figs. 1a & b), while the absence of disc swelling indicated a retrobulbar ON (RBN) (Figs. 2 & 3).

If the presentation of ON recurred  $<$  30 days from the first attack, it was considered a relapse; whereas if it occurred  $\geq$  30 days later, it was considered to be a new attack, or a recurrence as defined by McDonald et al.<sup>(8)</sup> The diagnosis of MS was based on the patient's history and/or case note records from the ophthalmology or neurology clinics; case records were also searched for any other reported possible underlying aetiology for the ON, which was therefore classified as follows:

- (1) Idiopathic: When ON was diagnosed in the absence of MS or other systemic disease.
- (2) ON associated with MS: When ON was associated with MS as recorded in the patient records or from his/her history.
- (3) Infective or ON secondary to an autoimmune disorder: When ON was found to be secondary to an infective process, e.g. syphilis, or associated with an autoimmune condition, such as Sjogren's syndrome or systemic lupus erythematosus.
- (4) Autoimmune ON: If ON was corticosteroid dependent with positive autoimmune markers, but did not fit the diagnostic criteria for a specific autoimmune disorder in accordance with the definition of Dutton et al.<sup>(9)</sup>
- (5) Recurrent idiopathic ON: In cases where ON was recurrent in accordance with the McDonald criteria but not associated with MS or any other systemic disease.
- (6) Neuroretinitis: When ON was associated with retinal oedema and macular star formation.

The data was analysed using the Statistical Package for Social Sciences version 11.0 (SPSS Inc, Chicago, IL, USA) two years after completion of collection and recording. The research was conducted according to the Declaration of Helsinki, and the institutional review boards of the four

**Table I. Comparison of demographical and clinical characteristics of patients with optic neuritis.**

Authors:	SNOSG	ONTT <sup>(4)</sup>	Lin et al <sup>(6)</sup>	Wakakura et al <sup>(5)</sup>
Country:	Singapore (n = 55)	USA (n = 448)	Taiwan (n = 109)	Japan (n = 70)
Females (%)	76.3	77.2	53.2	69.0
Age range (years)	12–70	18–46	7–80	14–55
Pain (%)	70.9	92.2	58.7	56.0
Phosphenes (%)	7.1	30.4	U	U
Uhthoff's syndrome (%)	7.1	U	U	U
MS* (%)	25.5	30.1 (PS, P, D) 13.0 (P, D)	Nil	5.6 (P, D)
Previous ON (%)	21.8	Nil	U	Nil
Disc swelling (%)	60.0	35.3	53.2	50.0
Disc haemorrhage (%)	16.4	5.6	16.5	U
Bilateral (%)	16.4	Nil	34.9	Nil

\* PS: possible multiple sclerosis; P: probable multiple sclerosis; D: definite multiple sclerosis; U: unreported.

**Table II. Analysis of the different aetiologies of optic neuritis in 55 patients.**

Aetiology of ON from SNOSG (n = 55)	Anterior ON (papillitis)	Retrobulbar ON
Idiopathic	19	8
Multiple sclerosis	3	11
Infective/associated with autoimmune disease	5	0
Autoimmune ON	2	1
Recurrent idiopathic ON	2	2
Neuroretinitis	2	0
Total	33	22

SNOSG: Singapore Neuro-Ophthalmology Study Group; ON: optic neuritis

public hospitals involved granted approval for the study.

## RESULTS

A total of 1,506 neuro-ophthalmic cases, including 902 new patients, were seen during the study period from September 2002 to June 2004. There were 60 cases of ON as specified in the database coded as noted above under ICD-9, 377.30, 377.31 and 377.32. Four patients were later excluded because they presented more than three months after the onset of symptoms, and one patient was excluded due to uncertainty of diagnosis on review. Thus analysis was performed on the remaining 55 patients. The demographics and the clinical features of patients in our series are shown in Table I, along with those of the ONTT and the reports from Taiwan and Japan. Of our patients, 80.7% were Singapore residents, with 71.9% being Chinese, 10.5% Malays, 8.8% Indians and 8.8% minority races. As expected, 58.2% were between the ages of 21 and 40 years with a peak in the 31–40 year age group (range 12–70 years). 76.3% were females. The initial symptoms and clinical findings along with the incidence of associated MS at presentation are also shown in Table I, where it should be noted that a swollen disc (papillitis) was found in 60.0% (n = 33) and disc haemorrhages in

16.4% (n = 9) of our patients, in contrast to the 35.3% and 5.6%, respectively, reported from the ONTT.

The aetiology of ON as determined by review of the case records two years after the conclusion of the study is shown in Table II, where it can be seen that 49.1% (n = 27) of our cases were idiopathic. MS was found in 25.5% (n = 14), while infective causes and ON secondary to autoimmune disease accounted for 9.1% (n = 5), and 5.5% (n = 3) had autoimmune ON. We obtained follow-up information on 60.4% of patients with unilateral ON and 66.7% of patients with bilateral disease; this level of follow-up is accepted as the maximum achievable from such a local cohort of public service patients. In the unilateral group, 75.9% achieved 6/12 or better visual acuity, compared to 17.2 percent with this level of vision at study entry. Visual recovery was worse in patients with more severe loss at the outset; thus for patients with initial visual acuity of counting fingers or worse, 58.8% recovered to 6/12 or better at six months. Recovery of colour vision paralleled that of visual acuity with 69.0% of patients being able to identify 13–15 of 15 Ishihara plates at six months. Even among those patients who were only able to identify four or fewer of the plates initially, 63.6% identified 13–15 of 15 Ishihara plates after six months.

In the bilateral group, all patients achieved 6/12 or better visual acuity and identified 13–15 of 15 Ishihara plates at six months even in the eye with more severe initial involvement.

Nine patients (16.4%) presented with bilateral simultaneous ON and were similar to the entire cohort, except that males appeared significantly more prone to sustain a bilateral ON ( $p = 0.019$ , four females and five males), one of these nine was known to have MS and another ankylosing spondylitis. In the course of the study, one further patient developed MS and another was found to have syphilis, while six remained idiopathic. Seven of these nine patients exhibited papillitis, while two (those with ankylosing spondylitis and MS) had retrobulbar disease. 12 patients had a history of ON at entry, and seven of them had already been diagnosed with MS, one further patient had autoimmune ON and four were idiopathic. At the conclusion of the study, four additional patients were found to have developed a second attack of ON, two of these also being diagnosed with MS, one other with Sjogren's syndrome and one with autoimmune ON. Therefore, of the 16 patients (29.1%) with repeated attacks of ON, eventually nine had MS, two autoimmune ON and one Sjogren's syndrome; while four remained idiopathic.

11 patients had a past history of MS at study entry. At the end of four years, three additional patients were similarly diagnosed, hence our four-year probability of developing MS was 9.1%. We looked in detail at these three patients, all were females aged 27, 30 and 61 years respectively, and all developed the retrobulbar variety of ON. The two patients, aged 30 and 61 years, had recurrent attacks and subsequently developed transverse myelitis, and were thus diagnosed with the opticospinal form of MS commonly seen in Singapore. The final patient, aged 27 years, had white matter lesions on brain magnetic resonance imaging that were also consistent with the diagnosis of MS.

## DISCUSSION

This prospective study of ON carried out in specialist neuro-ophthalmology clinics in Singapore was planned to characterise the clinical features of the condition in our local patients and to elucidate its causes and prognosis. The ONTT is recognised as the seminal study in these areas, but was set up initially to determine whether corticosteroids were effective in the treatment of ON, and as 85% of the 448 cases studied were Caucasian,<sup>(4)</sup> its findings cannot readily be applied to our patients.

Table I compares data from our study with that from the ONTT<sup>(4)</sup> and with the reports from Japan<sup>(5)</sup> and Taiwan.<sup>(6)</sup> The earlier local study of Wang et al was

retrospective in nature with a smaller cohort of 31 patients from a single institution, and had only 37.8% of female patients.<sup>(7)</sup> This study cannot therefore be compared with ours, where it can be seen that our female proportion of patients (76.3%) is similar to that of the ONTT (77.2%),<sup>(4)</sup> though higher than in the other two Asian studies.<sup>(5,6)</sup> The age range of the patients was the lowest in the ONTT (18–46 years),<sup>(4)</sup> the highest in the Taiwanese study (7–80 years),<sup>(6)</sup> while our age range was 12–70 years. With respect to pain at presentation, which is the textbook norm, our figure of 70.9% and the others from Asia<sup>(5,6)</sup> were surprisingly lower than that found in the ONTT;<sup>(4)</sup> the other significant difference is our higher incidence (60%) of a swollen disc (papillitis) compared to ONTT's 35.3%. Disc haemorrhages were also more common in our patients, in keeping with the other Asian study.<sup>(6)</sup> On further analysis of the disc appearance in the different categories of ON (Table II), papillitis was found in 70.4% of idiopathic cases, but only in 21.4% of the MS patients, and occurred in a majority of patients where the ON was associated with the other rarer causes.

Most previous studies dealing with ON had concentrated on its association with MS or on idiopathic cases, but had given little information as to other possible underlying systemic causes. We therefore attempted to verify the aetiology in all our patients at the conclusion of the study (2–4 years of follow-up) and found that 14 out of our 55 cases (25.5%) had an aetiology other than MS or were idiopathic. This figure is comparable to those of Wakakura et al who had 31.4% of secondary cases exclusive of MS,<sup>(5)</sup> and those of Lin et al who had 22.3%.<sup>(6)</sup> Therefore, it would appear that ON in Asia may have an aetiology other than MS in more than 20% of cases, which is in keeping with the latter's known lesser incidence in Asian populations.<sup>(10)</sup> Bilateral simultaneous ON occurred in 16.4% of our patients, whereas a rate of 34.9% was reported in the Asian reports of Lin et al<sup>(6)</sup> and 19.2% by Wang et al.<sup>(7)</sup> In contrast, de la Cruz and Kupersmith from New York reported an incidence of only 6.8%, but they excluded MS, toxic optic neuropathy and Devic's disease.<sup>(11)</sup> Most reported cases of bilateral simultaneous ON occurred in children often following a viral illness and were rarely associated with MS.<sup>(12)</sup> With respect to our nine bilateral patients, five were male adults, seven had papillitis and six were idiopathic. In these nine cases, the secondary causes, other than MS, were syphilis and ankylosing spondylitis, thus we advocate full investigations for all cases of bilateral simultaneous ON in order to exclude an infective or autoimmune cause.

We found that visual recovery was good both in unilateral and bilateral ON patients. In unilateral cases,

75.9% regained 6/12 or better visual acuity, while 100% of those with bilateral ON regained 6/12 or better visual acuity. In the review of the ONTT patients at six months when 438/448 cases were followed-up, 93.3% recovered to 6/12 or better visual acuity,<sup>(13)</sup> while Wakahura et al reported that over 70% of their patients regained 6/6 or better visual acuity at one year.<sup>(14)</sup> Our apparent overall poorer visual recovery can be explained by the fact that we included all cases of ON regardless of an underlying cause, not just those associated with MS and idiopathic cases which have a better rate of visual recovery.

12 of our patients had a past history of ON at study entry and four had a second attack during the four-year study period. Of these 16 patients (29.1% of the total 55), nine had MS, two had autoimmune ON, one had Sjogren's syndrome, and only four had idiopathic disease. The five-year results from the ONTT also reported that 28% of patients had a recurrence of ON, and that this was more frequent in their MS group.<sup>(15)</sup> From the experience of the ONTT, the ten-year overall risk of developing MS was 38%, but only 22% if there were no plaques on magnetic resonance imaging, and 56% with plaques on magnetic resonance imaging.<sup>(16)</sup> Lin et al also compared the risks of developing MS from different studies, with the highest rates in the United Kingdom (59% over ten years), and the lowest in Japan (8.3% over 5.2 years).<sup>(6)</sup> The risk of our Singapore ON patients developing MS was 9.1% within four years.

In conclusion, for Asian patients presenting with ON, our study showed that 25.5% will have MS at the outset, and the four-year risk of developing MS is 9.1%. Half of Asian ON cases appear to be idiopathic, and a quarter have causes other than MS. Bilateral simultaneous ON occurs in 16.4% of patients, is more common in males, more often anterior and is mainly idiopathic. The risk of repeated attacks of ON is 29%. Visual outcome is good with 75.9% of our patients recovering 6/12 or better visual acuity in unilateral ON, and 100% in bilateral ON. Our results are comparable to those reported from other Asian studies which are in agreement with our important findings that the incidence of optic disc swelling (papillitis) and

optic disc haemorrhage is higher, whereas the recurrence rates and conversion to MS are lower than reported from Western countries.

## REFERENCES

1. Smith CH. Optic neuritis. In: Miller NR, Newman NJ, eds. Walsh and Hoyt's Clinical Neuro-ophthalmology. 6th ed. Baltimore: Williams and Wilkins, 2005: 239-47.
2. Cullen JF, Por YM. Ischaemic optic neuropathy: the Singapore scene. *Singapore Med J* 2007; 48:281-6.
3. Ebers GC. Optic neuritis and multiple sclerosis. *Arch Neurol* 1985; 42:702-4.
4. The clinical profile of optic neuritis. Experience of the Optic Neuritis Treatment Trial. Optic Neuritis Study Group. *Arch Ophthalmol* 1991; 109:1673-8.
5. Wakakura M, Minei-Higa R, Oono S, et al. Baseline features of idiopathic optic neuritis as determined by a multicenter treatment trial in Japan. Optic Neuritis Treatment Trial Multicenter Cooperative Research Group (ONMRG). *Jpn J Ophthalmol* 1999; 43:127-32.
6. Lin YC, Yen MY, Hsu WM, et al. Low conversion rate to multiple sclerosis in idiopathic optic neuritis patients in Taiwan. *Jpn J Ophthalmol* 2006; 50:170-5.
7. Wang JC, Tow S, Tin A, et al. The presentation, aetiology, management and outcome of optic neuritis in an Asian population. *Clin Experiment Ophthalmol* 2001; 29:312-5.
8. McDonald WI, Compston A, Edan G, et al. Recommended diagnostic criteria for multiple sclerosis: guidelines from the International Panel on the diagnosis of multiple sclerosis. *Ann Neurol* 2001; 50:121-7.
9. Dutton JJ, Burde RM, Klingele TG. Autoimmune retrobulbar optic neuritis. *Am J Ophthalmol* 1982; 94:11-7.
10. Das A, Puvanendran K. A retrospective review of patients with clinically defined multiple sclerosis. *Ann Acad Med Singapore* 1998; 27:204-9.
11. de la Cruz J, Kupersmith MJ. Clinical profile of simultaneous bilateral optic neuritis in adults. *Br J Ophthalmol* 2006; 90:551-4.
12. Boomer JA, Siatkowski RM. Optic neuritis in adults and children. *Semin Ophthalmol* 2003; 18:174-80.
13. Beck RW, Cleary PA, Backlund JC. The course of visual recovery after optic neuritis. Experience of the Optic Neuritis Treatment Trial. *Ophthalmology* 1994; 101:1771-8.
14. Wakakura M, Mashimo K, Oono S, et al. Multicentre clinical trial for evaluating methylprednisolone pulse treatment of idiopathic optic neuritis in Japan. *Jpn J Ophthalmol* 1999; 43:133-8.
15. Visual function 5 years after optic neuritis: experience of the Optic Neuritis Treatment Trial. The Optic Neuritis Study Group. *Arch Ophthalmol* 1997; 115:1545-52.
16. Beck RW, Trobe JD, Moke PS, et al. High- and low- risk profiles for development of multiple sclerosis with 10 years after optic neuritis: experience of the Optic Neuritis Treatment Trial. *Arch Ophthalmol* 2003; 121:944-9.