

# Continuous figure-of-eight suturing in upper and lower gastrointestinal anastomosis

Hussain A, Mahmood H, Nicholls J, El-Hasani S

## ABSTRACT

**Introduction:** The optimal technique for gastrointestinal anastomosis is controversial. The three most popular techniques are two layers, one layer and the stapling method. However, there is no universal agreement on the best technique. The aim of this study was to evaluate the safety, feasibility, and efficacy of continuous figure-of-eight suturing in gastrointestinal anastomosis.

**Methods:** This was a retrospective study of 170 patients who underwent gastrointestinal anastomosis using continuous figure-of-eight suturing for the first layer and continuous seromuscular suturing for the second layer from August 1993 to January 2006. All operations were performed by a single consultant surgeon. We assessed each anastomosis by checking the integrity, vascularity and patency, and also ensuring tension-free status. Postoperatively, patients were managed by routine care of intravenous fluids and nasogastric tube until they had active bowel sounds and started absorbing. Imaging was arranged for patients who developed clinical signs and symptoms of leak.

**Results:** 170 patients underwent gastrointestinal anastomosis by continuous figure-of-eight suturing for different pathologies over a two-and-a-half-year period. There were 92 (54.1 percent) men and 78 (45.9 percent) women. The mean age of the patients was 56 (range 20–88) years. The median follow-up was 74 months. There were 124 (72.9 percent) small bowel anastomosis and 46 (27.1 percent) large bowel anastomosis. An important complication after gastrointestinal anastomosis was leakage, which was reported in three (1.8 percent) patients. One of them had gastric cancer, one had Crohn's disease and one had intestinal ischaemia. No mortality was reported in relation to anastomotic failure. Two (1.2 percent) patients developed stenosis and 15 (8.8 percent) patients died because of progression of their disease or other pathologies during the follow-up.

**Conclusion:** Continuous figure-of-eight suturing is a simple, easy to learn, safe and satisfactory

upper and lower gastrointestinal anastomosis technique.

**Keywords:** continuous figure-of-eight suturing, gastrointestinal anastomosis, gastrointestinal tract, suturing techniques

*Singapore Med J 2008; 49(9): 672-675*

## INTRODUCTION

The development in the diagnostic facilities and surgical service has contributed to the improvement of the outcome of gastrointestinal anastomosis (GIA). However, there is no universal agreement about the best technique for GIA. Predicted fear of increased postoperative complications secondary to the anastomotic failure has resulted in a diversity of techniques. Historically, two-layer anastomosis using interrupted silk sutures for an outer inverted seromuscular layer and a running absorbable suture for a transmural inner layer has been standard for most surgical situations.<sup>(1)</sup> It is still one of the preferred methods although a single layer anastomosis is continuing to be a method of choice for many surgeons. Stapling anastomosis is another popular technique in many centres.

We usually used the continuous figure-of-eight (CFO8) technique for gastrointestinal anastomosis. This technique fulfils two functions. Firstly, it acts as haemostatic suturing to prevent anastomosis line bleeding; and secondly, it will bring the two sides of the mucosa together with satisfactory alignment, which ensures the integrity and watertight feature of an ideal anastomosis. The theoretical fear of anastomosis line strangulation and necrosis which was proposed by several authors in criticising the continuous GIA suturing was not confirmed in our study. Although this method was used in procedures of other specialities such as ophthalmology,<sup>(2,3)</sup> according to our knowledge, there was no report of its use in gastrointestinal surgery. This study evaluated the CFO8 technique as a method of GIA.

## METHODS

This is a retrospective study of 170 patients who underwent GIA using CFO8 from August 1993 to January 2006. All patients signed the informed consent and the procedure

Department of  
General Surgery,  
Princess Royal  
University Hospital,  
Farnborough  
Common,  
Orpington BR6 8ND,  
Kent,  
UK

Hussain A, FRCS  
Senior Clinical Fellow

Mahmood H,  
MBChB,  
Clinical Fellow

Nicholls J, RGN,  
ASP  
Perioperative  
Practitioner

El-Hasani S,  
MBChB, FRCS  
Consultant

**Correspondence to:**  
Dr Abdulzahra  
Hussain  
Tel: (44) 79 4939 3892  
Fax: (44) 16 8986 4488  
Email: azahrahussain  
@yahoo.com

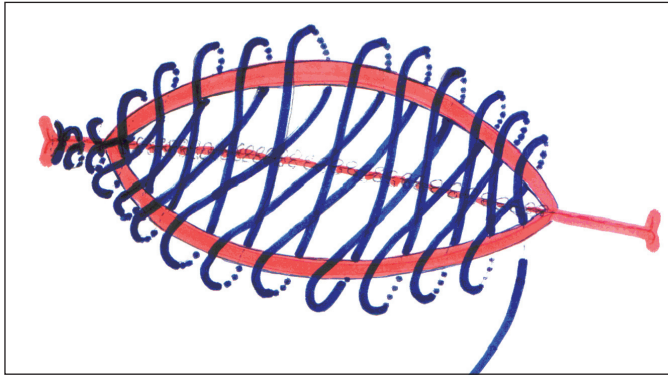


Fig. 1 Diagram shows the CFO8 anastomosis for the first layer.

detail was explained to them. Patients were considered for entry into the study if they were having their anastomosis performed by CFO8 technique, regardless of the pathology, the age, and the American Society of Anaesthesiologists (ASA) grading. A single consultant surgeon performed all the procedures. The operations which were done by trainees or other consultants in the surgical unit were excluded from this study.

After identifying the diseased segment and the decision to resect or bypass was taken depending on the pathology, two non-crushing clamps were applied proximally and distally. The anastomosis could be end-to-end, end-to-side, side-to-side, or side-to-end. We preferred side-to-side anastomosis when feasible. A good sized stoma of at least 5 cm was ensured in all cases. The surgeon had the choice to do either the first layer or the posterior second layer first. Polydioxanone (PDS) or vicryl suture was used for CFO8 anastomosis for the first layer. The suturing started at the angle with: out-in then in-out and knotting the suture, then in-out, in-out, and so on. The resulted suturing would be a CFO8 with a good edge-to-edge alignment without mucosal eversion (Fig. 1). A second layer of continuous suturing was inserted as a backup layer. The intraoperative integrity, patency, vascularity, and non-tension anastomosis was checked at the end of procedure. Postoperative routine management was applied and follow-up as outpatient assessment was arranged for all patients. Clinical leak was investigated using gastrografin contrast study and computed tomography (CT).

## RESULTS

170 patients who were underwent GIA by CFO8 for different pathologies were included in this study. There were 92 (54.1%) males and 78 (45.9%) females. There were 124 (72.9%) small bowel anastomosis and 46 (27.1%) large bowel anastomosis. Anastomosis was

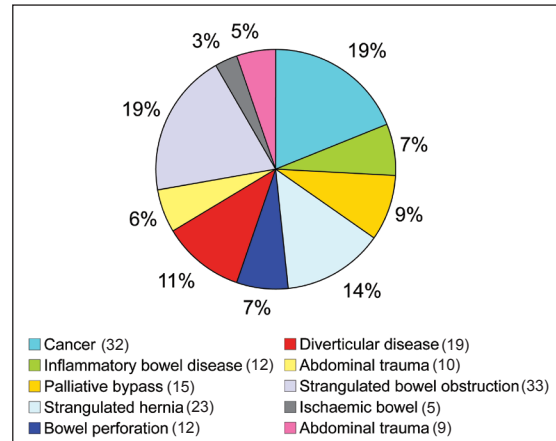


Fig. 2 Pie chart shows the indications (by number and percentage) for GIA.

performed for 32 (18.8%) patients with cancer, 12 (7.1%) with inflammatory bowel disease, 15 (8.8%) for bypass for non-resectable tumours, 23 (13.5%) for resection for strangulated hernia, 12 (7.1%) for bowel perforation, 19 (11.2%) for diverticular disease of the colon, 9 (5.3%) for abdominal trauma, 10 (5.9%) for upper and lower gastrointestinal tract bleeding, 33 (19.4%) for strangulated bowel obstruction and five (2.9%) for ischaemic bowel. Only one out of six consultant surgeons in the unit used this anastomosis technique.

The mean age of the patients was 56 (range 20–88) years. The median follow-up period was 74 months (range 1.5–13.5 years). The most important complication was anastomotic leakage. Three (1.8%) patients developed anastomotic leak. One patient had gastric cancer, one had Crohn's disease and one had intestinal ischaemia. Two (1.2%) patients who had gastrointestinal cancer developed stenosis. No case of clinical stenosis or obstruction was reported for the remaining 168 patients, and no perioperative mortality was reported in relation to anastomotic failure. 15 (8.8%) patients died because of progression of their primary disease or unrelated other pathologies during the follow-up period.

## DISCUSSION

There is a continuing debate on the best technique for GIA, but widespread agreement regarding the criteria of ideal anastomosis, which should fulfil the following: (a) It must be well-vascularised, (b) safe ("waterproof"), (c) easily feasible, (d) tension-free, (e) spillage should be avoided, and (f) should be inexpensive.<sup>(4)</sup> Different methods and sutures have been used for GIA,<sup>(5-17)</sup> and these clearly represent differences and the wide choices available for surgeons. One of the principle issues was to perform GIA by a single layer or two layers. Both methods were extensively investigated and discussed in the literature and a large number of authors preferred a two-

**Table I. Morbidity and mortality for different gastrointestinal anastomotic techniques.**

Authors	No. anastomosis	Technique	Leak percent	Mortality percent
Oláh et al <sup>(17)</sup>	247	Single layer	2.0	0
Leslie and Steele <sup>(7)</sup>	553	Interrupted seromuscular	0.2	0
Thiede et al <sup>(13)</sup>	1,666	Biofragmentable ring	2.04	3
Burch et al <sup>(6)</sup>	67	Two layers	1.5	0

layer technique for GIA. However, the debate continues from the days of Halsted, and there have been several theoretical, experimental and practical arguments against the two-layer technique. Examples of these are snagging problems and linear necrosis by strangulation.

A meta-analysis of randomised controlled trials has compared the two- and one-layer techniques, and no evidence was found that two-layer GIA leads to fewer postoperative leaks than single-layer GIA. The duration of the anastomosis and medical expenses in single-layer GIA appears to be better than other methods.<sup>(1)</sup> Every surgeon has his preferred method of anastomosis, depending on his personal experience, his career progression and the evidence-based medicine. We chose the CFO8 technique because it provides good alignment and haemostasis, and prevents eversion of the edges at the anastomosis line. It is our preferred hand-sewn technique and we use it when a stapling method is considered inappropriate.

Anastomotic leakage is the most important complication specific to intestinal surgery,<sup>(18)</sup> often followed by serious morbidity or death, after resection or bypass operations of the intestine in the emergency and elective setting. The surgeon's experience and method of suturing, in addition to certain factors such as preoperative steroid use, longer duration of operation, and contamination of the operative field, will influence the outcome.<sup>(19)</sup> The recent studies have shown that the incidence of anastomotic failure is decreasing. This is due to the evolution in surgical practice and dramatic movement from diagnose and treat, to investigate the causative factors and prevent them or take reasonable steps to reduce their effects. Examples of these factors are shock, peritoneal sepsis, advanced age, malignancy, malnutrition, coagulopathy, steroid dependence, uraemia, radiation therapy, diabetes mellitus, perforation, anaemia, faecal soiling, and deficiencies of vitamin C, iron and zinc.<sup>(20)</sup> Other major contributors to the improved management of GIA disruption are intensive care units, antibiotics, nutritional support, and implementation of the enhanced recovery after surgery programme (ERAS), which may further reduce the morbidity and increase survival in these patients.<sup>(21,22)</sup>

We only experienced three leaks following GIA. The first one was a gastric cancer patient who had had

subtotal gastrectomy and gastroduodenal anastomosis. The second was a small bowel anastomosis for Crohn's disease, while the third one was small bowel anastomosis for bowel ischaemia. The leaks were diagnosed on clinical grounds and were confirmed by gastrograffin study and CT. The first patient required laparotomy and revision of the anastomosis. The other two were treated conservatively by drainage and intravenous fluids. All patients responded very well and were discharged in a stable condition. No perioperative mortality was recorded but the follow-up records showed that 15 (8.8%) patients died because of progression of the disease for which the anastomosis was performed (resection or bypass) or other unrelated pathologies. There were follow-up investigations to exclude stenosis at the anastomotic region for clinically-symptomatic patients. Two patients who had gastrointestinal cancer were diagnosed with stenosis at the anastomotic site within two years of the operation. A stent was inserted for one patient while bypass surgery was performed for the other. No immediate or late stenosis or stricture was reported in the remaining patients. This may be because we were very careful in performing a good sized stoma, not less than 5 cm for all patients and using side-side anastomosis when possible.

In our technique, the two-layer anastomosis contributes to the outcome of the anastomosis. We believe the important step is the first CFO8. However, because we were using a second supporting layer, it is difficult to assume that the efficacy and safety of the technique is only due to the CFO8 as a single layer of anastomosis. Therefore, the second continuous seromuscular layer is a supporting and contributing factor to the outcome. Moreover, if we compare our results to the two-layer technique studies in which the surgeons had used simple continuous suturing or even continuous single layer suturing, our results will be comparable or even better.<sup>(23-25)</sup> PDS and vicryl sutures which are both absorbable and of good strength were used to complete the anastomoses. We used either suture type depending on the availability in the operating theatre.

In the current surgical era, our study would require a comparison group, either a group with a different technique or randomised prospective trial. There was difficulty in selecting the previous study groups to compare our

results to because of the diversity of the study designs, randomisation, and the type of the technique and sutures. We randomly chose four studies from the literature based on the type of techniques as the major criteria to compare and contrast our results (Table 1).<sup>(6,7,13,17)</sup> Our results were comparable to these series. We suggest this technique for upper and lower gastrointestinal surgery. There were 124 (72.9%) upper GIA and 46 (27.1%) large bowel anastomosis. Our results showed three upper gastrointestinal leaks for the whole series. Interestingly, no clinical leak was reported for colorectal anastomosis. There is little consensus regarding acceptable rates of leakage that required surgery after colorectal operations; however, its incidence is varied but reported as low as 0.8%.<sup>(26)</sup> Although only 27.1% colorectal anastomosis were performed using the CFO8 technique, the incidence of leak was statistically significant ( $p < 0.05$ ) when compared to other studies.<sup>(17,27)</sup> This supports our technique of CFO8 in providing a safe and effective method not only for upper but also for lower GIA.

A possible limitation of our study is the mixture of indications, resection types and underlying diseases. These differences are expected to influence the outcome. However, in spite of 38% of patients (Fig. 2) having their anastomosis performed for indications with potential risk of leak (cancer, inflammatory bowel disease, palliative anastomosis and ischaemic bowel), we had an acceptable leak rate and perioperative mortality. Nevertheless, leak incidence is variable and can be related to the technique and experience of the surgeon, patient's factors, baseline support and available facilities. Therefore, the introduction of a new technique is imperative to improve the overall outcomes, provided the above-mentioned influencing factors are guaranteed. This will support our technique rather than indicate weakness, although we agree that this experience can be investigated further by a well-designed, controlled and randomised larger study involving the upper or lower gastrointestinal tract to confirm our results. In conclusion, the CFO8 suturing technique is safe, easy to perform and applicable for upper and lower GIA.

## REFERENCES

- Shikata S, Yamagishi H, Taji Y, Shimada T, Noguchi Y. Single-versus two-layer intestinal anastomosis: a meta-analysis of randomized controlled trials. *BMC Surg* 2006; 6:2.
- Evereklioglu C, Oner A, Somdaş MA, et al. Figure-of-eight vertical mattress suture technique for anterior flap suspension to overlying tissues in external dacryocystorhinostomy. *Am J Ophthalmol* 2007; 143:328-33.
- Dietz UA, Debus ES, Thiede A, Kuhfuss I. Inverting bilateral figure-of-eight suture of the rectus sheath after burst abdomen with destruction of the linea alba: a new technique. *J Plast Reconstr Aesthet Surg* 2007; 60:389-92.
- Steinke W, Leippold T, Schweizer W. Gastrointestinal extramucous running suture anastomosis. *Swiss Surg* 2003; 9:114-20.
- Zoedler T, Becker H, Roher HD. [Continuous single layer anastomosis as the standard procedure in the gastrointestinal tract]. *Chirurg* 1995; 66:50-3. German.
- Burch JM, Franciose RJ, Moore EE, Biffl WL, Offner PJ. Single-layer continuous versus two-layer interrupted intestinal anastomosis: a prospective randomized trial. *Ann Surg* 2000; 231:832-7.
- Leslie A, Steele RJ. The interrupted serosubmucosal anastomosis - still the gold standard. *Colorectal Dis* 2003; 5:362-6.
- Max E, Sweeney WB, Bailey HR, et al. Results of 1,000 single-layer continuous polypropylene intestinal anastomoses. *Am J Surg* 1991; 162:461-7.
- Littke MP, Markgraf R. [Continuous single-layer technique in turnable and nonturnable gastrointestinal anastomoses. A prospective observational study of emergency and elective operations]. *Zentralbl Chir* 2002; 127:992-6. German.
- Moriura S, Kobayashi I, Ishiguro S, et al. Continuous mattress suture for all hand-sewn anastomoses of the gastrointestinal tract. *Am J Surg* 2002; 184:446-8.
- Hirata K, Konishi T, Ueda Y, et al. [Healing in the intestinal anastomosis--comparison of the Albert-Lembert and Gambee method]. *J UOEH*. 2000; 22:1-6. Japanese.
- Catena F, La Donna M, Gagliardi S, Avanzolini A, Taffurelli M. Stapled versus hand-sewn anastomoses in emergency intestinal surgery: results of a prospective randomized study. *Surg Today* 2004; 34:123-6.
- Thiede A, Geiger D, Dietz UA et al. Overview on compression anastomoses: biofragmentable anastomosis ring multicenter prospective trial of 1666 anastomosis. *World J Surg* 1998; 22:78-86.
- Di Castro A, Biancari F, Brocato R, et al. Intestinal anastomosis with the biofragmentable anastomosis ring. *Am J Surg* 1998; 176:472-4.
- Kim SH, Choi HJ, Park KJ, et al. Sutureless intestinal anastomosis with the biofragmentable anastomosis ring: experience of 632 anastomosis in a single institute. *Dis Colon Rectum* 2005; 48:2127-32.
- Oláh A, Belágyi T, Neuberger G, Hegedús L. [Single layer continuous absorbable sutures for gastrointestinal anastomosis]. *Magy Seb* 1999; 52:63-6. Hungarian.
- Oláh A, Belágyi T, Neuberger G, Gamal EM. Use of different absorbable sutures for continuous single-layer anastomosis in the gastrointestinal tract. A prospective, randomized study. *Dig Surg* 2000; 17:483-5.
- Lipska MA, Bissett IP, Parry BR, Merrie AE. Anastomotic leakage after lower gastrointestinal anastomosis: men are at a higher risk. *ANZ J Surg* 2006; 76:579-85.
- Konishi T, Watanabe T, Kishimoto J, Nagawa H. Risk factors for anastomotic leakage after surgery for colorectal cancer: results of prospective surveillance. *J Am Coll Surg* 2006; 202:439-44.
- Kostic LL. [Sutures in digestive surgery]. *Acta Chir Jugosl* 1994; 41(2 Suppl 2):211-20. Croatian.
- Pickleman J, Watson W, Cunningham J, Fisher SG, Gamelli R. The failed gastrointestinal anastomosis: an inevitable catastrophe. *J Am Coll Surg* 1999; 188:473-82.
- Lobo DN, Macafee DA, Allison SP. How perioperative fluid balance influences postoperative outcomes. *Best Pract Res Clin Anaesthesiol* 2006; 20:439-55.
- Sarin S, Lightwood RG. Continuous single-layer gastrointestinal anastomosis: a prospective audit. *Br J Surg* 1989; 76:493-5.
- AhChong AK, Chiu KM, Law IC, Chu MK, Yip AW. Single-layer continuous anastomosis in gastrointestinal surgery: a prospective audit. *Aust N Z J Surg* 1996; 66:34-6.
- Ceraldi CM, Rypins EB, Monahan M, Chang B, Sarfeh II. Comparison of continuous single layer polypropylene anastomosis with double layer and stapled anastomoses in elective colon resections. *Am Surg* 1993; 59:168-71.
- Jones OM, John SK, Horseman N, Lawrance RJ, Fozard JB. Low anastomotic leak rate after colorectal surgery: a single-centre study. *Colorectal Dis* 2007; 9:740-4.
- Hyman N, Manchester TL, Osler T, Burns B, Cataldo PA. Anastomotic leaks after intestinal anastomosis: it's later than you think. *Ann Surg* 2007; 245:254-8.