

Multiple accessory structures in the upper limb of a single cadaver

Vollala V R, Nagabhooshana S, Bhat S M, Potu B K, Rakesh V

ABSTRACT

The arterial and muscular variations of the upper limbs are common but important with regard to surgical approaches. Even though anomalies of the coracobrachialis muscle are rare, anatomical variations of the biceps brachii, existence of the accessory muscles in the forearm and persistent median artery are known and well documented. During routine dissection, we observed some important anatomical variations in a 50-year-old male cadaver. The variations were unilateral. The anomalies were: third head for biceps brachii muscle, an accessory belly for coracobrachialis muscle crossing the median nerve and brachial vessels and continuing with the medial head of triceps brachii muscle to be inserted to the olecranon process (coracoulnaris), a persistent median artery and an additional muscle in the anterior compartment of forearm. Although there are individual reports about these variations, the combination of these variations in one cadaver has not previously been described in the literature. Awareness of these variations is necessary to avoid complications during radiodiagnostic procedures or surgeries in the upper limb.

Keywords: anatomical variants, biceps brachii, coracobrachialis, coracoulnaris, median artery

Singapore Med J 2008; 49(9):e254-e258

INTRODUCTION

The classical description of attachments of the biceps brachii muscle include: the short head arising from the tip of the coracoid process of the scapula and the long head arising from the supraglenoid tubercle of the scapula and from the glenoidal labrum. Distally, the two bellies unite to form a common tendon which is inserted into the posterior rough part of the radial tuberosity and through the bicipital aponeurosis to the subcutaneous posterior border of ulna. It is one of the most variable muscles in the human body, in

terms of the number and morphology of its heads.⁽¹⁻⁴⁾ This muscle frequently has more than two heads arising from the humerus at the insertion of the coracobrachialis or the neck of the humerus. There are reports describing supernumerary bicipital heads, ranging from three to seven. Among them, the three-headed variant represents the most common type that has been reported with a prevalence ranging from 7.5%–18.3%.^(2,5-8)

Normally, the coracobrachialis muscle arises from the tip of the coracoid process of the scapula in common with the short head of the biceps brachii muscle and inserts into the middle of the anteromedial surface of the shaft of the humerus. The reported morphological variations of the coracobrachialis muscle include accessory slips inserting to the medial epicondyle of the humerus, medial supracondylar ridge, medial intermuscular septum, the lesser tubercle and a supernumerary head passing over the shoulder joint.⁽⁹⁻¹¹⁾ The presence of accessory muscles in the forearm was reported back in 1813 by Gantzer, and from then on, these muscles have been reported with variable attachments.⁽¹²⁻²¹⁾ The accessory heads of the deep flexors of the forearm (Gantzer's muscles) have been described as small bellies inserting either into the flexor pollicis longus (FPL) or flexor digitorum profundus (FDP). The median artery is a transitory vessel that represents the arterial axis of the forearm during early embryonic life. It normally regresses in the second embryonic month to become the small slender artery, arteria comitans nervi mediani.⁽²²⁾ Persistence of the median artery is not uncommon, and its incidence is reported as ranging between 1.5% and 27.1%.⁽²³⁻²⁵⁾

CASE REPORT

The study involved the upper limb dissections of a 50-year-old male cadaver. The dissections of both upper extremities (right and left) of the body were carried out according to the instructions by Cunningham's Manual of Practical Anatomy.⁽²⁶⁾ The body was preserved by the injection of a formalin-based preservative (10% formalin) and stored at -4°C. Before taking photographs, the dissected region was rinsed with water. The third head of biceps brachii muscle, accessory

Department of
Anatomy,
Melaka Manipal
Medical College,
Manipal University,
Manipal 576104,
Karnataka,
India

Vollala VR, MSc
Lecturer

Nagabhooshana S,
MSc, PhD
Professor

Bhat SM, MSc
Associate Professor

Department of
Anatomy,
Kasturba Medical
College,
Manipal University,
Manipal 576104,
Karnataka,
India

Potu BK, MSc
Lecturer

Rakesh V, MSc
Lecturer

Correspondence to:
Dr Venkata Ramana
Vollala
Tel: (91) 820 292 2642
Fax: (91) 820 257 1905
Email: ramana.anat@
gmail.com

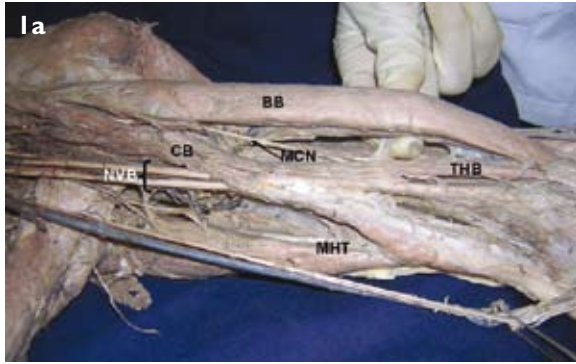


Fig. 1a Photograph of the anterior compartment of the left arm shows the third head of biceps brachii and accessory belly of coracobrachialis crossing the median nerve and brachial vessels.
BB: biceps brachii; THB: third head of biceps brachii; CB: coracobrachialis; MHT: medial head of triceps brachii; NVB: neurovascular bundle (median nerve, ulnar nerve and brachial vessels); MCN: musculocutaneous nerve

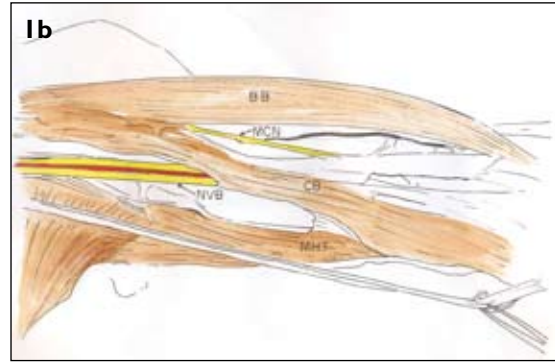


Fig. 1b Schematic diagram of the anterior compartment of the left arm.
BB: biceps brachii; CB: coracobrachialis; MHT: medial head of triceps brachii; NVB: neurovascular bundle (median nerve, ulnar nerve and brachial vessels); MCN: musculocutaneous nerve

belly of coracobrachialis muscle crossing the median nerve and brachial vessels, a persistent median artery and an additional muscle in the anterior compartment of forearm were found in the left upper limb. However, the right upper limb showed no abnormality.

The accessory head of the biceps brachii muscle arose from the shaft of the humerus between the insertion of the coracobrachialis muscle and origin of the brachialis muscle. The additional muscle fibres formed a narrow tendon which inserted into the medial aspect of the tendon of the biceps brachii muscle to be inserted to the radial tuberosity (Fig. 1a). In the same arm, we also found an anomalous coracobrachialis muscle. The origin of coracobrachialis was normal from the tip of the coracoid process along with the short head of biceps brachii, but the muscle fibres divided into superficial and deep bellies. The deep fibres inserted to the medial surface of the middle of the shaft of the humerus, deep to the neurovascular bundle of the anterior compartment of the arm. The superficial fibres crossed the median nerve, ulnar nerve, brachial vessels and continued with the medial head of triceps brachii muscle to be inserted to the olecranon process (Figs. 1a & b), forming the potential site for entrapment or compression of the neurovascular bundle. A review of the literature suggests that the occurrence of this variation is very rare globally. The nerve supply to the third head of biceps brachii and coracobrachialis muscle was from the musculocutaneous nerve.

There was an additional muscle in the anterior compartment of the forearm. It was seen deep to the flexor digitorum superficialis (FDS) and took origin from the undersurface of the FDS distal to its origin from the medial epicondyle of humerus. The muscle belly ended in a long tendon in the middle part of the forearm and the tendon merged with the tendon of FDP

for the middle finger (Fig. 2). The following are the approximate sizes of the muscle: muscle length 7 cm, tendon length 15 cm, muscle width 0.8 cm, and tendon width 0.3 cm. The additional muscle belly was anterior to both the anterior interosseous nerve and vessels, and the ulnar artery. The nerve and arterial supply to the muscle came from the anterior interosseous nerve and ulnar artery, respectively. There was persistent median artery taking origin from the anterior interosseous artery and accompanied the lateral aspect of the median nerve up to the wrist (Fig 3). The artery gave muscular branches to the nearby muscles.

DISCUSSION

Although the third head of biceps brachii is a common occurrence in mammals,⁽²⁷⁻²⁹⁾ previous studies in human beings show that the third head of biceps brachii is seen in about 8% of Chinese,⁽³⁾ 10% of white Europeans,^(3,30) 12% of black Africans,⁽³⁾ 18% of Japanese,⁽³⁾ 20.5% of South African blacks, 8.3% of South African whites,⁽⁵⁾ 20% of Brazilian whites, 9% of Brazilian blacks,⁽²⁾ 15% of Turks,⁽⁶⁾ and merely 2% in the Indian population.⁽³¹⁾ Thus, the occurrence of third head of biceps brachii in the Indian population is rare. According to Rodriguez-Niedenfuhr et al, the accessory bicipital head in the present case corresponds to the inferomedial type.⁽⁷⁾ Based on its origin, it may be considered as a remnant of the long head of coracobrachialis muscle, an ancestral hominoid muscle.^(32,33) The third head of biceps brachii in our case originated from the anteromedial surface of the humerus distal to the insertion of the coracobrachialis, passed inferomedial to the main biceps brachii and anterior to the brachialis muscle, and inserted into the medial side of the common biceps tendon. The medial humeral origin of the third head may provide additional




Fig. 2 Anterior photograph of the left forearm. The accessory head (Gantzer muscle) of the flexor digitorum profundus arises from under the surface of the flexor digitorum superficialis and inserts into the tendon for the middle finger of flexor digitorum profundus.

FDP: flexor digitorum profundus; Ah of FDP: additional head of flexor digitorum profundus; FDS: flexor digitorum superficialis, *****: tendon of additional head of flexor digitorum profundus.

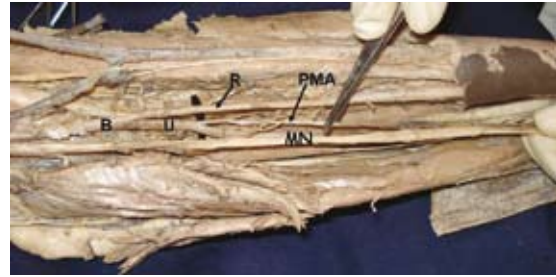

Fig. 3 Photograph shows the persistent median artery. B: brachial artery; U: ulnar artery; R: radial artery; PMA: persistent median artery; MN: median nerve.

strength to the biceps during supination of the forearm and elbow flexion irrespective of shoulder position.⁽³⁴⁾ The presence of the third head may cause unusual bone displacement, subsequent to fracture; such variations have relevance in surgical procedures.

In the present case, the accessory fibres of the coracobrachialis muscle crossed the neurovascular bundle of the anterior compartment of the arm and continued with the medial head of triceps to be inserted to the olecranon process of ulna. There are only two reports in the literature similar to our finding,^(3,35) but they have not given any specific name to this additional belly extending towards the ulna through the triceps brachii. This can be aptly called “coracoularis”. The “coracoularis” muscle can help in the extension of the elbow and pronation of the forearm. The presence of the additional fibres of the coracobrachialis muscle reported in this case may be explained on the basis of the embryogenesis of the muscles of the arm. During development, the limb bud mesenchyme of the lateral plate differentiates into intrinsic muscles of the upper limb. A single muscle mass is formed by fusion of the muscle primordia within the different layers of the arm at a certain stage of development;⁽³⁶⁾ thereafter, some muscle primordia disappear through cell death.⁽³⁷⁾ Failure of the muscle primordia to disappear during embryologic development may have resulted in the present anomalous coracobrachialis muscle.

An important finding in our case is a passageway for the brachial artery and median nerve formed by the additional fibres of the coracobrachialis muscle. Other openings, however, have been described for the passage of the median nerve and brachial artery,⁽³⁸⁾ the most common being the tunnel formed beneath the ligament of Struthers.⁽³⁹⁾ Due to abnormal crossing of muscle belly over the neurovascular bundle of this region of the arm, the median nerve and brachial artery may undergo active or passive compression leading to neurovascular disorders. Even though we

did not find any such reported clinical cases, this kind of neurovascular disorders may be similar to the cases of entrapment by ligament of Struthers. The present variation adds to the complexity of the coracobrachialis muscle and suggests that the possibility of an abnormal insertion of the coracobrachialis muscle should be considered in a patient with a high median nerve palsy and low brachial artery compression. It may lead to wasting or ischaemic contraction of flexors of the forearm. This variation is important to note during the active use of coracobrachialis as a transposition flap in deformities of infraclavicular and axillary areas and in postmastectomy reconstruction;⁽⁴⁰⁾ during surgical intervention of the anterior compartment of the arm, such as trauma, tumour, neurovascular disease; while using conjoint tendon for stabilisation treatment for recurrent dislocation and subluxation of the shoulder joint;⁽⁴¹⁾ while using coracobrachialis as a vascularised muscle for transfer for the treatment of longstanding facial paralysis;⁽⁴²⁾ during evaluation of computed tomography (CT) and magnetic resonance (MR) imaging. As the coracobrachialis is also a guide to the axillary artery during surgery and anaesthesia, knowledge of this abnormal insertion may prove significant.

The additional muscle of the forearm seen in the current case arose from the undersurface of FDS and inserted into tendon of FDP for the middle finger. Through the accessory slip, the FDS can have its additional action on the terminal phalanx of the middle finger. The insertion of the accessory head of the FDP into the main muscle has been described via one, two or three slips in nine different possible combinations,⁽¹³⁾ among them to the tendon of the middle finger,^(12,21) as in our case. Previous studies show the incidence of the accessory head of FDP to range from 2.9% to 35.2%.^(17,19) These accessory muscles have been observed to arise from the coronoid process, the medial epicondyle via fibres of the FDS, or a combination

of the two.^(12,13,16-19,43) Even though this variation is interesting anatomically, the accessory head of FDP can restrict its movements, resulting in burning pain in the lower third of the forearm via a muscle-tendon shearing action.⁽⁴⁴⁾ The accessory heads of the flexor muscles have been described in primates and other mammals (pigs, foxes and marmots) as a muscle belly that connects the medial epicondyle origin of the FDS with the more or less differentiated deep flexor muscles.⁽⁴⁵⁾ The flexor muscles of the forearm develop from the flexor mass which subsequently divides into two layers, superficial and deep. The deep layer gives rise to the FDS, FDP and FPL.⁽⁴⁶⁾ The existence of accessory muscles which connect the flexor muscles could be explained by the incomplete cleavage of the flexor mass during development.

Accessory muscles in the arm and forearm may lead to confusion during surgical procedures or cause compression of neurovascular structures. To avoid clinical complications, during radiodiagnostic procedures (e.g. CT, MR imaging) or surgical approach of these regions, awareness of such variations must be borne in mind. These types of variations are interesting not only to anatomists, but also to orthopaedic surgeons, physiotherapists and radiologists. Persistent median arteries vary in their mode of origin and have been described as arising from the ulnar, interosseous, radial or brachial arteries.⁽²⁵⁾ The median artery may persist in adult life in two different patterns, palmar and antebrachial, based on their vascular territory. The palmar type, which represents the embryologic pattern, is large, long and reaches the palm. The antebrachial type, which represents a partial regression of the embryonic artery is slender, short, and terminates before reaching wrist.⁽⁴⁷⁾

In the present report, the median artery, which is the antebrachial type, arose from the anterior interosseous artery and descended to the wrist on the superficial aspect of FPL and deep to FDS accompanying the lateral side of the median nerve and terminated as a very thin branch in the median nerve sheath. Since the median artery is reportedly conserved in domestic mammals and is the usual condition in lower tetrapods,^(48,49) its persistence in the adult human represents a retention of the primitive arterial pattern. Presence of an additional belly for coracobrachialis muscle, third head of biceps brachii muscle, accessory head of FDP (Gantzer's muscle) and a persistent median artery in a single cadaver is a rare combination. Though there are individual reports about these variations, the combination of these variations in one cadaver has not previously been described in the literature.

REFERENCES

1. Kosugi K, Shibata S, Yamashita H. Supernumerary head of biceps brachii and branching pattern of the musculocutaneous nerve in Japanese. *Surg Radiol Anat* 1992; 14:175-85.
2. Neto HS, Camilli JA, Andrade JCT, Filho JM, Marques MJ. On the incidence of the biceps brachii third head in Brazilian whites and blacks. *Ann Anat* 1998; 180:69-71.
3. Bergman RA, Thompson SA, Afifi AK, Saadeh FA. *Compendium of Human Anatomic Variations*. Baltimore: Urban & Schwarzenberg, 1988: 10-2.
4. Nakatani T, Tanaka S, Mizukami S. Absence of the musculocutaneous nerve with innervation of coracobrachialis, biceps brachii, brachialis and the lateral border of the forearm by branches from the lateral cord of the brachial plexus. *J Anat* 1997; 191:459-60.
5. Asvat R, Candler P, Sarmiento EE. High incidence of the third head of biceps brachii in South African populations. *J Anat* 1993; 182:101-4.
6. Kopuz C, Sancak B, Ozbenli S. On the incidence of third head of biceps brachii in Turkish neonates and adults. *Kaibogaku Zasshi* 1999; 74:301-5.
7. Rodriguez-Niedenfuhr M, Vazquez T, Choi D, Parkin I, Sanudo JR. Supernumerary humeral heads of the biceps brachii muscle revisited. *Clin Anat* 2003; 16:197-203.
8. Abu-Hijleh MF. Three-headed biceps brachii muscle associated with duplicated musculocutaneous nerve. *Clin Anat* 2005; 18:376-9.
9. Wood J. On human muscular variations and their relation to comparative anatomy. *J Anat Physiol* 1867; 1:44-59.
10. Howell AB, Straus, WL. The brachial flexor muscles in primates. *Proc US Natl Museum* 1932; 80:1-31.
11. Böhnel P. [Variant of the coracobrachialis muscle (accessory origin from the shoulder joint capsule)]. *Handchirurgie* 1979; 11:119-20. German.
12. Wood J. Variations in human myology observed during the winter session of 1867-68 at King's College, London. *Proc R Soc Lond* 1868; 16:483-525.
13. Macalister A. Additional observations on muscular anomalies in human anatomy (3rd series), with the catalogue of principal muscular variation hitherto published. *Trans R Ir Acad* 1875; 25:1-130.
14. Turner W. Notes on the dissection of a second Negro. *J Anat Physiol* 1880; 14(Pt 2):244-8.
15. Schäfer EA, Thane GD, eds. *Quain's Elements of Anatomy*. Vol 2, Part 2. London: Longmans, 1884: 227-8.
16. Dykes J, Anson BJ. The accessory tendon of the flexor pollicis longus muscle. *Anat Rec* 1944; 90:83-9.
17. Mangini U. Flexor pollicis longus muscle: its morphology and clinical significance. *J Bone Joint Surg Am* 1960; 42A:467-70.
18. Malhotra VK, Sing NP, Tewari SP. The accessory head of the flexor pollicis longus muscle and its nerve supply. *Anat Anz* 1982; 151:503-5.
19. Kida M. [The morphology of Gantzer's muscle with specific reference to morphogenesis of the flexor digitorum superficialis]. *Kaibogaku Zasshi* 1988; 63:539-46. Japanese.
20. Tountas CH, Bergman R. *Anatomic Variations of the Upper Extremity*. New York: Churchill Livingstone, 1993: 147-56.
21. Jones M, Abrahams PH. Case report: accessory head of the deep forearm flexors. *J Anat* 1997; 191:313-14.
22. Singer E. Embryological pattern persisting in the arteries of the arm. *Anat Rec* 1933; 55: 403-9.
23. McCormack LJ, Cauldwell EW, Anson BJ. Brachial and antebrachial arterial patterns: a study of 750 extremities. *Surg Gynecol Obstet* 1953; 96:43-54.
24. Srivastava SK, Pande BS. Anomalous pattern of median artery in the forearm of Indians. *Acta Anat* 1990; 138:193-4.
25. Henneberg M, George BJ. High incidence of the median artery of the forearm in a sample of recent Southern African cadavers. *J Anat* 1992; 180:185-8.

26. Romanes GJ. Upper and lower limbs. In: Cunningham's Manual of Practical Anatomy. 15th ed. Vol 1. New York: Oxford University Press, 1993; 67-8, 74-6.
27. Dobson GE. Notes on the anatomy of cercopithecus callithichus. Proc Zool Soc Lond 1881; 812-8.
28. Primrose A. The anatomy of orang-outang (*Simia satyrus*). Trans R Soc Can Inst 1899; 6:507-98.
29. Sonntag CF. On the anatomy, physiology and pathology of the chimpanzee. Proc Zool Soc Lond 1923; 24:349-449.
30. Gray H. Anatomy of the Human Body. 29th Am ed. Philadelphia: Lea and Febiger, 1973: 488-99.
31. Soubhagya R, Nayak, Latha V, Prabhu, Sivanandan R. Third head of biceps brachii: a rare occurrence in the Indian population. Ann Anat 2006; 188:159-61.
32. Sonntag CF. On the anatomy, physiology and pathology of the chimpanzee. Proc Zool Soc 1923; 22:323-63.
33. Sonntag CF. On the anatomy, physiology and pathology of the orang-utan. Proc Zool Soc 1924; 24:349-80.
34. Swieter MG, Carmichael SW. Bilateral three headed biceps brachii muscle. Anat Anz 1980; 148:346-9.
35. El-Naggar MM, Zahir FI. Two bellies of the coracobrachialis muscle associated with a third head of the biceps brachii muscle. Clin Anat 2001; 14:379-82.
36. Cihak R. Ontogenesis of the skeleton and intrinsic muscles of the human hand and foot. Ergeb Anat Entwicklungsgesch 1972; 46:5-194.
37. Grim M. Ultrastructure of the ulnar portion of the contrahent muscle layer in the embryonic human hand. Folia Morphol (Praha) 1972; 20:113-5.
38. Mustafa El-Naggar, Al-Saggaf Samar. Variation of the coracobrachialis muscle with a tunnel for the median nerve and brachial artery. Clin Anat 2004; 17:139-43.
39. Struthers J. On some points in the abnormal anatomy of the arm. Br Foreign Med Chir Rev 1854; 14:224-36.
40. Kopuz C, İçten N, Yildirim M. A rare accessory coracobrachialis muscle: a review of the literature. Surg Radiol Anat 2003; 24: 406-10.
41. Jiang LS, Cui YM, Zhou ZD, Dai LY. Stabilizing effect of the transferred conjoined tendon on shoulder stability. Knee Surg Sports Traumatol Arthrosc 2007; 15:800-5.
42. Taylor GI, Cichowitz A, Ang SG, Seneviratne S, Ashton M. Comparative anatomical study of the gracilis and coracobrachialis muscles: implications for facial reanimation. Plast Reconstr Surg 2003; 112: 20-30.
43. Martin BF. The oblique cord of the forearm. J Anat 1958; 92:609-15.
44. Ryu J, Watson HK. SSMB syndrome. Symptomatic supernumerary muscle belly syndrome. Clin Orthop Relat Res 1987; 216:195-202.
45. Parsons FG. The muscles of mammals with special relation to human myology. J Anat 1898; 32:721-52.
46. Lewis WH. The development of the muscular system. In: Keibel F, Mall FP, ed. Manual of Embryology. Vol 2. Philadelphia: JB Lippincott, 1910: 455-522.
47. Rodriguez-Niedenfuhr M, Sanudo JR, Vazquez T, et al. Median artery revisited. J Anat 1999; 195:57-63.
48. O'donoghue CH. The blood vascular system of the Tuatara, *Sphenodon punctatus*. Philos Trans R Soc Lond 1920; B210:75-252.
49. Francis ET. The Anatomy of the Salamander. Oxford: Clarendon Press, 1934: 381.