

Anatomical variations of the thyroid gland: possible surgical implications

Ranade A V, Rai R, Pai M M, Nayak S R, Prakash, Krisnamurthy A, Narayana S

ABSTRACT

Introduction: The organogenesis of the thyroid gland in humans is often disturbed, leading to a variety of morphological variations of the gland, such as hypoplasia, ectopy, hemiagenesis and agenesis. As the morphological variations are usually diagnosed incidentally during examination for other thyroid gland diseases, the true incidence is therefore uncertain.

Methods: This study was structured to investigate the gross anatomical features of the thyroid gland in 105 (88 male and 17 female) cadavers from the coastal belt of southern India, an endemic goitre region.

Results: The pyramidal lobe was present in 61 (58 percent) male cadavers, and 52 (49.5 percent) cadavers showed the presence of the levator glandulae thyroideae. 33 percent of the specimens studied showed agenesis of the isthmus. However, the accessory thyroid tissue was found in only one cadaver.

Conclusion: This study highlights the various developmental anomalies of the thyroid gland, which forms a cornerstone to safe and effective surgery.

Keywords: accessory thyroid tissue, anatomical variations, ectopic thyroid tissue, levator glandulae thyroideae, pyramidal lobe

Singapore Med J 2008;49(9):831-834

INTRODUCTION

The anomalies of the development of the thyroid gland distort the morphology of the gland, and may cause clinical functional disorders and various thyroid illnesses.⁽¹⁻³⁾ The thyroid gland lies deep to the sternothyroid and sternohyoid muscles, located anteriorly in the neck at the level of the C5–T1 vertebrae.⁽⁴⁾ Accessory nodules/ectopic thyroid tissue of the thyroid are usually found at the embryonic origin of thyroid gland, at the foramen caecum, or on the lingual duct and thyroglossal tract within the tongue.⁽⁵⁾ These accessory nodules/ectopic thyroid tissue of the thyroid may also be seen at various other sites of body, such as the anterior mediastinum,⁽⁶⁾ heart,⁽⁷⁾ lung,⁽⁸⁾ submandibular region,⁽⁹⁾ trachea,⁽¹⁰⁾ duodenum⁽¹¹⁾ and

Table I. The number of male and female cadavers with gross anatomical features.

	Male cadavers	Female cadavers
Pyramidal lobe	61	Absent
LGT	50	2
AI	27	8
ATT + AI	1	Absent
Pyramidal lobe + LGT	23	Absent

LGT: levator glandulae thyroideae; AI: absence of isthmus; ATT: accessory thyroid tissue

adrenal gland.⁽¹²⁾ These ectopic thyroid tissues may later undergo malignant changes.^(6,10) Approximately 50 percent of thyroid glands have a pyramidal lobe. This lobe, which varies in size, extends superiorly from the isthmus of the thyroid gland, usually to the left of the median plane. The isthmus may be incomplete.⁽⁴⁾ A band of connective tissue may continue from the apex of the pyramidal lobe to the hyoid. The pyramidal lobe and the band develop from remnants of the epithelium and connective tissue of the thyroglossal duct.⁽⁴⁾ The purpose of this study was to highlight various developmental anomalies of the thyroid gland, thereby forming a cornerstone to safe and effective surgery.

METHODS

Dissections were performed on the head and neck region of 105 cadavers of both genders (88 male and 17 female). The thyroid gland was exposed and studied for any variations and developmental anomalies, including partial and total agenesis of the gland, presence of ectopic tissues or accessory thyroids, and permanent thyroglossal duct anomalies such as cysts, fistulae, or sinuses, and pyramidal lobes or fibrous bands.

RESULTS

The gross anatomical features observed in the present study (Table I) are summarised below:

1. Presence of pyramidal lobe in 61 (58%) male cadavers (Fig. 1). The pyramidal lobe was absent in female cadavers
2. Presence of levator glandulae thyroideae in 52 (49.5%) cadavers. Among them only two (12%) female cadavers showed the presence of levator glandulae thyroideae (Fig. 2).

Department of Anatomy, Kasturba Medical College, Mangalore, Karnataka 575004, India

Ranade AV, PhD
Assistant Professor

Rai R, MSc
Senior Lecturer

Pai MM, MD
Associate Professor

Nayak SR, MSc
Lecturer

Krisnamurthy A, MD
Assistant Professor

Vydehi Institute of Medical Sciences and Research Centre, Bangalore 560066, India

Prakash, MD
Assistant Professor

Department of Pediatrics, A J Institute of Medical Sciences, Mangalore 575004, Karnataka, India

Narayana S, MBBS
Tutor

Correspondence to:
Dr Anu V Ranade
Tel: (91) 824 222 2768
Fax: (91) 824 242 8183
Email: anuranade@yahoo.co.in

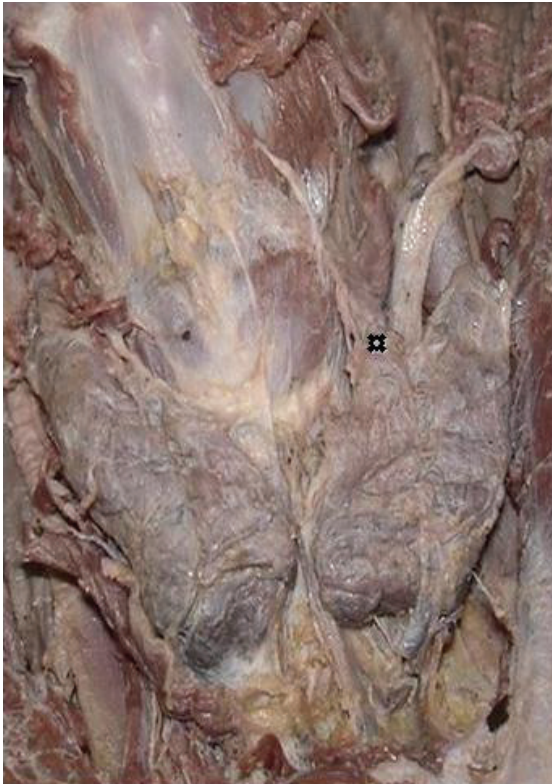

Fig. 1 Photograph taken at the front of the neck shows the pyramidal lobe of the thyroid gland (✱).

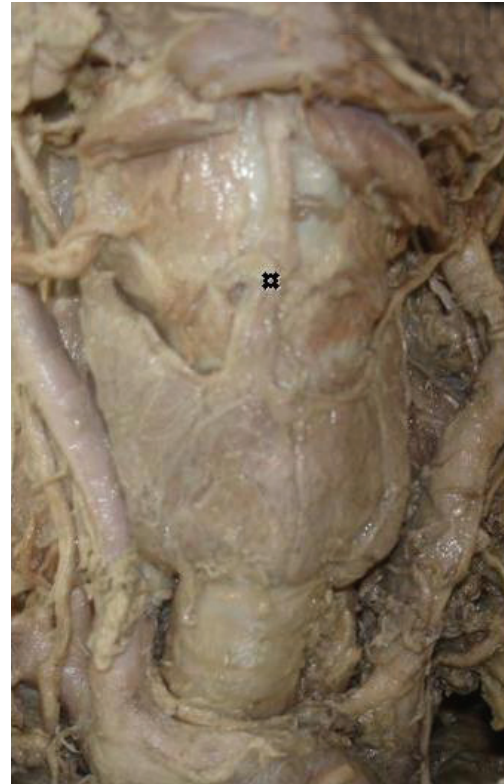


Fig. 2 Photograph taken at the front of the neck shows the levator glandulae thyroideae (✱).

3. Absence of isthmus in 35 (33%) cadavers, of which eight were female cadavers (Fig. 3).
4. In one case, accessory thyroid tissue was found above the cricoid cartilage as a separate mass supplied by the branch of superior thyroid artery (Fig. 4).

DISCUSSION

Most of the variations of the thyroid gland are due to a partial persistence of the median or thyroglossal duct.⁽¹³⁾ Failure of the development of the entire gland, or part of the gland, results in agenesis or hemiagenesis, which may be unilateral or isthmic.^(14,15) Many workers claim that the absence of isthmus is quite rare in humans,^(3,16) and in adult animals, the isthmus is either present or absent. According to the studies by Braun et al, the isthmus was missing in four cases of the 58 cadavers they studied.⁽¹⁷⁾ Won and Chung have reported that in 3% of the cases studied, the isthmus was absent and the lateral lobes of the thyroid were separated.⁽¹⁸⁾ Nehtap et al observed failure of fusion of isthmus in the midline of the thyroid gland in a 48-year-old female cadaver.⁽¹⁹⁾ According to Gruber (quoted by Testut and Latajet), the incidence of agenesis of the thyroid isthmus is about 5%,⁽²⁰⁾ while according to Marshall, it is about 10%.⁽²¹⁾ The absence of an isthmus can be associated with other types of dysorganogenesis, such as the absence of a lobe or the presence of ectopic thyroid tissue.⁽²²⁾ When

the absence of isthmus is observed, a differential diagnosis against the following pathologies should be carried out: (a) autonomous thyroid nodule; (b) thyroiditis; (c) primary carcinoma; (d) neoplastic metastases; and (e) infiltrative diseases such as amyloidosis.⁽²³⁾

The frequency of the presence of pyramidal lobes could be a source of pitfalls in thyroidectomy during preoperative diagnosis on scintigraphical images.⁽¹⁷⁾ A pyramidal lobe was found to be present in 55% (32/58) of the cadavers studied by Braun et al.⁽¹⁷⁾ According to them, it was found more frequently in men than in women. In a study performed to clarify the morphological characteristics of the thyroid glands in Koreans, the frequency of the existence of the pyramidal lobe was 76.8 percent.⁽¹⁸⁾

An accessory thyroid gland was present in one specimen among 58 cadavers studied by Braun et al.⁽¹⁷⁾ Ectopic thyroid may cause hypothyroidism.^(2,3) Accessory thyroid gland at the carotid bifurcation may present as a carotid body tumour.⁽²⁴⁾ The possibility of the presence of ectopic thyroid tissue should be thought of, when magnetic resonance imaging of a presumed carotid body tumour shows tumour characteristics, which are not completely specific for a carotid body tumour, because this ectopic tissue could be the patient's only properly functioning thyroid tissue.⁽²⁵⁾ Ectopic thyroid tissue may undergo malignant changes.^(6,10) An ectopic tissue in the

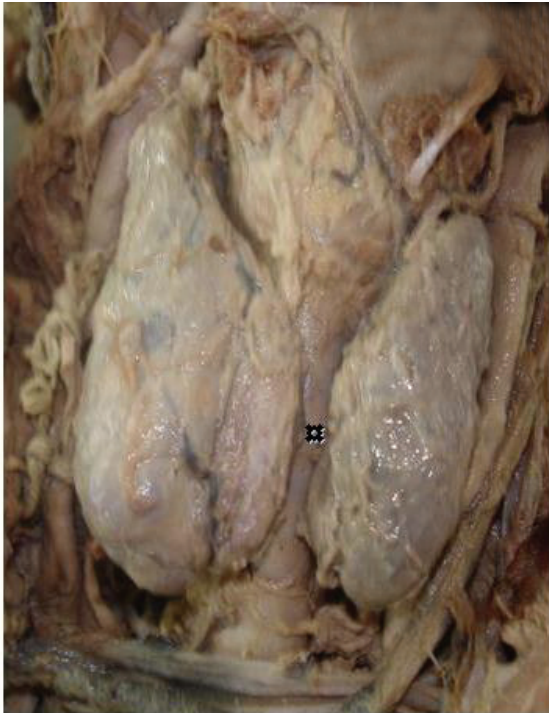

Fig. 3 Photograph taken at the front of the neck shows the absence of isthmus of the thyroid gland (✕).

parotid gland has been reported by Mysorekar et al, who explained that the ectopic thyroid tissue in the parotid gland could be due to a common evolution of the thyroid and parathyroid glands.⁽²⁵⁾ The presence of thyroid tissue within the tracheal lumen is an unusual cause of upper respiratory obstruction. Thyroid tissue in this location may be a true ectopic tissue or may be caused by the invasion of the trachea by a malignant process.⁽²⁶⁾

According to Gregory and Guse, Soemmerring's levator glandulae thyroideae is an accessory muscle which runs from the hyoid bone to insert partly on the thyroid cartilage and partly on the isthmus of the thyroid gland.⁽²⁷⁾ Merkel thought that the levator glandulae was constant and glandular though usually surrounded by muscle fibres.⁽²⁸⁾ Huschke spoke of the structure only as glandular, mentioning nothing about the muscle.⁽²⁹⁾ Bourguery described and illustrated a muscle, which he called "hyo-thyroidien", occupying the place of the pyramidal lobe.⁽³⁰⁾ Finally, Godart reported a case in which the structure was indeed muscular, on the basis of the nitric acid test for muscle.⁽³¹⁾ Soemmerring's muscle is the same as the hyo-thyro-glandulaire of Pointe, the levator glandulae thyroideae superficialis medius et longus of Krause,⁽³²⁾ and the musculus thyroideus of Merkel; its usual full name in the literature is levator glandulae thyroideae of Soemmerring. Saadeh et al reported an unusual levator glandulae thyroideae on the left side of the neck in a female cadaver. It arose from the mastoid process, extended superficially to the superior belly of the

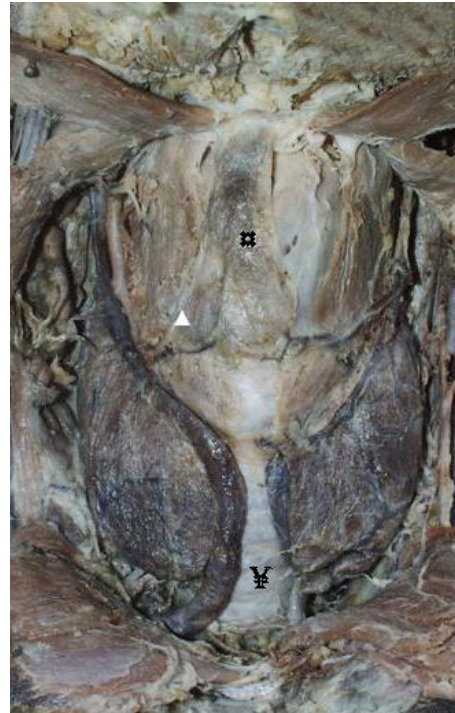

Fig. 4 Photograph taken at the front of the neck shows the ectopic thyroid tissue (□), absence of isthmus of the thyroid gland (✕), and the arterial supply to the ectopic tissue (▲).

omohyoid muscle and inserted into the connective tissue of the left lobe of the thyroid gland.⁽³³⁾

Reports in the literature suggest that chromosome 22 could play a role in the thyroid development.⁽³⁴⁾ The surgeon planning a thyroidectomy must be prepared to find variations in two important structures in the neck. He must be prepared to find ectopic thyroid nodules around the normally-located thyroid gland. Any unattached nodule should be considered malignant until proven otherwise.⁽³⁵⁾ Therefore, the anterior cervical region has to be investigated very carefully during an operation, in order not to leave behind residual thyroid tissue during total thyroidectomy.⁽¹⁷⁾ Knowledge of vascular aberrations is essential in routine surgical procedure. Proper identification of these vessels, as in one of our findings (Fig. 4), is very important in order to avoid major complications, especially during head and neck surgery. Therefore, through training and understanding of the thyroid anatomy and its associated anatomical variations are very much essential, so that these anomalies are not overlooked in the differential diagnosis.

REFERENCES

1. Arriaga MA, Myers EN. Ectopic thyroid in the retro esophageal superior mediastinum. *Otolaryngol Head Neck Surg* 1988; 99:338-40.
2. Baldwin RL, Copeland SK. Lingual thyroid and associated epilogist. *South Med J* 1988; 81:1538-41.
3. Larochelle D, Arcand P, Belzile M, Gagnon NB. Ectopic thyroid tissue - A review of the literature. *J Otolaryngol* 1979; 8:523-30.
4. Moore KL, Dalley AF. *Clinically Oriented Anatomy*. 5th ed.

- Philadelphia: Lippincott Williams and Wilkins, 2006: 1083-5.
5. Bergman RA, Afifi AK, Miyauchi R. Thyroid gland. In: Illustrated Encyclopedia of Human Anatomic Variation: Opus IV: Organ Systems: Endocrine System. Available at: www.anatomyatlases.org/AnatomicVariants/OrganSystem/Text/ThyroidGland.shtml. Accessed. August 12, 2007.
 6. Sand J, Pehkonen E, Mattila J, Seppanen S, Salmi J. Pulsating mass at the sternum: a primary carcinoma of ectopic mediastinal thyroid. *J Thorac Cardiovasc Surg* 1996; 112: 833-5.
 7. Casanova JB, Daly RC, Edwards BS, Tazelaar HD, Thompson GB. Intracardiac ectopic thyroid. *Ann Thorac Surg* 2000; 70:1694-6.
 8. Bando T, Genka K, Ishikawa K, Kuniyoshi M, Kuda T. Ectopic intrapulmonary thyroid. *Chest* 1993; 103:1278-9.
 9. Feller KU, Mavros A, Gaertner HJ. Ectopic submandibular thyroid tissue with a coexisting active and normally located thyroid gland: case report and review of literature. *Oral Surg Oral Med Oral Pathol Oral Radiol Endod* 2000; 90:618-23.
 10. Hari CK, Brown MJ, Thompson I. Tall cell variant of papillary carcinoma arising from ectopic thyroid tissue in the trachea. *J Laryngol Otol* 1999; 113:183-5.
 11. Takahashi T, Ishikura H, Kato H, Tanabe T, Yoshiki T. Ectopic thyroid follicles in the submucosa of the duodenum. *Virchows Arch A Pathol Anat Histopathol* 1991; 418:547-50.
 12. Shiraiishi T, Imai H, Fukutome K, Watanabe M, Yatani R. Ectopic thyroid in the adrenal gland. *Hum Pathol* 1999; 30:105-8.
 13. Melnick JC, Stemkowski PE. Thyroid hemi-agenesis (hockey stick sign): a review of the world literature and a report of four cases. *J Clin Endocrinol Metab* 1981; 52:247-51.
 14. Kaplaw EL, Shukla M, Hara H, Ito K. Developmental abnormalities of the thyroid. In: De Groot LJ, ed. *Endocrinology*. Philadelphia: Saunders, 1994: 893-9.
 15. Larsen W J. Development of the head and neck: In: Larsen WJ, ed. *Human Embryology*. New York: Churchill Livingstone, 1993: 335-9.
 16. Romanes GJ. *Cunningham's Textbook of Anatomy*. 12th ed. Oxford: Oxford University Press, 1981: 57-9, 286, 596-7.
 17. Braun E, Windisch G, Wolf G, Hausleitner L, Anderhuber F. The pyramidal lobe: clinical anatomy and its importance in thyroid surgery. *Surg Radiol Anat* 2007; 29:21-7.
 18. Won HS, Chung IH. Morphologic variations of the thyroid gland in Korean adults. *Korean J Phys Antropol* 2002; 15:119-25.
 19. Nehtap Y, Eser Y, Figen K. Failure of the isthmus lobe to fuse in the midline. *Clin Anat* 1995; 8:33-5.
 20. Testut L, Latarjet A. *Tratado de Anatomia Humana, Tomo IV*. 9th ed. Barcelona: Salvat Editores, 1978.
 21. Marshall CF. Variation in the form of the thyroid in man. *J Anat Physiol* 1895; 29: 234-9.
 22. Duh QI, Ciula TA, Clark OH. Primary parathyroid hyperplasia associated with thyroid hemiagenesis and agenesis of the isthmus. *Surg* 1994; 115:257-63.
 23. Pastor VJF, Gil VJA, De Paz Fernández FJ, Cachorro MB. Agenesis of the thyroid isthmus. *Eur J Anat* 2006; 10:83-4.
 24. Hollander EJ, Visser MJ, van Baalen JM. Accessory thyroid gland at carotid bifurcation presenting as a carotid body tumor: case report and review of the literature. *J Vasc Surg* 2004; 39:260-2.
 25. Mysorekar VV, Dandekar CP, Sreevathsa MR. Ectopic thyroid tissue in the parotid salivary gland. *Singapore Med J* 2004; 45:437-8.
 26. Donegan JO, Wood MD. Intratracheal thyroid - familial occurrence. *Laryngoscope* 1985; 95:6-8.
 27. Gregory JK, Guse DM. Unique variant of levator glandulae thyroideae musde. *Clin Anat* 2007; 20:966-7.
 28. Merkel FS. *Die Anatomie des Menschen mit Hinweisen auf die ärztliche Praxis, Abt. 3*. Wiesbaden: JF Bergman, 1913: 50. German.
 29. Huschke E. *Traité de splanchnologie et des organes des sens*. In: *Encyclopedie Anatomique*. Vol V. Paris: JB Bailliere, 1845: 274.
 30. Bourguery JM. *Traite complet d'anatomie de l'homme, comprenant la medecine operatoire, avec planches lithographiees d'apres nature par NH Jacob*. Atlas. Paris. C. [-A.] Delaunay 1831; Tome II: 90, 1836; Tome IV: 91. French.
 31. Godart J. *Muscle de la glande thyroide, muscle de Duvernoi, musculus levator glandulae thyroideae*. (Exemple du Soemmerring.) [Abstr.] *Bull Soc Anat Paris* 1847; 22:202-5. French.
 32. Krause W. *Handbuch der menschlichen Anatomie. Durchaus nach eigenen Untersuchungen, und mit besonderer Rücksicht auf das Bedürfnis der Studirenden, der praktischen Ärzte und Wundärzte und der Gerichtsärzte*. 3. ed. Bd 2. Hannover: Hahn'sche Buchhandlung, 1879: 427. German.
 33. Saadeh FA, Kawas SH, Haikal FA, Hawi JS. An unusual levator glandulae thyroideae: a case report and literature review. *J Anat Soc Ind* 1996; 45:125-8.
 34. Gangbo E, Lacombe D, Alberti EM, et al. Trisomy 22 with thyroid isthmus agenesis and absent gall bladder. *Genet Couns* 2004; 15:311-5.
 35. Gray SW, Skandalakis JE, Akin JT Jr. Embryological consideration of thyroid surgery: developmental anatomy of the thyroid, parathyroids and the recurrent laryngeal nerve. *Am Surg* 1976; 42:621-8.