

Experience with plaque excision and dermal grafting in the surgical treatment of Peyronie's disease

Goyal N K, Kumar A, Das S K, Pandey A K, Sharma G K, Trivedi S, Dwivedi U S, Singh P B

ABSTRACT

Introduction: Peyronie's disease is a common cause of sexual dysfunction. We assess the technique of plaque excision and dermal grafting for the treatment of Peyronie's disease.

Methods: A total of 11 patients, aged 38–55 years, were operated for Peyronie's disease. All patients had stable plaque on the dorsum or dorsolateral aspect of the penile shaft. All patients had penile curvature, nine (81.8 percent) had painful erections, six (54.5 percent) had penile pain and three (27.3 percent) had erectile dysfunction. All suffered difficulty in intercourse. We performed plaque excision and dermal grafting. Main outcome measures were relief of penile pain, relief of painful erection, performance of satisfactory coitus and straight penis while erection.

Results: All patients had relief of penile pain and painful erection. Nine (81.8 percent) patients had straight penis and had satisfactory coitus. Two (18.2 percent) patients suffered postoperative erectile dysfunction which was mild and responded to Sildenafil tabs.

Conclusion: Although experience with this technique is limited, the initial results are encouraging. We found this technique feasible with satisfactory results.

Keywords: dermal graft, penile disease, penis, Peyronie's disease, plaque excision

Singapore Med J 2008;49(10):805-808

INTRODUCTION

Peyronie's disease (PD) is characterised by an acquired plaque-inducing penile deformity.⁽¹⁾ It is a common cause of sexual dysfunction in middle-aged men. Over the years, various medical and surgical therapies have been attempted with a relative lack of efficacy. Surgical treatment is opted in PD after medical management has failed. There are three general categories of surgical options for PD, namely: tunical shortening, tunical lengthening or grafting, and penile prosthesis. The ultimate goal for treatment of PD is to obtain satisfactory erection for intercourse and to relieve penile pain. We present our experience with dermal grafting in the surgical treatment of PD.

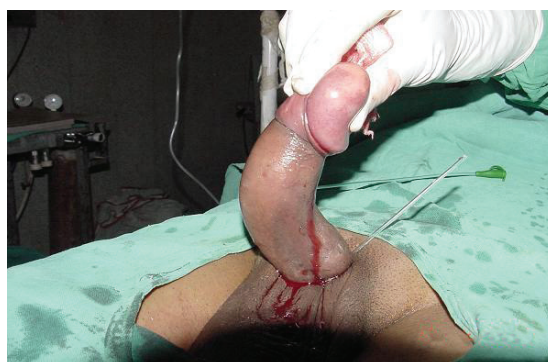

Fig. 1 Photograph shows severe dorsal chordee.

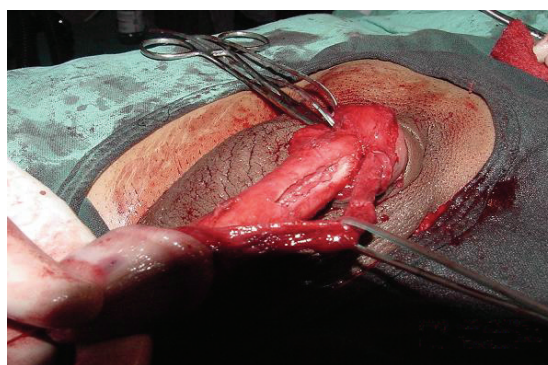


Fig. 2 Operative photograph shows plaque excision.

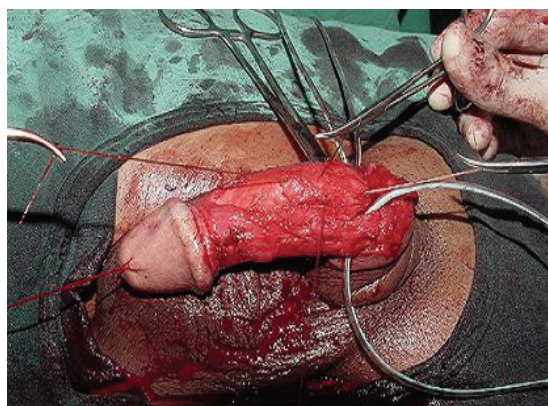


Fig. 3 Operative photograph shows dermal graft placement.

METHODS

This study is a retrospective analysis of 11 patients with PD treated with excision of plaque and dermal grafting from January 2001 to July 2007. The patients' profile and clinical features are listed in Table I. All patients had calcified plaques which were stable for at least one year. All had received medical treatment in the form of oral vitamin E (400 mg thrice a day), intralesional steroid (triamcinolone, 10 mg biweekly for 12 weeks) or intralesional interferon $\alpha 2b$ (3 million IU biweekly for

Department of
Urology,
Institute of Medical
Sciences,
Banaras Hindu
University,
Varanasi 221005,
India

Goyal NK, MS
Senior Resident

Kumar A, MS
Senior Resident

Das SK, MS
Senior Resident

Pandey AK, MS
Senior Resident

Sharma GK, MS
Senior Resident

Trivedi S, MCh
Lecturer

Dwivedi US, MCh
Reader

Singh PB, MCh
Professor

Correspondence to:
Prof Pratap Bahadur
Singh
Tel: (91) 983 961 0185
Fax: (91) 542 231 3200
Email: pburology@
gmail.com

Table I. Patients' characteristics.

Clinical variables	No. of patients
Total number	11
Mean age (range) (years)	42.5 (38–55)
Mean duration of symptoms (range) (months)	20.5 (14.5–34)*
Penile curvature (°)	
30–45	3
45–60	6
> 60	2
Plaque size (cm)	
< 2	3
2–4	7
> 4	1
Predominant location of the plaque	
Dorsal	5
Right lateral	3
Left lateral	2
Circumferential	1
Painful erections	9
Penile pain	6
Erectile dysfunction	
Mild	2
Moderate	1
Severe	0
Difficulty in intercourse	11
Preoperative treatment received	
Vitamin E	11
Intralesional steroids	4
Intralesional Interferon α 2b	3
Mean follow-up (range) (months)	9.5 (6.8–15)

12 weeks). To evaluate erectile dysfunction, we used the International Index of Erectile Function (IIEF) scoring (Table II) both in the preoperative and postoperative periods. We have been using Doppler ultrasonography to determine the vascular competence of the penis in patients with erectile dysfunction.

Preoperative counselling was conducted for all patients, and this included discussion of the patients' and partners' expectations, as well as potential risks and complications. The complications of the procedure, such as haematoma, penile and glans hypoesthesia, urethral injury and wound infection, were explained to the patients. All patients underwent the standard technique of plaque excision and dermal graft placement (Figs.1–3). We used a hairless area in the superolateral side of the iliac crest of the abdominal skin for obtaining the dermis. The dermal graft has the tendency to contract about 30%, so we ensured that the graft measured around 30%–40% larger in all directions than the corporotomy defect. Erections were encouraged after two weeks and intercourse was allowed after six weeks. Patients were followed-up for six months to two years.

RESULTS

Results are shown in the Table III. 81.8% were able to perform satisfactory intercourse. All patients were relieved of penile pain and painful erection. Postoperative complications were penile oedema, haematoma, wound infection and glans paraesthesia (Table III). Two patients

suffered erectile dysfunction in the postoperative period, of which one did not have erectile dysfunction before the surgery. Erectile dysfunction was mild in both cases and was successfully managed with Tab Sildenafil (50 mg half-an-hour before intercourse).

DISCUSSION

PD is a benign condition that is characterised by significant curvature of the penile shaft and accompanying area of fibrosis in the tunica vaginalis. This process most commonly occurs in middle-aged men. Symptoms may begin after an injury to the penis during sexual intercourse or from another trauma. The repeated injury to the penis during sexual intercourse leads to subtunical bleeding, and subsequently produces increased amounts of scar tissue.⁽²⁾ This scarring causes tethering of the penis, resulting in curvature, which may be minor to significant. Symptoms include a lump or area of scarring or plaque on the shaft of penis which may or may not be associated with pain and penile curvature during erection. Symptoms may worsen during intercourse. Patients may also suffer from decreased penile length and erectile difficulties, with complete erectile dysfunction or decreased duration of erection.

PD, while troublesome, is in no way related to sexually-transmitted disease, sexual practices, or cancer of the penis or other organs. Risk factors that may increase the possibility of PD include Paget's disease of the bone, rheumatoid arthritis, use of vacuum devices, penile infection, urological instrumentation or catheterisation. PD is often self-limiting, running its course over 12–18 months. During this time, the pain usually resolves spontaneously in 4–6 months, curvature may be moderate, and plaque size may diminish or soften. The course of disease can be variable, with up to 13% regressing spontaneously, 40% progressing if untreated, and 47% showing no change over time.⁽³⁾

Treatment of PD usually begins with medications in the hope to improve wound healing and soften the scar tissue associated with plaque. Various medications like vitamin E, colchicines, tamoxifen and steroids have been used. Clinical benefit, however, has not been demonstrated. Successful treatment of the plaque has been demonstrated with direct injection of medication like verapamil, steroids or alpha-interferon. If the medical treatment has failed, surgery may be an alternative for restoring coital ability. There are three general categories of surgical options for PD: tunical shortening, tunical lengthening/graft, and penile prosthesis. Plaque excision and dermal skin grafting technique for the treatment of PD was first popularised by Devine and Horton in 1974.⁽⁴⁾ Pitfall of this technique is the requirement of a second incision to harvest a dermal

Table II. IIEF-5 scoring system.

Over the past six months:	Score				
	1	2	3	4	5
How do you rate your confidence that you could get and keep an erection?	Very low	Low	Moderate	High	Very high
When you had erections with sexual stimulation, how often were your erections hard enough for penetration?	Almost never or never	Much less than half the time	About half the time	Much more than half the time	Almost always or always
During sexual intercourse, how often were you able to maintain your erection after you had penetrated (entered) your partner?	Almost never or never	Much less than half the time	About half the time	Much more than half the time	Almost always or always
During sexual intercourse, how difficult was it to maintain your erection to the completion of intercourse?	Extremely difficult	Very difficult	Difficult	Slightly difficult	Not difficult
When you attempted sexual intercourse, how often was it satisfactory for you?	Almost never or never	Much less than half the time	About half the time	Much more than half the time	Almost always or always

The IIEF-5 score is the sum of questions 1 to 5. The lowest score is 5 and the highest score 25. Erectile dysfunction: < 21; Mild: 17–21; Moderate: 8–16; Severe: 5–7

Table III. Postoperative results.

	No. of patients
Preoperative symptoms	
Penile curvature	9*
Painful erection	9*
Penile pain	6*
Satisfactory intercourse	9*
Postoperative complications	
Penile oedema	3
Haematoma	1
Wound infection	1
Glans paraesthesia	2
Erectile dysfunction	2

*showed improvement

Table IV. Comparison of the technique with the literature.

Study	No. of patients	Reduction in penis curvature (%)	Erectile dysfunction (%)	Satisfactory intercourse (%)
Devine and Horton ⁽⁴⁾	5	84 (straight)	0	53
Chun et al ⁽⁵⁾	15	73 (straight)	66.7	78.6
Backhause et al ⁽⁶⁾	20	65 (straight) 25 (5°–15°) 10 (30°–70°)	15	–
Nikoobakht et al ⁽⁷⁾	27	85 (straight)	16	88
Irani et al ⁽⁸⁾	18	100 (straight)	39	66
Kondas et al ⁽⁹⁾	16	100 (straight)	0	100
Hick et al ⁽¹⁰⁾	15	> 75 (straight)	0	> 75
Present study	11	81.8 (straight)	0	81.8

skin graft, which increases morbidity. Its advantage is that the patient does not need to pay for the extra cost of the graft, as with isografts or synthetic grafts. We compared our results with the literature (Table IV). Our results are comparable with other techniques using different graft materials, and some of the complications reported with other graft materials are not seen with the dermal graft (Table V). To date, the

follow-up results have been gratifying.

In conclusion, plaque excision and dermal grafting is a promising technique for surgical management of PD. In the Indian scenario, where the cost of treatment is a major factor in deciding the mode of treatment, this technique is very useful. We found this technique to be feasible, with satisfactory results.

Table V. Comparison with other graft materials.

Study	Graft	No. of patients	Straightness (%)	ED (%)	Satisfaction (%)	Complications (%)
Usta et al ⁽¹¹⁾	Cadaveric pericardium	19	79.9	–	73.7	–
Adenyi et al ⁽¹²⁾	Saphenous vein	51	82.4	7.8	61	Numerous
Sampaio et al ⁽¹³⁾	Duramater	40	95	15	–	2.5 partial foreskin necrosis (2.5) Decreased sensitivity of glans (22.6)
Egydio et al ⁽¹⁴⁾	Bovine pericardium	33	87.9	–	100	None listed
Knoll ⁽¹⁵⁾	Porcine SIS	12	91.1	8.3	–	–
Breyer et al ⁽¹⁶⁾	Porcine SIS	19	88	10	90	Recurrent penile curvature (37) Recurrent penile plaque (26) Haematoma at graft (26) Graft infection (5) Recurrent disease requiring placcation (5)
Licht and Lewis ⁽¹⁷⁾	PTFE	28	–	–	–	–
Shiohvilli and Kakonashvili ⁽¹⁸⁾	Buccal mucosal graft	26	92.3	–	–	Shortening of penis (7.7)
Montorsi et al ⁽¹⁹⁾	Vein patch	50	80	6	94	Penile shortening Penile hypoaesthesia Penile haematoma Wound infection Glandular ischaemia
Thiel et al ⁽²⁰⁾	Cadaveric pericardium	–	–	–	–	Inclusion cyst formation Graft contraction
Craatz et al ⁽²¹⁾	Dorsal lamina of rectus sheath	12	83.4	25	58.3	Prepuical oedema (41.7) Haematoma (16.6) Decrease in diameter of penis (25)

REFERENCES

- Tornehl CK, Carson CC. Surgical alternatives for treating Peyronie's disease. *BJU Int* 2004; 94:774-8.
- Devine CJ Jr, Somers KD, Jordan SG, Schlossberg SM. Proposal: trauma as cause of Peyronie's lesion. *J Urol* 1997; 157:285-90.
- Gelbard MK, Dorey F, James K. The natural history of Peyronie's disease. *J Urol* 1990; 144:1376-9.
- Devine CJ, Horton CE. The surgical treatment of Peyronie's disease with a dermal graft. *J Urol* 1974; 111:44-9.
- Chun JL, McGregor A, Krishnan R, Carson CC. A comparison of dermal and cadaveric pericardial grafts in the modified Horton-Devine procedure for Peyronie's disease. *J Urol* 2001; 166:185-8.
- Backhaus BO, Muller SC, Albers P. Corporoplasty for advanced Peyronie's disease using venous and/or dermis grafting. New surgical technique and long-term patient satisfaction. *J Urol* 2003; 169:981-4.
- Nikoobakht MR, Mehraei A, Pourmand GH, Jaladat H, Nasseh HR. Management of Peyronie's disease with dermal grafting. *Urology* 2004; 2:36-9.
- Irani D, Zeighami SH, Khezri AA. Results of dermal patch graft in the treatment of Peyronie's disease. *Urology* 2004; 2:40-3.
- Kondas J, Dioszeghy G, Konder G, et al. Plaque excision and dermal graft in the surgical treatment of plastic induration of the penis (Peyronie's disease). *Int Urol Nephrol* 1998; 30:321-6.
- Hicks CC, O'Brien DP 3rd, Bostwick J 3rd, Walton KN. Experience with the Horton-Devine dermal graft in the treatment of Peyronie's disease. *Urology* 1978; 119:504-6.
- Usta MF, Bivalacqua TJ, Sanabria J et al. Patient and partner satisfaction and long-term results after surgical treatment for Peyronie's disease. *Urology* 2003; 62:105-9.
- Adenyi AA, Goorney SR, Pryor JP, Ralph DJ. The Lue procedure. An analysis of the outcome in Peyronie's disease. *BJU Int* 2002; 89:404-8.
- Sampaio JS, Fonseca J, Passarinho A, Christino J, Mendes J. Peyronie's disease. Surgical correction of 40 patients with relaxing incision and duramater graft. *Eur Urol* 2002; 41:551-5.
- Egydio PH, Lucon AM, Arap S. Treatment of Peyronie's disease by incomplete circumferential incision of the tunica albuginea and plaque with bovine pericardium graft. *Urology* 2002; 59: 570-4.
- Knoll LD. Use of porcine small intestinal submucosa graft in the surgical management of Peyronie's disease. *Urology* 2001; 57:753-7.
- Breyer BN, Brant WO, Garcia MM, Bella AJ, Lue TF. Complications of porcine small intestine submucosa graft for Peyronie's disease. *J Urol* 2007; 177:589-1.
- Licht MR, Lewis RW. Modified Nesbit procedure for the treatment of Peyronie's disease: a comparative outcome analysis. *J Urol* 1997; 158:460-3.
- Shiohvilli TJ, Kakonashvili AP. The surgical treatment of Peyronie's disease: replacement of plaque by free autograft of buccal mucosa. *Eur Urol* 2005; 48:129-5.
- Montorsi F, Salonia A, Maga T, et al. Evidence based assessment of long-term results of plaque incision and vein grafting for Peyronie's disease. *J Urol Nephrol* 2000; 163:1704-8.
- Thiel DD, Broderick GA, Wu KJ. Inclusion cyst and graft contraction in Tutoplast human cadaveric pericardium following Peyronie's grafting: a previously unreported complication. *Int J Impot Res* 2005; 17:550-2.
- Craatz S, Spanel-Borowski K, Begemann JF, et al. The dorsal lamina of the rectus sheath: a suitable grafting material for the penile tunica albuginea in Peyronie's disease? *BJU Int* 2006; 97:134-7.