

# Recurrent Bell's palsy in a young woman

Ngow H A, Wan Khairina W M N, Hamidon B B

## ABSTRACT

**Bell's palsy is a benign lower motor neuron facial nerve disorder. It is almost always unilateral. We report a 20-year-old nulliparous woman with five episodes of recurrent Bell's palsy. A review of recent medical literature revealed a paucity of case reports involving an individual with five episodes of recurrent Bell's palsy, with none found in Asian neurology medical literature. Despite the multiple episodes of Bell's palsy recurrences, the patient did not suffer much neurological sequelae from the disease.**

**Keywords:** Bell's palsy, facial nerve palsy, lower motor neuron disorder, recurrent nerve palsy

*Singapore Med J 2008; 49(10):e278-e280*

## INTRODUCTION

Bell's palsy is regarded as a benign common neurological disorder of unknown cause. It has an acute onset and is almost always a mononeuritis. The most common symptoms of idiopathic unilateral lower motor neuron facial nerve paralysis include acute facial palsy, hyperacusis and posterior auricular pain on the affected side, altered taste sensation over the anterior two-thirds of the tongue, and incomplete hyperaesthesia over the trigeminal nerve distribution. Recent data has shown complete resolution of symptoms within the first two months of onset in about 70%–80% of cases, leaving approximately 20%–30% of patients with varying degrees of residual facial nerve dysfunction.<sup>(1,2)</sup> A review of recent medical literature revealed a paucity of case reports involving an individual with five episodes of recurrent Bell's palsy, with none found in Asian neurology medical literature.

## CASE REPORT

A 20-year-old female Malay nulliparous teacher attended our neurology clinic for her fifth episode of Bell's palsy. She suffered four previous episodes of unilateral left-sided facial nerve palsy, at the age of 12, 14, 19 and 20 years. All episodes took about four weeks to resolve completely. She was given oral prednisolone and oral acyclovir during her fourth episode of Bell's palsy. The aetiology of the facial nerve palsy was never determined. We did not have information regarding the severity of the previous episodes as she was only referred to our clinic for her fifth episode. There was

no evidence of Ramsay Hunt syndrome, plication of the tongue or labial oedema to account for Melkelsson-Rosenthal syndrome. She denied further history of traumatic injury to the face or a recent flu-like illness. She denied symptoms of a viral illness preceding any of the episodes. She was otherwise well and healthy with no known history of hypertension and diabetes mellitus. Interestingly, her mother had had a single attack of left Bell's palsy in her forties, which resolved completely. There was no other family member involved.

Her latest episode started one week prior to consultation, with sudden onset of left-sided facial weakness, headache, neck pain and distortion of sound in the ipsilateral ear. She denied fever or symptoms of an upper respiratory tract infection. Physical examination revealed left-sided lower motor neuron facial nerve palsy, House-Brackmann Grade IV.<sup>(3)</sup> She was not hypertensive and her blood pressure was 120/80 mmHg. The auricle and oral cavity did not show any vesicle. The nasal septum was not deformed or perforated. There was no ptosis of the left eye. The muscle tone of all four limbs was normal, with full power and normal deep tendon reflexes. The remainder of her physical and neurological examination was normal. The blood count showed mild lymphocytosis and the blood biochemistry panel were normal. Further blood tests including C3, C4, ANA titre and blood sugar level were all normal. However, the erythrocyte sedimentation rate was mildly elevated at 48 mm/hr, despite a normal C-reactive protein. An electroneurography study of her facial nerve was conducted on day 10 of illness, which revealed that the amplitude of the compound muscle action potential (CMAP) of the left facial nerve was only 45% of the right facial nerve. This indicated approximately 55% axonal degeneration of the left facial nerve (Table I and Fig. 1).

She was treated with a course of oral prednisolone 1 mg/kg body weight daily for ten days and oral acyclovir 400 mg five times daily for five days. Eye pad and artificial tears were prescribed for eye protection during sleep. She was also referred for facial physiotherapy with massage of the weakened muscles. At one month follow-up, the facial weakness had improved with sequelae of synkinesis.

## DISCUSSION

A review of the current medical literature revealed very few cases of four or more episodes of Bell's

**Internal Medicine Department, International Islamic University Malaysia, Faculty of Medicine, PO Box 141, Kuantan 25710, Malaysia**

Ngow HA, MD, MMed Assistant Professor and Clinical Specialist

**Department of Paediatrics, Hospital Universiti Kebangsaan Malaysia, Universiti Kebangsaan Malaysia, Jalan Yaakob Latiff, Bandar Tun Razak, Cheras Kuala Lumpur 56000, Malaysia**

Wan Khairina WMN, MBBS Senior Registrar

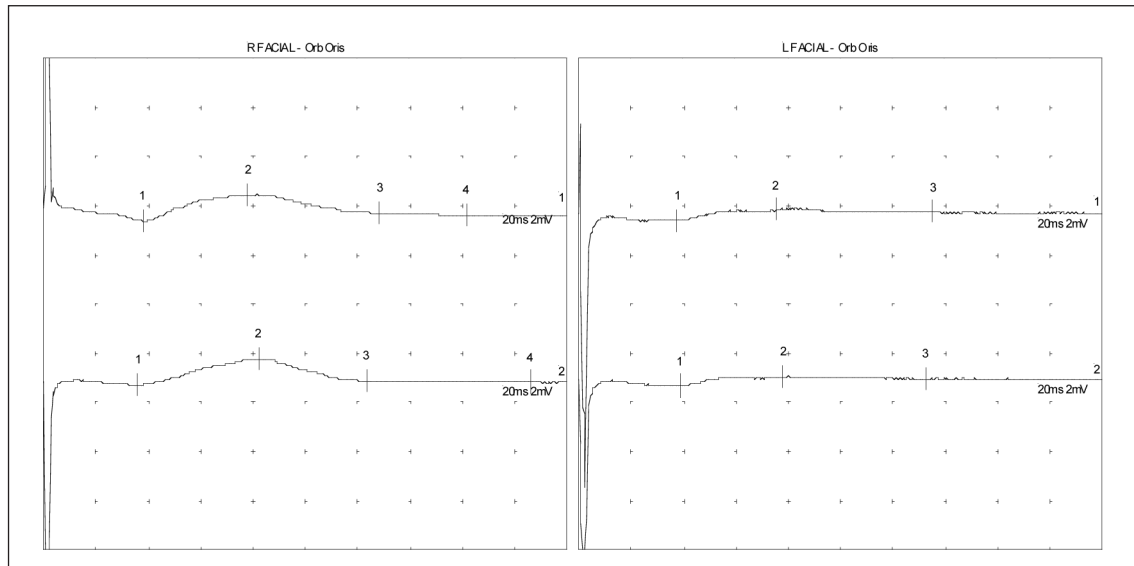
**Medical Department**

Hamidon BB, BSc, MD, MMed Professor and Consultant Neurologist

**Correspondence to:** Dr Harris Ngow Abdullah  
Tel: (60) 9 513 2797  
Fax: (60) 9 513 3615  
Email: harrisngow@gmail.com

**Table I. Readings obtained from the facial nerve electroneurography study.**

Nerve / sites	Onset (ms)	Amp. (mV)	Amp.2-4 (mV)	Dist. (cm)	Vel. (m/s)	d Lat. (ms)
Right facial orbicularis oris						
Anterior ear 1	3.85	1.1	0.9	11		3.85
Anterior ear 2	3.65	1.1	1.0	13	650.0	-0.20
Left facial orbicularis oris						
Anterior ear 1	3.80	0.5	0.2	11		3.80
Anterior ear 2	3.90	0.4	0.2	13	1,300.0	0.10



**Fig. 1** Graph shows the facial nerve conduction study of this patient. The left facial nerve CMAP is only 45% of the right facial nerve. This indicates an approximately 55% axonal degeneration of the left facial nerve.

palsy. Bell's palsy or idiopathic unilateral facial nerve paralysis is the most common cause of unilateral facial palsy. The reported prevalence in the general population is 10–30 cases per 100,000 persons.<sup>(1,2)</sup> Bell's palsy has an equal gender ratio, but some reviews suggest a slight female preponderance.<sup>(2)</sup> Although most reported cases in clinical practice involve patients suffering from a single episode, recurrent ipsilateral or alternating contralateral facial nerve paralysis occur in approximately 10%–15% of patients, as reported in older medical literature.<sup>(4–6)</sup> These recurrent attacks were associated with a strong family history of similar episodes.<sup>(7,8)</sup> Our patient's mother had a single episode of left-sided Bell's palsy in her forties. This may suggest a familial type of recurrent Bell's palsy. However, the lack of recurrent attacks on the mother is not characteristic. Pitts et al found a third recurrence in 3% and fourth recurrence in 1.5% of cases out of 140 patients in their retrospective study; however, there was no specific discussion on the family history of each of these patients.<sup>(9)</sup> We were not able to find newer case series with the exception of the above-mentioned articles. Unlike the other reports of recurrent Bell's palsy, we failed to find a case report

such as ours with five episodes of Bell's palsy without a family history of multiple recurrent attacks. There were several published reports regarding recurrence of Bell's palsy with each pregnancy, but our patient is nulliparous, and as such there is no association.<sup>(10)</sup>

Besides common conditions like hypertension and diabetes mellitus, which may predispose to single or multiple attacks, the aetiology of Bell's palsy is still a matter of debate since it was first reported by Nicolas A Friedrich two centuries ago in 1798.<sup>(11)</sup> The familial cases of recurrent ipsilateral and alternating contralateral facial nerve palsy have both autosomal dominant and recessive inheritance.<sup>(4,7)</sup> This genetic predisposition may also include variations in the immune response of each individual towards the inciting antigen. Some patients may be more easily predisposed to facial nerve inflammation by exposure to a preceding pathogen, such as *Herpes simplex* virus, Epstein-Barr virus and cytomegalovirus. There have been an increasing number of reports on the *Herpes simplex* virus particle found on facial nerve biopsy in patients with Bell's palsy.<sup>(12,13)</sup> This suggests an underlying viral aetiology. Bell's palsy has a very controversial history from its aetiology and natural

history to its management. Bell's palsy is no longer considered idiopathic and is believed to result from a viral insult, most likely *Herpes simplex* virus with secondary oedema and inflammatory demyelination. In addition, a narrowed facial canal diameter may be a predisposing genetic factor in a similar family.<sup>(14)</sup> A coincidental finding from reported cases of recurrent Bell's palsy suggests that the patient's left facial nerve involvement was more prone to recurrence. However, the literature revealed an approximately equal frequency of involvement on either side.<sup>(14)</sup> Finally, despite a multitude of investigations done to elicit a possible aetiology, we failed to demonstrate the cause of multiple recurrences of Bell's palsy in this patient's left facial nerve.

## REFERENCES

1. Morgan M, Nathwani D. Facial palsy and infection: the unfolding story. *Clin Inf Dis* 1992; 14:263-71.
2. Katusic SK, Beard CM, Wiederholt WC, Bergstralh EJ, Kurland LT. Incidence, clinical findings, and prognosis in Bell's palsy, Rochester, Minnesota, 1968-1982. *Ann Neurol* 1986; 20:622-7.
3. House JW, Brackmann DE. Facial nerve grading system. *Otolaryngol Head Neck Surg* 1985; 93:146-7.
4. Cawthorne T, Haynes DR. Facial palsy. *Br Med J* 1956; 2:1197-200.
5. Hallmo P, Elverland HH, Mair IWS. Recurrent facial palsy. *Arch Otorhinolaryngol* 1983; 237:97-102.
6. Boddie HG. Recurrent Bell's palsy. *J Laryngol Otol* 1972; 86:117-20.
7. Hageman G, Ioppel PF, Jansen ENH, Rozeboom AR. Familial, alternating Bell's palsy with dominant inheritance. *Eur Neurol* 1990; 30:310-3.
8. DeSanto LW, Schubert HA. Bell's palsy: ten cases in a family. *Arch Otolaryngol* 1969; 89:700-2.
9. Pitts DB, Adour KK, Hilsinger RL Jr. Recurrent Bell's palsy: analysis of 140 patients. *Laryngoscope* 1988; 98:535-40.
10. Walling AD. Bell's palsy in pregnancy and the puerperium. *J Fam Pract* 1993; 36:559-63.
11. Friedrich NA. De paralysis musculorum facier rheumatica. *J Erfindungen (Gotha)* 1798; 8:25.
12. Burgess RC, Michaels L, Bale JF Jr, Smith RJ. Polymerase chain reaction amplification of herpes simplex viral DNA from the geniculate ganglion of a patient with Bell's palsy. *Ann Otol Rhinol Laryngol* 1994; 103:775-9.
13. Murakami S, Mizobuchi M, Nakashiro Y, et al. Bell's palsy and herpes simplex virus: identification of viral DNA in endoneurial fluid and muscle. *Ann Intern Med* 1996; 124(1 Pt 1):27-30.
14. English JB, Stommel EW, Bernat JL. Recurrent Bell's palsy. *Neurology* 1996; 47:604-5.