

# The treatment of tongue haemangioma by plasma knife surgery

Kutluhan A, Bozdemir K, Ugras S

## ABSTRACT

A seven-year-old girl presented with a 4 cm × 2 cm lesion of the tongue which was located at the posterior one-third in the midline. The lesion was excised by plasma knife surgery. No complication, such as bleeding, shortness of breath or infection, occurred after the treatment. Plasma knife surgery is an acceptable choice for selected benign lingual vascular malformations.

**Keywords:** haemangioma, oral cavity tumours, plasma knife surgery, radiofrequency surgery, tongue haemangioma, vascular tumours

*Singapore Med J 2008;49(11):e312-e314*

## INTRODUCTION

Vascular lesions of the tongue are rare lesions which can create clinical problems consisting, in the majority of cases, of spontaneous haemorrhage from the mouth. The other common complaints are pain, shortness of breath secondary to the enlargement of the tongue, and the disabilities of chewing and speaking. Embolisation, excision, cryotherapy, sclerotherapy, radiation, laser photocoagulation and chemotherapy methods had been used for the treatment of this kind of lesions in the past.<sup>(1)</sup> More aggressive treatment methods could cause lingual tissue loss and major functional disability. Conservative treatment choices were either insufficient or subject to recurrence. Plasma knife surgery with radiofrequency (PK), one of the new developing technologies, could be a suitable choice for some haemangiomas of the tongue. We report a case of excision by using PK on a frequently-bleeding tongue hemangioma.

## CASE REPORT

A seven-year-old girl was admitted to our clinic with a lesion of her tongue that was enlarging slowly in the recent two years. In last six months, the lesion was bleeding and caused pain on moving the tongue. The lesion was observed in the posterior two-thirds of the tongue on the midline, with a size of 4 cm × 2 cm (Fig. 1). She also had subcutaneous skin lesions, which looked like haemangioma, in the subclavian region. The lesion was totally resected by PK under general anaesthesia with a prediagnosis of haemangioma of the tongue. This PK procedure was performed under 90% coagulation and 10% cut mode as PK tonsillectomy. The

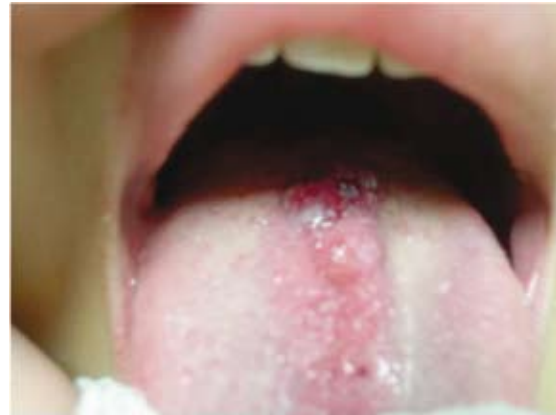

Fig. 1 Photograph shows the patient's tongue haemangioma.

lesion was excised just near to the normal tissue. There was no bleeding during the procedure. Neither pain nor shortness of breath was seen postoperatively. Cold fluid food intake started three hours after the surgery. The patient's chewing, swallowing and speaking were normal. Postoperative pathological diagnosis was haemangioma (Fig. 2). The patient was hospitalised for a night just as a precaution to observe for oedema, bleeding and airway obstruction. The wound healed in three weeks (Fig. 3), and there was no recurrence after six months.

## DISCUSSION

Haemangiomas are among the most common neoplasms encountered in the paediatric age group. Some of the childhood haemangiomas may have spontaneous regression, but some of the lesions need urgent treatment, especially if they could cause airway obstruction, bleeding and thrombocytopenia, infection or cardiovascular problems.<sup>(2)</sup> If the lesions are so large that could not be resected totally, they are suitable for the symptomatic control of the lesion.<sup>(3)</sup> In our case, treatment was mandatory because of the site of the haemangioma.

The mucosal haemangioma is typically a soft, moderately well-circumscribed, painless mass which is red or blue in colouration. The more superficial ones are often lobulated and will blanch under finger pressure. Deeper lesions tend to be dome-shaped with normal or blue surface colouration; they seldom blanch. The haemangioma is characterised by an excess of blood vessels, usually veins and capillaries, in a focal area of the submucosal connective tissue. It is almost

ENT Department,  
Ankara Ataturk  
Education and  
Research Hospital,  
Ankara,  
Turkey

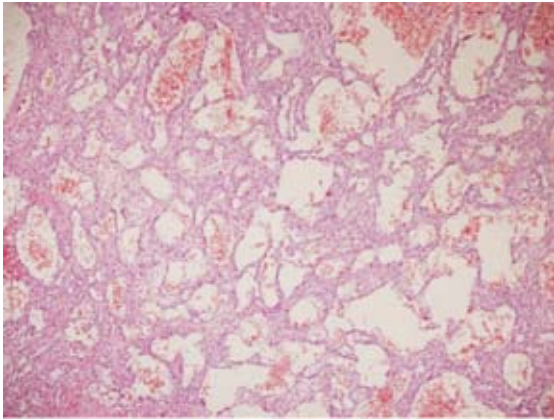
Kutluhan A, MD  
Professor

Bozdemir K, MD  
Specialist

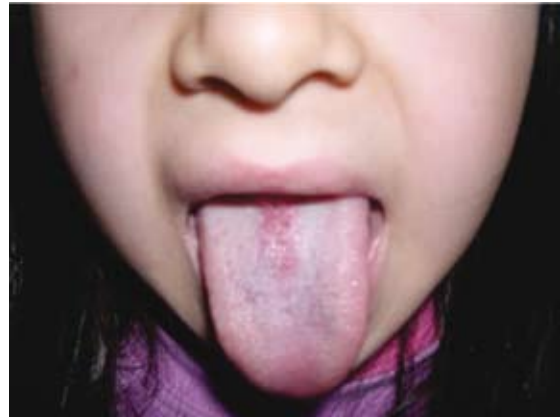Department of  
Pathology

Ugras S, MD  
Professor

**Correspondence to:**  
Prof Ahmet Kutluhan  
Tel: (90) 532 283 4651  
Fax: (90) 312 291 2726  
Email: ahkutluhan@  
hotmail.com



**Fig. 2** Photomicrograph shows a one-line serial endothelial cell covered, consisting of erythrocytes in its lumen of a vascular structure (Haematoxylin & eosin,  $\times 100$ ).



**Fig. 3** Postoperative photograph of the tongue.

never encapsulated. Lesions are subdivided into several categories: capillary haemangioma, cavernous haemangioma, epithelioid haemangioma, intramuscular haemangioma and sinusoidal haemangioma. Haemangiomas comprise numerous intertwining vessels lined by endothelium with relatively flat or plump nuclei, depending on the duration of the lesion.

Conservative or further aggressive forms of treatment may be tried for the haemangioma cases of the tongue. Both treatment methods have disadvantages. In the conservative treatment, recurrences may be frequent. On the other hand, aggressive treatment could also cause function loss. However, the results of cryotherapy have been reported to have high success rates.<sup>(4)</sup> Su et al found that the cure rate was 77.5% in 120 cases with venous malformations, and the incomplete cure rate was declared as 17.5% and that the cryotherapy effectiveness is high in patients with venous malformations.<sup>(5)</sup> However, cryotherapy was not available in our clinic nor our country. Besides, this new technique (PK), of which the success rate we were unaware, was used successfully in our haemangioma case.

Due to its side effects, radiotherapy and chemotherapy would not be suitable as a treatment choice for this lesion. Swallowing, chewing and speaking function disabilities were seen in the cases where CO<sub>2</sub> laser was applied. Combined treatments applied as ligation, embolisation or radiofrequency were additional treatment modes to excision of the lesion.<sup>(6)</sup> Clymer et al applied photocoagulation with interstitial Nd:YAG laser including one case of tongue haemangioma and eight head and neck haemangiomas.<sup>(7)</sup> The patient with the tongue haemangioma was one year of age and had 7% reduction of the lesion after 617 J of laser which had been applied twice. The haemangiomas which were located at the bucca, the upper and the lower lip, the nasal tip and the forehead had been treated by laser

for an average of 4.7 times, and the mean reduction in volume of the lesion was 53% (range 33%–74%). No lesion enlargement was observed during the one-year follow-up. The authors declared that Nd:YAG laser was a reliable surgical technique which has advantages like minimal complications, stable response to the treatment, and less blood loss. The disadvantage of this technique was that five repeat surgeries had to be done.<sup>(7)</sup>

PK is a new treatment modality for excision of these lesions. PK technology provides an electrically conducting site by means of obtaining the use of controlled radiofrequency energy, and by using the intra- and extracellular fluid. The active zone on the device provides an ionised layer by means of radiofrequency waves. Dense kinetic energy divides, demolishes and evaporates the constructional element tissue. During this procedure, there is very little thermal damage to the surrounding tissue. Because it requires no additional saline supply for the operation according to the thermal procedure, its tip temperature remains a cool 70°C–80°C. Therefore, it provides a pink viable resection bed. PK is developed for tonsillectomy, adenoidectomy, uvulopalatopharyngoplasty, thyroidectomy and excisions of the head and neck masses.<sup>(8,9)</sup> We used a 90% coagulation and 10% cut mode choice for the PK excision of the haemangioma of the tongue. It was shown that the PK was capable to control the bleeding. This method is consequently a safe and suitable surgical choice to be applied for superficial and small-sized haemangiomas of the tongue. In our case, there was no swelling of the tongue, bleeding nor pain postoperatively. There was also no problem of speaking and swallowing. The experience that we gained from this case is that the PK surgery would be a suitable treatment modality for the localised and superficial haemangiomas of the tongue. PK can also be combined with other treatment modalities in larger lesions.

## REFERENCES

1. Hobby LW. Further evaluation of the potential of the argon laser in the treatment of strawberry hemangiomas. *Plast Reconstr Surg* 1983; 71:481-5.
2. Cohen SR, Wang CL. Steroid treatment of hemangioma of the head and neck in children. *Ann Otol* 1972; 81:584-90.
3. Dixon JA, Davis RK, Gilbertson JJ. Laser photocoagulation of vascular malformations of the tongue. *Laryngoscope* 1986; 96:537-41.
4. Qureshi SS, Chaukar DA, Pathak KA, et al. Hemangioma of base of tongue. *Indian J Cancer* 2004; 41:181-3.
5. Su T, Liu B, Zhao JH, Zhao YF. [Cryotherapy combined with pingyangmycin for the treatment of venous malformations]. *Zhonghua Zheng Xing Wai Ke Za Zhi* 2006; 22:453-4. Chinese.
6. Nour SG, Lewin JS, Gutman M, et al. Percutaneous MR imaging-guided radiofrequency interstitial thermal ablation of tongue base in porcine models: implications for obstructive sleep apnea syndrome. *Radiology* 2004; 230:359-68.
7. Clymer MA, Fortune DS, Reinisch L, et al. Interstitial Nd:YAG photocoagulation for vascular malformations and hemangiomas in childhood. *Arch Otolaryngol Head Neck Surg* 1998; 124:431-6.
8. Chang KW. Randomized controlled trial of Coblation versus electrocautery tonsillectomy. *Otolaryngol Head Neck Surg* 2005; 132:273-80.
9. Hall DJ, Littlefield PD, Birkmire-Peters DP, Holtel MR. Radiofrequency ablation versus electrocautery in tonsillectomy. *Otolaryngol Head Neck Surg* 2004; 130:300-5.