

# Primary osteogenic sarcoma of the breast

Dragoumis D, Bimpa K, Assimaki A, Tsiftoglou A

## ABSTRACT

Primary osteogenic sarcomas of the breast are exceptionally uncommon. We describe such a case occurring in a 66-year-old woman who presented with a hard mass in her left breast. Mammography and breast ultrasonography showed a calcified breast lump, but features were not diagnostic. Modified radical mastectomy of the left breast, including axillary lymph node dissection, was performed. Microscopical and immunohistochemical findings established the diagnosis of primary osteogenic sarcoma. Because there was no evidence of metastasis, no further treatment was considered necessary. She remained well 15 months later, without tumour recurrence. We discuss in detail the diagnostic implications of this rare entity.

**Keywords:** breast osteogenic sarcoma, breast tumour, extraskelatal osteogenic sarcoma, osteogenic sarcoma, soft tissue sarcoma

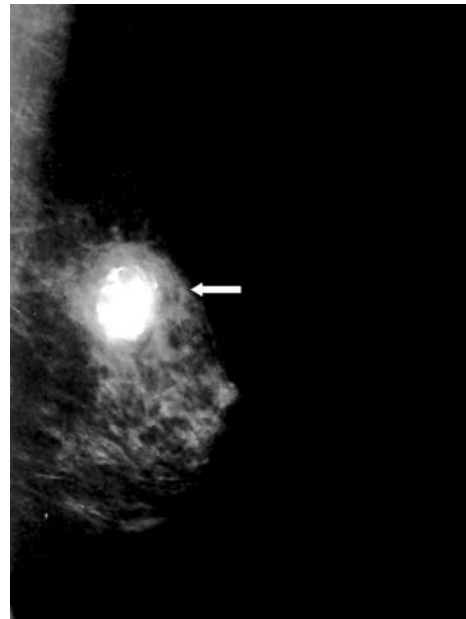
*Singapore Med J 2008;49(11):e315-e317*

## INTRODUCTION

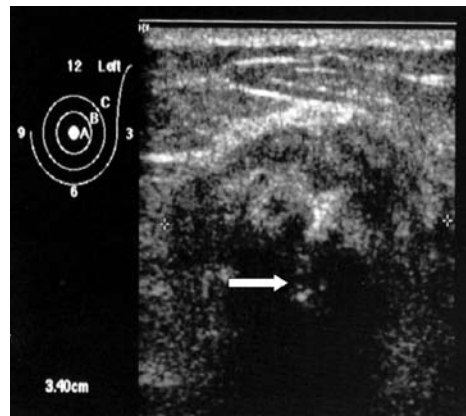
Extraskelatal osteogenic sarcomas account for less than 1% of soft tissue sarcomas. Mammary sarcomas are also relatively uncommon, representing less than 1% of all primary breast malignancies, while primary osteosarcomas of the breast are extremely rare. Almost every previous reference to this entity in the medical literature has been in the form of isolated case reports. In all cases, the patients had been diagnosed clinically as having breast carcinoma and the correct tissue diagnosis was established histologically. The largest collection of primary breast osteogenic sarcomas is a retrospective clinicopathological analysis of 50 cases seen over a 38-year period.<sup>(1)</sup> Our paper describes a 66-year-old woman with a primary osteogenic sarcoma arising in the left breast.

## CASE REPORT

A 66-year-old woman became aware of a non-tender lump in the medial upper quadrant of her left breast. She first noticed the mass one month previously. During



**Fig. 1** Mammogram shows a dense calcified lesion (white arrow), radiologically mimicking a calcified fibroadenoma or breast carcinoma.



**Fig. 2** Breast US image shows a large, hypoechoic mass, with an echogenic centre (white arrow).

this period, she did not have any pain or discharge from the nipple. Her family history was unremarkable, as was her medical history. She had three children and two miscarriages in her gynaecological history, and had never undergone any radiation, birth control or hormone replacement therapy. On physical examination, the patient had a palpable, hard tumour, approximately 4 cm in diameter, which was located on the medial upper quadrant of the left breast. There was no palpable axillary

Department of  
General Surgery,  
Breast Division,  
St Luke's Hospital,  
Panorama,  
Thessaloniki 55236,  
Greece

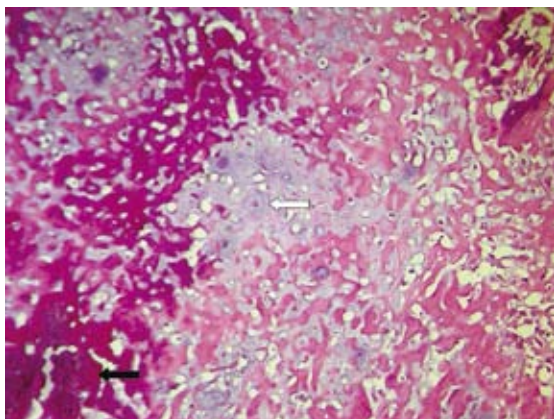
Dragoumis D, MD  
Registrar

Bimpa K, MD, PhD  
Registrar

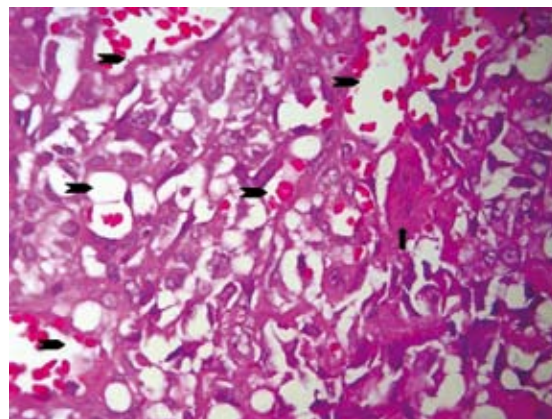
Assimaki A, MD,  
Associate Consultant

Tsiftoglou A, MD  
Consultant

**Correspondence to:**  
Dr Dimitrios M  
Dragoumis  
Tel: (30) 2310 212 497  
Fax: (30) 2310 230 640  
Email: ddragoumis@  
gmail.com



**Fig. 3** Photomicrograph shows neoplastic bone (black arrow) and chondroid tissue (white arrow) (Haematoxylin & eosin,  $\times 200$ ).



**Fig. 4** Photomicrograph shows neoplastic cells (arrowheads) and multinucleated giant cells (arrow) with irregular nuclei (Haematoxylin & eosin,  $\times 200$ ).

lymph node and there were no abnormal findings on the right breast. A clinical diagnosis of a locally-advanced cancer of the left breast was made.

Mammography, first performed to investigate this lesion, revealed a dense, 3-cm calcified lesion, with irregular margins, in the upper medial quadrant of the left breast (Fig. 1). Breast ultrasonography (US) confirmed the presence of a hypoechoic mass (Fig. 2), occupying the upper quadrants of the left breast, suspicious of a fibroadenoma or breast carcinoma. Preoperative examination consisting of a full blood count, serum kidney and liver functions, as well as cancer markers (CEA, CA 15-3, CA 125) and US of the abdomen failed to document any abnormalities. An isotope bone scan did not reveal any abnormal uptake. Fine-needle aspiration was performed, but did not retrieve any meaningful tissue. Excisional biopsy and frozen section analysis confirmed the malignant nature of the lump. The patient eventually underwent a modified radical mastectomy of the left breast, including axillary lymph node dissection.

The macroscopical examination revealed a hard, spherical, well-circumscribed lesion measuring 4 cm in diameter. Histologically, there was a malignant neoplasm comprising islands of chondroblastic, osteoblastic stromal cells and reactive multinucleated giant cells (Figs. 3 & 4). Mitotic activity was easily observed. The microscopical pattern consisted of pleomorphic, round and spindle-shaped tumour cells with large, irregular nuclei. Cut sections documented the presence of 11 axillary lymph nodes, with no metastatic deposits noted within the nodes. The neoplastic cells expressed smooth muscle actin (SMA) and vimentin, but they did not express wide-spectrum keratin, AE1/AE3, S-100 protein, HER 2/neu protein, progesterone and oestrogen receptors (Fig. 5). The histological and immunohistochemical findings therefore established the diagnosis of primary osteogenic sarcoma of the breast.

Postoperative computed tomography of the chest

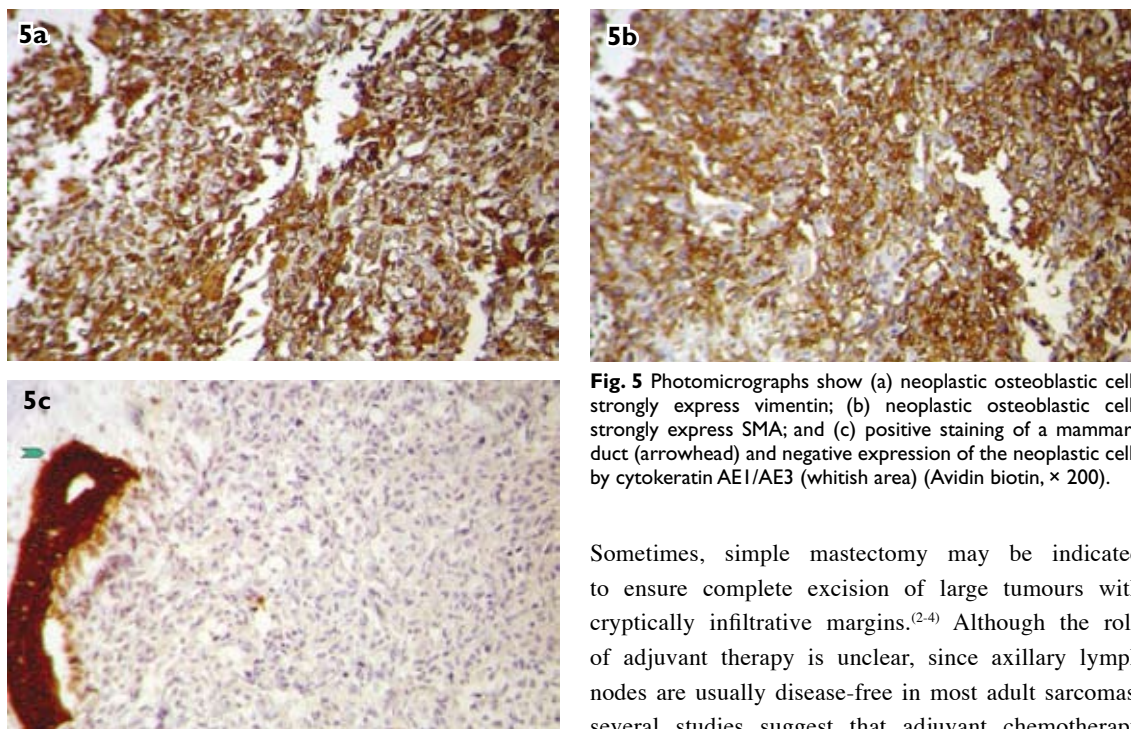
and abdomen showed no evidence of metastatic disease. We did not consider that adjuvant treatment was necessary in the presence of adequate local control and in the absence of metastatic spread of disease. Follow-up mammography was satisfactory to date, and she remained well without tumour recurrence at 15 months.

## DISCUSSION

Primary osteogenic sarcomas of the breast are exceptionally rare, with published references generally limited to case reports. However, the actual incidence is difficult to determine, because some of the approximately 100 previously-reported cases probably included metaplastic carcinomas, as well as osteogenic sarcomas arising in association with a biphasic tumour, such as phyllodes tumour or carcinosarcoma.<sup>(1,2)</sup> Primary osteogenic sarcoma of the breast affects mainly advanced-aged women (over 64 years of age), but it has also been described in men. The aetiological factors are indistinct, although it has rarely been reported arising in breast tissue, due to prior local irradiation and trauma.<sup>(2)</sup>

The typical clinical appearance of breast osteogenic sarcoma is a mobile, hard, irregular lump with no axillary lymphadenopathy. An elevated serum alkaline phosphatase has been associated with high histochemical expression in the tumour, and this level usually declines following excision. The mammographical finding is of a well-circumscribed, dense lesion with prominent calcifications within the mass. Targeted breast US usually confirms the presence of a well-defined mass, hypoechoic with an echogenic centre, due to the existence of calcifications. However, it is very difficult to diagnose mammary osteogenic sarcoma from the clinical features, such as those revealed by palpation, mammogram and US appearance.<sup>(2,3)</sup>

Histologically, they can be classified into three subtypes, including fibroblastic, osteoblastic and osteoclastic osteogenic sarcomas. Histological



**Fig. 5** Photomicrographs show (a) neoplastic osteoblastic cells strongly express vimentin; (b) neoplastic osteoblastic cells strongly express SMA; and (c) positive staining of a mammary duct (arrowhead) and negative expression of the neoplastic cells by cytokeratin AE1/AE3 (whitish area) (Avidin biotin,  $\times 200$ ).

differentiation is important, since fibroblastic osteogenic sarcomas are associated with a better survival outcome than other pathological types.<sup>(3,4)</sup> In our patient, the osteoblastic cells were the prevailing neoplastic element of the lesion, thus subcategorising the tumour under the osteoblastic subtype. The presence of bone or osteoid element in breast lesions is relatively rare, but has been also described in epithelial neoplasms, such as metaplastic carcinomas. Metaplastic carcinomas typically are immunoreactive for cytokeratin, identifying them as epithelial neoplasms.<sup>(3)</sup>

The basic requirements for the diagnosis of a primary osteosarcoma of the breast, according to Allan and Soule, include (a) the presence of neoplastic osteoid or bone, (b) the exclusion of origin in the bone, and (c) the absence of an epithelial component.<sup>(5)</sup> In our patient, the result of an isotope skeletal bone scan aided in excluding the possibility of a primary bone tumour, while histological and immunohistochemical analyses showed no evidence of epithelial differentiation. Osteosarcomas of the breast are biologically aggressive neoplasms characterised by early recurrences (43% at a median of one year) and haematogeneous metastatic spread, frequently to the lungs, bone, liver and soft tissues (skin/subcutaneous). A large tumour size significantly predicts a worse therapeutic outcome, while the five-year survival rate is dismal (approximately 38%).<sup>(1,6)</sup>

The cardinal treatment should include total excision of the primary tumour with clear resection margins, in order to reduce the possibility for tumour recurrence.

Sometimes, simple mastectomy may be indicated to ensure complete excision of large tumours with cryptically infiltrative margins.<sup>(2,4)</sup> Although the role of adjuvant therapy is unclear, since axillary lymph nodes are usually disease-free in most adult sarcomas, several studies suggest that adjuvant chemotherapy may be of value in patient management. As adjuvant combination chemotherapy has spectacularly increased survival in osteogenic sarcoma of the bone, combination chemotherapy and local radiotherapy have been proposed for mammary osteosarcoma, although there is still no distinct treatment strategy which has a proven beneficial impact in long-term survival.<sup>(6,7)</sup>

We report another case of osteosarcoma of the breast, where a definitive diagnosis was made based on histology and immunochemistry. To date, surgical excision with clear surgical margins remains the cornerstone of treatment, as it offers the best outcome for patients. However, due to its rarity, there is still inadequate data on chemotherapy and local radiotherapy for control of tumour recurrences.

## REFERENCES

- Silver SA, Tavassoli FA. Primary osteogenic sarcoma of the breast. A clinicopathologic analysis of 50 cases. *Am J Surg Pathol* 1998; 22:25-33.
- Vorobiof G, Hariparsad G, Freinkel W, Said H, Vorobiof DA. Primary osteosarcoma of the breast: a case report. *Breast J* 2003; 9:231-3.
- Sando N, Oka K, Moriya T, et al. Osteosarcoma arising in the breast. *APMIS*, 2006; 114:580-6.
- Ogundiran TO, Ademola SA, Oluwatosin OM, Akang EE, Adebamowo CA. Primary osteogenic sarcoma of the breast. *World J Surg Onc* 2006; 4:90-4.
- Allan CJ, Soule EH. Osteogenic sarcoma of the somatic soft tissues. A clinicopathologic study of 26 cases and review of literature. *Cancer* 1971; 27:1121-33.
- Brustugun OT, Reed W, Poulsen JP, Bruland ØS. Primary osteosarcoma of the breast. *Acta Oncol* 2005; 7:767-70.
- Irshad K, Mann BS, Cambell H. Primary osteosarcoma of the breast. *Breast* 2003; 12:72-4.