

CME Article

Pancreas divisum: magnetic resonance cholangiopancreatography findings

Chalazonitis N A, Lachanis B S, Laspas F, Ptohis N, Tsimitselis G, Tzovara J

ABSTRACT

Pancreas divisum is a common congenital abnormality of the pancreas that results from the lack of fusion between the dorsal and ventral pancreatic ducts during foetal development. In these cases, the dorsal duct becomes the main pancreatic duct and drains most of the pancreas. Pancreas divisum is mainly asymptomatic, but the prevalence of pancreas divisum is higher in patients with chronic abdominal pain and idiopathic pancreatitis. A study of 20 patients with pancreas divisum (12 men and eight women; aged 19–77 years; mean age 39 years) and who underwent magnetic resonance cholangiopancreatography (MRCP), was performed. In our series, pancreas divisum was clinically manifested as unexplained episodes of abdominal pain (mean duration 3.2 years) (60 percent), mild pancreatitis (30 percent) or incidentally (ten percent). MRCP demonstrated non-communicating dorsal and ventral ducts, independent drainage sites, a dominant dorsal pancreatic duct, and a small cystic dilatation of the dorsal duct at minor papilla (santorinocoele). In this pictorial essay, we review the most common MRCP features of pancreas divisum.

Keywords: magnetic resonance cholangiopancreatography, pancreas divisum, pancreatic anomaly, pancreatitis

Singapore Med J 2008;49(11):951-955

INTRODUCTION

Pancreas divisum affects 5%–10% of the population and is considered to be a congenital anomaly of pancreatic ductal configuration.⁽¹⁾ Embryologically, the ventral pancreatic bud and biliary system arise from the hepatic diverticulum, and the dorsal pancreatic bud arises from the dorsal mesogastrium. Under normal conditions, as the ventral bud rotates around the foregut, there is fusion of the dorsal pancreas and ventral pancreas, and the ventral pancreatic duct fuses with the dorsal pancreatic duct and form the duct of Wirsung. Drainage of a normal pancreas normally occurs through the ventral duct of Wirsung, which joins the common bile duct at the level of the major papilla. The dorsal duct often remains as duct of Santorini, and empties into the duodenum through the

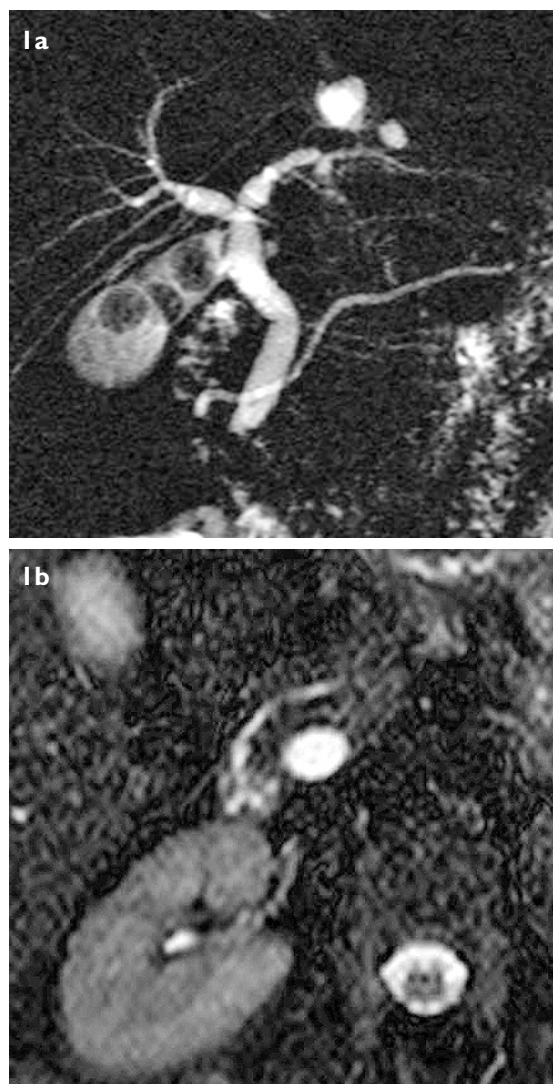


Fig. 1 (a) SS-TSE MRCP image shows the dorsal pancreatic duct draining through the minor papilla. The diameter and morphology of the pancreatic duct is normal. Note multiple gallstones. (b) Axial HASTE MRCP image shows the horizontal course of the dorsal pancreatic duct towards the minor papilla in front of the common bile duct.

minor papilla. When the dorsal and ventral pancreatic ducts fail to fuse, pancreas divisum occurs; this means that most of the glandular parenchyma is drained by the dorsal duct through the minor papilla. The smaller ventral duct, however, drains some of the pancreatic head through the major papilla, including the uncinete process.⁽²⁻⁴⁾

Although most people with pancreas divisum have no clinical disease, it has been suggested that pancreas

Department of
Radiology,
Hippocraton
General Hospital,
Athens,
Greece

Chalazonitis NA, MD,
PhD, MPH
Consultant

Laspas F, MD, MSc
Resident

Ptohis N, MD, PhD
Resident

Tsimitselis G, MD
Consultant

Tzovara J, MD
Consultant

Department of
Radiology,
(401) Army General
Hospital,
Athens,
Greece

Lachanis BS, MD
Director

Correspondence to:
Dr Fotios Laspas
Tel: (30) 210 601 1821
Fax: (30) 210 686 7196
Email: fotisdimi@
yahoo.gr

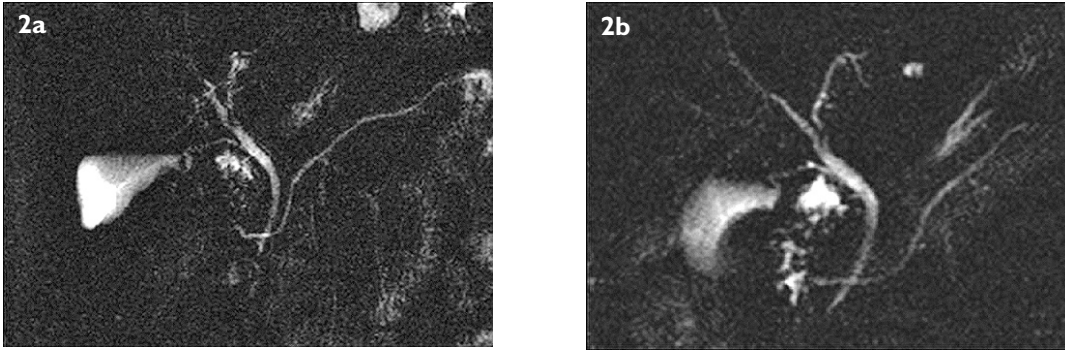


Fig. 2 (a,b) Coronal SS-TSE MRCP images show the complete pancreas divisum without dilatation of pancreatic duct. The common bile duct drains through the major papilla orifice.

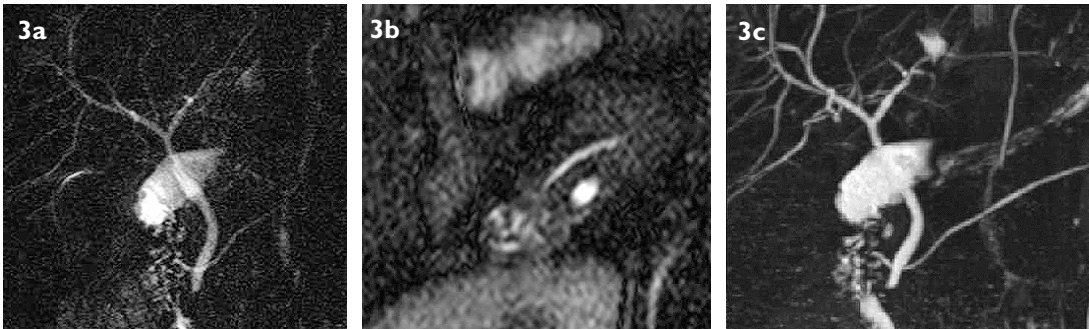


Fig. 3 A 31-year-old man presented with abdominal pain. (a) SS-TSE MRCP image shows that the main pancreatic duct and collateral side branches are both dilated. (b) Consecutive axial HASTE MRCP image shows dilatation of the main pancreatic duct. (c) 3D-TSE MIP image shows a typical case of pancreas divisum. Note the better visualisation of the pancreatic duct on the 3D-TSE MIP image.

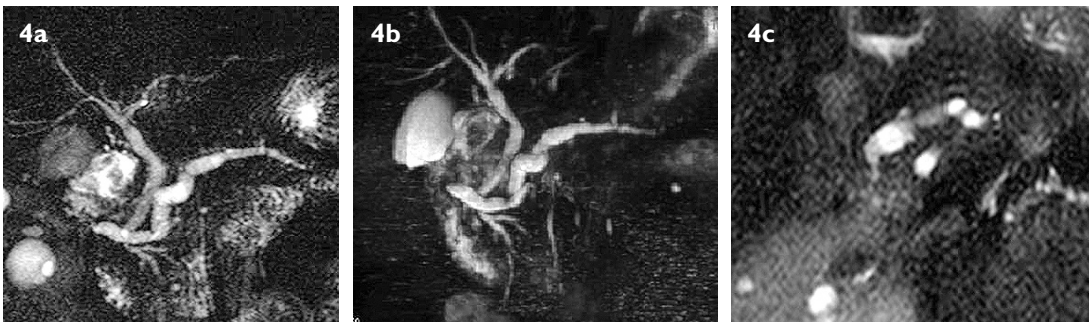

Fig. 4 (a,b) SS-FSE MRCP images show dilatation of the dorsal duct and small outpouchings of many collateral side ducts. (c) Axial HASTE image shows the dilated dorsal duct with stenosis at the orifice of the duct at minor papilla.

divisum may cause unexplained abdominal pain, recurrent episodes of acute pancreatitis or mild chronic pancreatitis, due to the presence of relative obstruction to the drainage of pancreatic secretions at the minor papilla. The inherently small diameter of the minor papilla causes increased pressures in the dorsal pancreatic duct. Pancreas divisum is found in 15%–20% of patients with unexplained pancreatitis.⁽⁵⁻⁷⁾ Endoscopic retrograde pancreatography can be used to make a definitive diagnosis of pancreas divisum. If standard cannulation of the major papilla is performed, endoscopic retrograde pancreatography reveals only ventral duct opacification. The filling of the dominant dorsal duct can be achieved by cannulation of the minor papilla.

Magnetic resonance cholangiopancreatography (MRCP) is a non-invasive diagnostic technique that

depicts the pancreatic ducts without injection of iodinated contrast material and has been shown to be highly sensitive and specific for pancreas divisum. Non-communication of the dorsal and central ducts, independent drainage sites and a dominant dorsal pancreatic duct can be seen using MRCP. Typically, the ventral duct is short and extremely narrow, while the dorsal duct is normally larger in calibre. Depiction of the pancreatic ducts can be improved using dynamic MRCP of the pancreatic duct after secretin stimulation. Secretin MRCP can improve the detection and classification of pancreas divisum. Abnormal persistent poststimulatory dilatation, a sign of ampullary dysfunction, can be shown with MRCP performed before and after secretin injection.^(1,8-11) Abdominal pain and recurrent pancreatitis associated with pancreas divisum is normally treated with minor papilla sphincterotomy.⁽¹²⁾

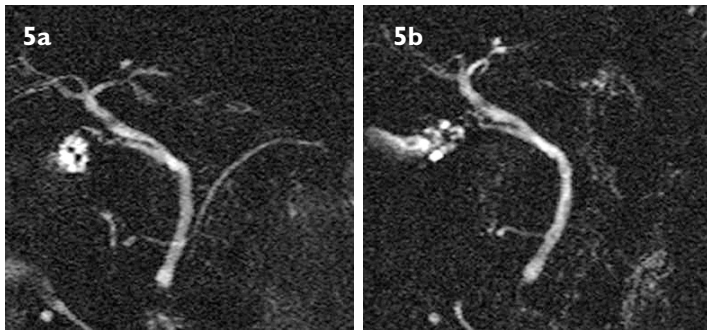


Fig. 5 (a,b) SS-FSE MRCP images show pancreas divisum associated with small focal round dilatation of the duct at the minor papilla representing a small santorinocoele.

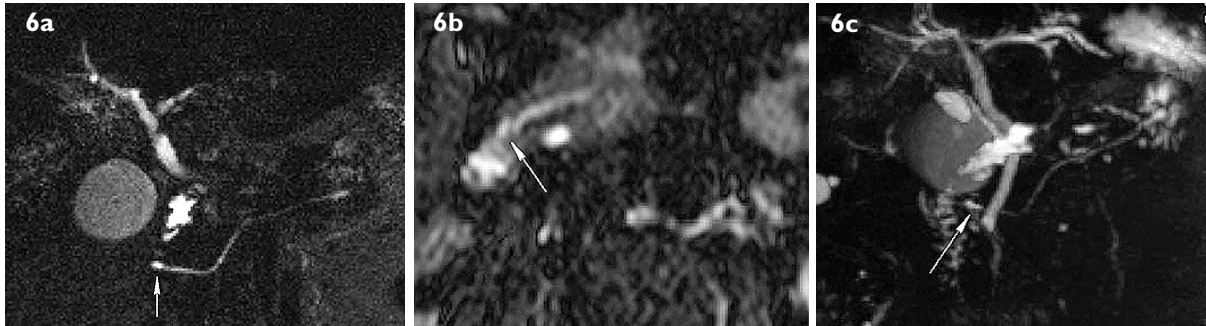


Fig. 6 A 23-year-old man with episodes of unexplained pain. (a) Source image of a 3D-TSE MTCP shows a small saccular dilatation of the dorsal duct at the minor papilla (santorinocoele – arrow). (b) Axial HASTE MRCP image that shows the main pancreatic duct. (The arrow shows a santorinocoele of the dorsal duct at the minor papilla). (c) SS-TSE MRCP image shows small cystic dilatation of the dorsal duct at the minor papilla (santorinocoele – arrow).

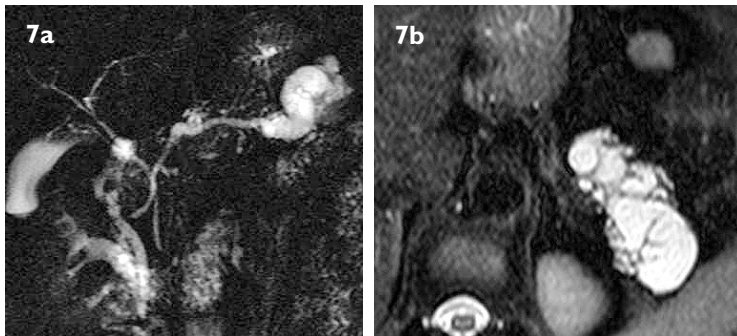


Fig. 7 (a) Pancreas divisum is associated with striking dilatation of the main pancreatic duct at the tail of the pancreas. (b) The dilated duct has many septa evident on the axial HASTE MRCP image. Differential diagnosis included IPMT of the main duct type and chronic pancreatitis.

CLINICAL FEATURES

Our series included 20 patients (12 men and eight women; age range 19–77 years; mean age 39 years). 12 of them presented with unexplained abdominal pain without hyperamylasaemia (four with first episode, eight with recurrent episodes, mean duration 3.2 years). Six patients presented with pancreatitis (three with first episode, three with recurrent episodes, mean 2.4 episodes) and two patients presented with symptomatic cholelithiasis.

The details of clinical history of some patients included:

- A 56-year-old patient with symptomatic cholelithiasis without hyperamylasaemia (Fig. 1).
- A 22-year-old man who presented with first episode of unexplained abdominal pain without hyperamylasaemia (Fig. 2).
- A 31-year-old man with abdominal pain (Fig 3).
- A 36-year-old woman with her fourth episode of mild pancreatitis (Fig. 4).
- A 24-year-old woman with her first episode of pancreatitis and incomplete pancreas divisum (Fig. 5).

- A 23-year-old man with episodes of unexplained pain (Fig. 6).
- A 54-year-old man with recurrent episodes of unexplained abdominal pain (Fig. 7). This patient refused surgery.

IMAGING FINDINGS

Pancreas divisum was detected in 15 patients. In 12 of those patients, this was the sole abnormality seen; whereas in the other three patients, the pancreas divisum was associated with the presence of small santorinocoele (small cystic dilatation of the dorsal duct). Incomplete pancreas divisum was depicted on MRCP images in two patients; one of them associated with santorinocoele. Other findings included two cases associated with dilatation of dorsal duct and side branches, and one case associated with significant focal dilatation of the duct with septa, probably intraductal papillary mucinous tumour (IPMT).

On SS-TSE images, the dorsal duct drained to the minor papilla, independent of common bile duct (Figs. 1a & 2). On axial HASTE images, the course of the duct was

horizontal in front of the common bile duct towards the minor papilla (Fig. 1b). Most cases of pancreas divisum in our series showed a normal diameter main duct without associated findings (Figs. 2 & 7). The main pancreatic duct and collateral side branches may be dilated (Figs. 3a & b). Sometimes stenosis of the main duct at the minor papilla may be evident (Fig. 3c). One case of incomplete pancreas divisum showed a small delicate side branch connecting the ventral with the dorsal duct, a finding that may be more evident on tomographic HASTE images than projectional SS-TSE images because of MIP limitations (Fig. 5). A santorinocoele is a small saccular dilatation of the dorsal duct at minor papilla,^(5,8) and we found it in 15% of our cases (Figs. 5 & 6). Its incidence may be higher on MRCP post-secretin stimulation. One case was associated with significant focal dilatation of the main duct in the tail with multiple septa, a finding that may be due to chronic pancreatitis or to IPMT of the main duct type (Fig. 7). The patient refused further investigation and was lost to follow-up. In three patients, we compared a respiratory-triggered 3D-TSE technique that showed pancreas divisum more clearly than the SS-TSE technique (Fig. 3c).

CONCLUSION

Although the majority of patients with pancreas divisum are asymptomatic, there is a subset of patients who have either pancreatic-type pain or recurrent episodes of acute pancreatitis. MRCP (particularly with secretin stimulation) may be the best way to diagnose and investigate patients with pancreas divisum because of its capacity as a non-invasive examination.

REFERENCES

1. Morgan DE, Logan K, Baron TH, Koehler RE, Smith JK. Pancreas divisum: implications for diagnostic and therapeutic pancreatography. *Am J Roentgenol* 1999; 173:193-8.
2. Schulte SJ. Embryology, normal variation, and congenital anomalies of the pancreas. In: Margulis' and Burhenne's Alimentary Tract Radiology. 5th ed. St Louis: Mosby, 1994: 1039-51.
3. Agha FP, Williams KD. Pancreas divisum: Incidence, detection and clinical significance. *Am J Gastroenterol* 1987; 82:315-20.
4. Mortel  KJ, Ros PR. Anatomic variants of the biliary tree: MR cholangiographic findings and clinical applications. *Am J Roentgenol* 2001; 177:389-94.
5. Klein SD, Affronti JP. Pancreas divisum, an evidence-based review: part I, pathophysiology. *Gastrointest Endosc* 2004; 60:419-25.
6. Mortele KJ, Wiesner W, Zou KH, Ros PR, Silverman SG. Asymptomatic non-specific serum hyperamylasemia and hyperlipasemia: spectrum of MRCP findings and clinical implications. *Abdom Imaging* 2004; 29:109-14.
7. Manfredi R, Lucidi V, Gui B, et al. Idiopathic chronic pancreatitis in children: MR cholangiopancreatography after secretin administration. *Radiology* 2002; 224:675-82.
8. Manfredi R, Costamagna G, Brizi MG, et al. Pancreas divisum and "santorinocoele": diagnosis with dynamic MR cholangiopancreatography with secretin stimulation. *Radiology* 2000; 217:403-8.
9. Mortele KJ, Rocha TC, Streeter JL, Taylor AJ. Multimodality imaging of pancreatic and biliary congenital anomalies. *RadioGraphics* 2006; 26:715-31.
10. Barish MA, Yucel K, Ferrucci JT. Magnetic resonance cholangiopancreatography. *N Engl J Med* 1999; 341:258-64.
11. Matos C, Metens T, Deviere J, et al. Pancreas divisum: evaluation with secretin-enhanced magnetic resonance cholangiopancreatography. *Gastrointest Endosc* 2001; 53:728-33.
12. Lehman GA, Sherman S. Diagnosis and therapy of pancreas divisum. *Gastrointest Endosc Clin N Am* 1998; 8:55-77.

SINGAPORE MEDICAL COUNCIL CATEGORY 3B CME PROGRAMME
Multiple Choice Questions (Code SMJ 200811B)

	True	False
Question 1. Pancreas divisum is:		
(a) A common congenital variant of the pancreatic anatomy.	<input type="checkbox"/>	<input type="checkbox"/>
(b) A rare form of annular pancreas.	<input type="checkbox"/>	<input type="checkbox"/>
(c) Mainly asymptomatic.	<input type="checkbox"/>	<input type="checkbox"/>
(d) Found rarely in patients with unexplained pancreatitis.	<input type="checkbox"/>	<input type="checkbox"/>
Question 2. The following statements about pancreas divisum are true:		
(a) It occurs when the ductal systems of the ventral and dorsal pancreatic ducts fail to fuse during foetal development.	<input type="checkbox"/>	<input type="checkbox"/>
(b) It is characterised typically by intraluminal filling defects of the pancreatic duct in MRCP.	<input type="checkbox"/>	<input type="checkbox"/>
(c) It is associated with the presence of choledochal cysts.	<input type="checkbox"/>	<input type="checkbox"/>
(d) It is associated with cystic pancreatic neoplasm.	<input type="checkbox"/>	<input type="checkbox"/>
Question 3. Regarding the recurrent attacks of pancreatitis in the presence of pancreas divisum:		
(a) They occur more commonly in people with pancreas divisum than in the general population.	<input type="checkbox"/>	<input type="checkbox"/>
(b) Mucinous pancreatic neoplasms are the predisposing notorious factor.	<input type="checkbox"/>	<input type="checkbox"/>
(c) Recurrent episodes may be caused due to the presence of relative obstruction to the drainage of pancreatic secretions at the minor papilla.	<input type="checkbox"/>	<input type="checkbox"/>
(d) Minor papilla sphincterotomy is the treatment.	<input type="checkbox"/>	<input type="checkbox"/>
Question 4. Regarding pancreas divisum:		
(a) Stenosis of the accessory papilla never occurs in cases of pancreas divisum.	<input type="checkbox"/>	<input type="checkbox"/>
(b) No further therapy should be systematically proposed for patients with pancreas divisum.	<input type="checkbox"/>	<input type="checkbox"/>
(c) Stress MRCP can reveal dilation of the duct of Santorini and a cystic dilation of the dorsal duct just before its insertion into the minor papilla in patients with pancreatic divisum.	<input type="checkbox"/>	<input type="checkbox"/>
(d) Endoscopic retrograde pancreatography can be used to make a definitive diagnosis of pancreas divisum.	<input type="checkbox"/>	<input type="checkbox"/>
Question 5. Parameters that can be assessed before and after administration of secretin in MRCP include the following:		
(a) Complete ductal anatomy with presence or absence of pancreas divisum.	<input type="checkbox"/>	<input type="checkbox"/>
(b) Classification of pancreas divisum.	<input type="checkbox"/>	<input type="checkbox"/>
(c) Visualisation of side pancreatic branches.	<input type="checkbox"/>	<input type="checkbox"/>
(d) Ampullary dysfunction.	<input type="checkbox"/>	<input type="checkbox"/>

Doctor's particulars:

Name in full: _____

MCR number: _____ Specialty: _____

Email address: _____

SUBMISSION INSTRUCTIONS:

(1) Log on at the SMJ website: <http://www.sma.org.sg/cme/smj> and select the appropriate set of questions. (2) Select your answers and provide your name, email address and MCR number. Click on "Submit answers" to submit.

RESULTS:

(1) Answers will be published in the SMJ January 2009 issue. (2) The MCR numbers of successful candidates will be posted online at www.sma.org.sg/cme/smj by 15 January 2009. (3) All online submissions will receive an automatic email acknowledgment. (4) Passing mark is 60%. No mark will be deducted for incorrect answers. (5) The SMJ editorial office will submit the list of successful candidates to the Singapore Medical Council.

Deadline for submission: (November 2008 SMJ 3B CME programme): 12 noon, 25 December 2008.