

# Unusual complication of intravenous Subutex abuse: two cases of septic sacroiliitis

Yang S S Y, Lee K

## ABSTRACT

We report two unusual cases of septic sacroiliitis resulting from intravenous Subutex abuse that initially masqueraded as low back pain. Both patients, a 48-year-old Malay man and a 30-year-old Malay woman, presented with chills, rigor and progressive lower back pain, and eventually experienced difficulty in ambulating. The Malay woman also developed severe pain in her left elbow, with swelling and restriction of movement. Blood investigations and cultures revealed an infective process. Imaging of the pelvis and lower back confirmed the diagnosis of septic arthritis of the sacroiliac joints. The first patient underwent computed tomography-guided drainage of the abscess and was administered intravenous antibiotics via a peripherally-inserted central catheter (PICC) line. The second patient underwent an arthrotomy for her elbow and her left sacroiliac joint was managed conservatively with intravenous antibiotics, also via a PICC line. The diagnostic difficulty and the need for a high index of suspicion are discussed.

**Keywords:** buprenorphine intravenous drug abuse, sacroiliitis, septic sacroiliitis, Subutex

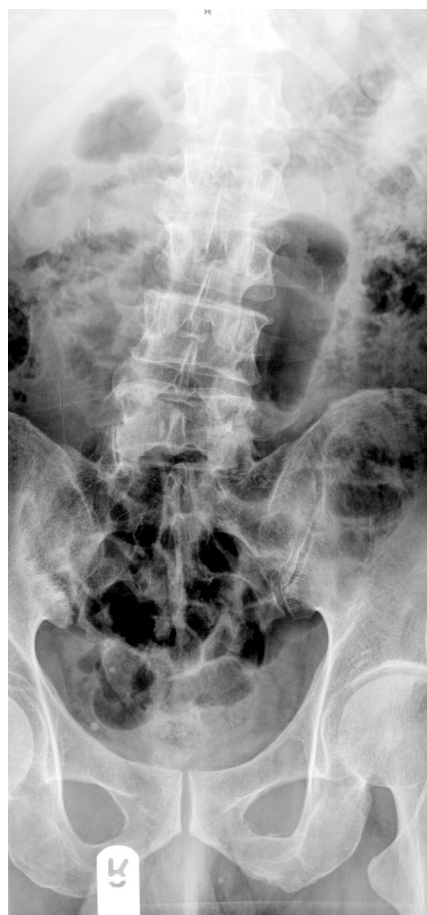*Singapore Med J 2008; 49(12):e343-e346*

## INTRODUCTION

Sacroiliitis is difficult to diagnose and is often mistaken for other more common causes of back pain, such as sciatica, herniated disc or muscle strain. It is normally associated with spondyloarthropathies and other inflammatory processes. Trauma, pregnancy, infections of the skin, osteomyelitis, urinary tract infection, and endocarditis are also potential causes. It is also seen with some frequency in intravenous drug users. Patients often present with a sudden onset of fever, pain and decreased range of motion. These symptoms are vague and lend to its diagnostic difficulty.

Subutex, or buprenorphine, was introduced into Singapore in 2002. It is a partial opioids agonist and

is meant to be administered sublingually. However, in 2005, news broke of addicts creating a new drug cocktail of Subutex crushed together with Dormicum (benzodiazepine) and administering it intravenously. Singaporean drug users had thus devised a method to abuse an otherwise extremely effective drug in the treatment of heroin withdrawal symptoms.<sup>(1)</sup> As a result, Subutex became a Class A controlled drug, which subjects traffickers and illegal dealers to 20 years in jail and 15 strokes of the cane. Addicts were given a two-week window to sign up for a voluntary rehabilitation programme in which they were weaned of the drug in a controlled environment.



**Fig. 1** Initial anterior-posterior radiograph of the first patient.

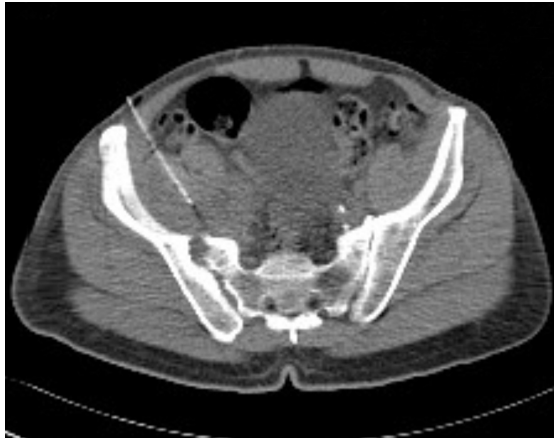Yong Loo Lin  
School of Medicine,  
National University  
of Singapore,  
10 Medical Drive,  
Singapore 117597

Yang SSY  
Medical Student

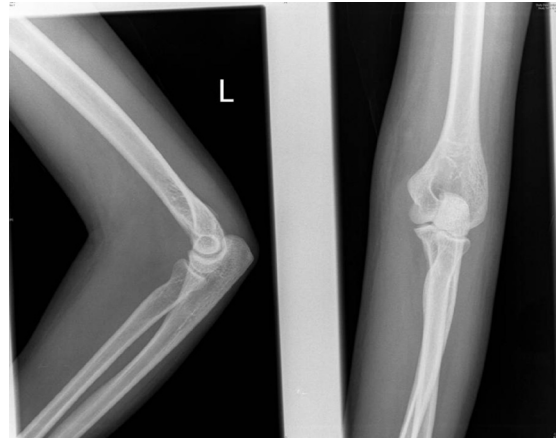Department of  
Orthopaedic  
Surgery,  
National University  
Hospital,  
5 Lower Kent Ridge  
Road,  
Singapore 119074

Lee K, MBBS,  
MRCSE, FRCSE  
Consultant

**Correspondence to:**  
Mr Sam Yang Shiyao  
Tel: (65) 9793 3964  
Fax: (65) 6448 2821  
Email: alpheus\_  
babinski@yahoo.com



**Fig. 2** CT-guided drainage of the right sacroiliac joint of the first patient.



**Fig. 3** Radiographs of the left elbow of the second patient.

## CASE REPORTS

Two patients with a history of intravenous Subutex abuse, particularly in the antecubital and femoral regions, presented with progressive lower back pain of such severity that they could no longer self-ambulate.

### Case 1

The first patient was a 48-year-old Malay man who gave a history of pain which began acutely in the morning, described to be worse under the ischium and to radiate down the back of the thigh towards the knee. While he was able to ambulate over short distances, walking exacerbated the pain. The pain was characterised as sharp and “poking”. On admission, the patient was febrile, with a temperature ranging from 38°C to 39°C. Needle marks were noted over both antecubital and femoral regions. The range of motion of his right hip was severely limited to 20° of flexion due to pain. Power, sensation and pulses were normal distally. Right lower paravertebral spasm was noted, and tenderness was elicited over the right dimple of Venus – just superficial to the sacroiliac joint.

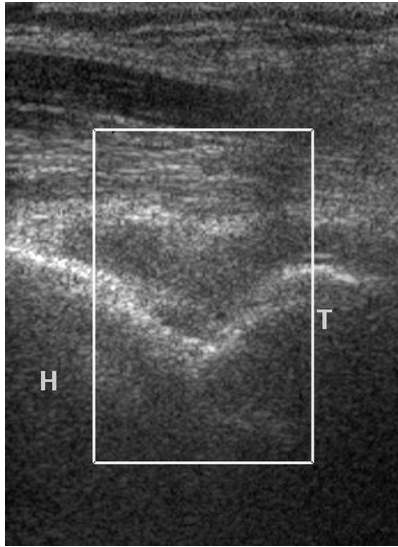
Blood investigations revealed leucocytosis at  $14.6 \times 10^9/L$ , together with an elevated differential count of neutrophils. C-reactive protein (CRP) and erythrocyte sedimentation rate (ESR) were also elevated. The blood culture grew *Staphylococcus aureus*. Initial radiographs of the pelvis showed bony changes and involvement of the right sacroiliac joint (Fig. 1). A peripherally-inserted central catheter line was inserted to administer intravenous cloxacillin. Magnetic resonance (MR) imaging was then performed, revealing septic arthritis of the sacroiliac joint, with extension into the adjacent sacral ala and iliac wing. A large intrapelvic abscess within and displacing the right iliacus muscle extended deep into the pelvis and exited via the right sacral foramina.

The patient then underwent a computed tomography (CT)-guided drainage (Fig. 2). Pus culture revealed *Staphylococcus aureus* sensitive to amoxicillin. After the procedure, he improved and began to ambulate better. His fever subsided and oral antibiotic treatment was implemented, consisting of flucloxacillin and ciprofloxacin for six weeks. He was discharged with pain medication. At the one-month follow-up, the patient’s total white blood cell (WBC) count was  $9.8 \times 10^9/L$ , ESR was 7 mm/hr and his CRP was  $< 5$  mg/dL. Radiographs of the lumbar spine was unremarkable, and CT of the abdomen and pelvis revealed resolution of the previous abscess. Ultrasonography of the right hip did not reveal any effusion.

### Case 2

The second patient was a 30-year-old Malay woman who presented with the same complaints as the first patient. She was also febrile on admission, and pattern needle mark characteristics, similar to those of first patient, were noticed. She experienced severe restriction of movement of her left hip, and tenderness elicited over her left lower back. Her left elbow was swollen, erythematous and tender. Her range of movement was severely restricted.

Her blood investigations revealed leucocytosis at  $19.4 \times 10^9/L$ . As with the first patient, she had an elevated differential count of neutrophils, CRP and ESR. A culture of her blood revealed *Streptococcus agalactia* and *Bacillus cereus* in addition to *Staphylococcus aureus*. Radiographs of the left elbow showed elevation of the posterior fat pad, in keeping with an elbow joint effusion with respect to the clinical context of septic arthritis (Fig. 3). She also underwent ultrasonography of the left elbow, which showed prominent joint effusion with synovial thickening (Fig. 4). No hypervascularity was noted on colour Doppler examination. In addition,



**Fig. 4** Ultrasonographical image of the left elbow of the second patient.

she underwent MR imaging to investigate her lower back pain. The gadolinium-enhanced MR imaging revealed abnormal enhancement of the left sacroiliac joint and the adjacent ilium. This was typical of early septic arthritis.

This patient then underwent an arthrotomy and washout of her septic left elbow. The septic sacroiliitis was initially treated with intravenous gentamycin for two weeks, followed by cloxacillin for six weeks. However, a peripheral blood smear revealed cloxacillin-induced anisocytosis, polychromasia, spherocytes and target cells. As she had developed autoimmune haemolytic anaemia, her antibiotic regime had to be changed to gentamycin and vancomycin. She was well and afebrile on discharge. Repeat blood tests on follow-up showed a declining WBC count, CRP and ESR, indicating a resolution of the infection.

## DISCUSSION

The increasing number of cases of Subutex abuse had led to the drug being banned, and there is considerable documentation on the dangerous orthopaedic complications which arise from the abuser self-administering the drug parenterally instead of its proper sublingual route.<sup>(2)</sup> This improper method of Subutex administration is known to cause surgical complications, such as skin infections, limb abscess and limb gangrene.<sup>(3,4)</sup> Ischaemia, septic arthritis, necrotising fasciitis and arterial aneurysms are also known to develop and further cause infection and vascular complications, especially in the peripheries when certain injection sites are used.<sup>(2,4,5)</sup> Medical complications such as bacterial endocarditis are also feared, particularly for intravenous drug abusers. Surgical complications are treated by

excision, debridement, and repair.<sup>(4)</sup> Anticoagulants and vasodilators are also used to treat ischaemia (vascular complications) when it occurs. In general, these treatment measures result in a poor outcome.<sup>(2)</sup>

For septic arthritis, the spectrum of causative organisms are wide. *Staphylococcus aureus* and Streptococci are responsible for 74% of the occurrences of septic arthritis. Septic arthritis is associated with a significant mortality at 11.5% with an additional significant morbidity of 31.6%.<sup>(6)</sup> Age, diabetes mellitus, rheumatoid arthritis, joint surgery, hip or knee prosthesis, skin infection, and human immunodeficiency virus type 1 infection significantly increase the probability of septic arthritis occurrence.<sup>(7)</sup> Early diagnosis of septic arthritis is of great importance as it would reduce morbidity and improve treatment outcome. Joint pain, swelling and fever occur in more than 50% of patients as bacteria seeds the synovium and readily enters the joint space. An intense inflammatory reaction follows with infiltration of polymorphonuclear leucocytes, resulting in proteolytic enzyme release and subsequent destruction of articular cartilage.

The two most important laboratory tests are the synovial fluid WBC count and percentage of polymorphonuclear cells from arthrocentesis.<sup>(7)</sup> Treatment will involve intravenous followed by oral antibiotics. Sensitivity testing is important, especially for cultures showing *Staphylococcus aureus*, as antibiotic resistance is common. The mainstay of treatment of septic arthritis is regular aspirations, surgical drainage or arthrotomy.<sup>(8,9)</sup> However, in certain situations where access to the joint is difficult, more conservative options like intravenous antibiotic therapy or CT-guided drainage are chosen.<sup>(10)</sup> With prompt treatment, clinical improvement is expected.

As shown in the above cases, intravenous drug abuse is also a cause of septic arthritis. The patients admitted to using unclean needles while injecting into the groin and probably missed the femoral vein. Other upper limb veins were sclerosed, resulting in difficulty setting up intravenous access. Most patients with sacroiliitis present with lower back pain, buttock pain and difficulty in walking.<sup>(11)</sup> Herein lies the difficulty in diagnosis: many conditions present in a similar fashion. Moreover, as sacroiliitis is relatively uncommon, accurate diagnosis is frequently delayed due to lack of awareness by clinicians and nonspecific clinical presentation.

Radiological investigations are largely required as it can be very difficult to diagnose infection from other causes of lower back pain, like pelvic inflammatory disease and other spondyloarthropathies. MR imaging is the most sensitive method for diagnosis, superior to

quantitative sacroiliac scintigraphy or conventional radiography for the detection and confirmation of active sacroiliitis.<sup>(12)</sup> A delayed diagnosis and failure to commence appropriate treatment promptly result in the late complications of abscess formation, septicaemia, joint contractures and stiffness, and late instability with joint subluxation and dislocation.<sup>(13)</sup> In summary, the early diagnosis and prompt management of septic sacroiliitis from intravenous Subutex abuse requires a high index of suspicion.

## REFERENCES

1. Feillin DA, Kleber H, Trumble-Hejdut JG, McLellan AT, Kosten TR. Consensus statement on office-based treatment of opioid dependence using buprenorphine. *J Subst Abuse Treat* 2004; 27:153-9.
2. Loo HW, Yam AKT, Tan TC, Peng YP, Teoh LC. Severe upper limb complications from parenteral abuse of Subutex®. *Ann Acad Med Singapore* 2005; 34:575-8.
3. Lo HY, Leong CSL. Surgical complications in parenteral Subutex abusers. *Singapore Med J* 2006; 47:924-7.
4. Del Giudice P, Vandenbos F, Boissy C, et al. Cutaneous complications of direct intra-arterial injections in drug addicts. *Acta Derm Venereol* 2005; 85:451-2.
5. Yeo AKS, Chan CY, Chia KH. Complications relating to intravenous buprenorphine abuse: a single institution case series. *Ann Acad Med Singapore* 2006; 35:487-91.
6. Weston VC, Jones AC, Bradbury N, Fawthrop F, Doherty M. Clinical features and outcome of septic arthritis in a single UK Health District 1982-1991. *Ann Rheum Dis* 1999; 58:214-9.
7. Margaretten ME, Kohlwes J, Moore D, Bent S. Does this adult patient have septic arthritis? *JAMA* 2007; 297:1478-88.
8. Youssef PP, York JR. Septic arthritis: a second decade of experience. *Aust N Z J Med*. 1994; 24:307-11.
9. Donatto KC. Orthopedic management of septic arthritis. *Rheum Dis Clin North Am* 1998; 24:275-86.
10. Doita M, Yoshiya S, Nabeshima Y, et al. Acute pyogenic sacroiliitis without predisposing conditions. *Spine* 2003; 28:E384-9.
11. Osman AA, Govender S. Septic sacroiliitis. *Clin Orthop Relat Res* 1995; 313:214-9.
12. Blum U, Buitrago-Tellez C, Munding A, et al. Magnetic resonance imaging (MRI) for detection of active sacroiliitis - a prospective study comparing conventional radiography, scintigraphy, and contrast enhanced MRI. *J Rheumatol* 1996; 23:2107-15.
13. Millar TM, McGrath P, McConnachie CC. Polyarticular septic arthritis following septic circumcision. *Rural Remote Health* 2007; 7:659.