

Acute renal failure following the use of rosiglitazone in a chronic kidney disease patient

Abdul Ghani R, Zainudin S, Kamaruddin N A, Kong N C T

ABSTRACT

Drug-induced acute interstitial nephritis is a well-recognised and important reversible cause of acute renal failure. Peroxisome-proliferator activated receptor-gamma agonists, such as rosiglitazone, have been proven to be safe in chronic kidney disease patients. We describe a 65-year-old man with long-standing diabetes mellitus and hypertension, presenting with a five-day history of fluid overload and uraemic symptoms. There was no ingestion of analgesics, alternative medicine and other nephrotoxic drugs, the only new prescription being rosiglitazone, which was commenced during his last clinic follow-up two weeks prior to presentation. He required haemodialysis with minimal improvement in renal profile, despite cessation of the offending drug. Renal biopsy revealed findings consistent with acute interstitial nephritis. An episode of upper gastrointestinal bleeding with bleeding duodenal ulcer limited the use of steroids. He was treated with a course of mycophenolate mofetil which showed good gradual response and he remained stable with residual renal impairment.

Keywords: acute interstitial nephritis, acute renal failure, mycophenolate mofetil, peroxisome-proliferator activated receptor-gamma, rosiglitazone, thiazolidinediones

Singapore Med J 2009; 50(1): e32-e34

INTRODUCTION

Drug-induced acute interstitial nephritis (AIN) is an important reversible cause of acute renal failure. Numerous drugs have been implicated as the offensive agents, the commonest being non-steroidal anti-inflammatory drugs (NSAIDs), angiotensin-converting-enzyme inhibitors and angiotensin-receptor blockers. Because of their insulin-sensitising properties, activators of peroxisome-proliferator activated receptor-gamma (PPAR γ), i.e. thiazolidinediones, are widely used in the treatment of type 2 diabetes mellitus. These include agents such as rosiglitazone and pioglitazone, which are confidently used in patients with chronic kidney disease.

CASE REPORT

A 65-year-old man with long-standing diabetes mellitus and hypertension presented to the emergency department with a short history of progressive shortness of breath five days prior to admission. This was associated with orthopnoea, reduced effort tolerance, oliguria, uraemic symptoms of nausea and vomiting, and loss of appetite. There was no recent history of fever or other constitutional symptoms. He denied taking any traditional or alternative medicine and was not prescribed any NSAIDs. He had diabetes mellitus and hypertension of 15 years' duration, complicated by erectile dysfunction, background retinopathy and diabetic nephropathy with a stable baseline creatinine of 130–150 $\mu\text{mol/L}$ over the last few years. He had hyperlipidaemia and infrequent attacks of gout. He was otherwise well, with no previous hospital admissions. He jogged regularly, was a non-smoker and a teetotaler. There was no drug allergy and his medications included metformin 850 mg daily, acarbose 100 mg thrice daily, gliclazide modified release 90 mg daily, co-aprovel (300 mg/12.5 mg) 1 tablet daily, amlodipine 10 mg daily, prazosin 2 mg daily, fenofibrate 160 mg daily and allopurinol 300 mg daily, all of which had been continued without any change in dosage for the past two years with good compliance. He was seen in the endocrine clinic two weeks prior to admission during which he had complained of increasing intolerance to acarbose due to a feeling of bloatedness, and admitted to intermittently omitting the drug. This was subsequently ceased and rosiglitazone was commenced at a daily dose of 4 mg.

On admission, he was mildly dyspnoeic, pale and shallow. He was afebrile, with a blood pressure of 160/75 mmHg and pulse rate of 72 beats/min. There was evidence of fluid overload with raised jugular venous pressure, displaced apex beat, bibasal crepitations and bilateral leg oedema. Biochemical investigations revealed acute renal failure with serum urea of 31.9 mmol/L and creatinine of 1,474 $\mu\text{mol/L}$. There was metabolic acidosis with serum pH of 7.243 and bicarbonate of 12.4 mmol/L. He had evidence of both microscopic haematuria and proteinuria, with a urine protein/creatinine index of 0.36. There was no eosinophilia or eosinophiluria. Serum albumin was normal with low sodium and high

Department of
Medicine,
Faculty of Medicine,
Universiti Kebangsaan
Malaysia,
Jalan Yaacob Latiff,
Cheras,
Kuala Lumpur 56000,
Malaysia

Abdul Ghani R,
MBBCh, BAO, MMed
Clinical Specialist

Zainudin S, MD,
MMed, MRCP
Consultant
Nephrologist

Kamaruddin NA,
MBBS, MMed
Consultant
Endocrinologist

Kong NCT, FRACP,
FRCPE, FASN
Consultant
Nephrologist

Correspondence to:
Dr Rohana Abdul Ghani
Tropicana Medical
Centre,
Kota Damansara,
Petaling Jaya 47810,
Malaysia
Tel: (60) 3 6287 1111
Fax: (60) 3 6287 1212
Email: agrohana@gmail.com

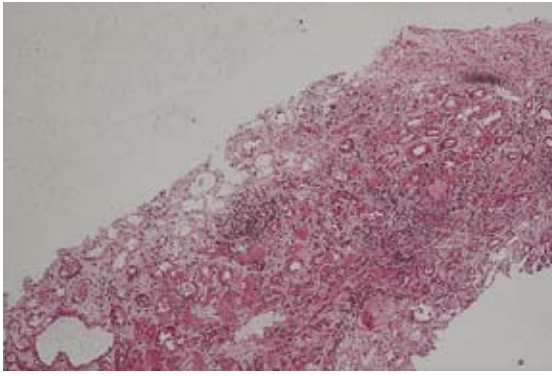


Fig. 1 Low power photomicrograph shows renal cortical tissue diffusely infiltrated by inflammatory cells (Haematoxylin & eosin, x 20).

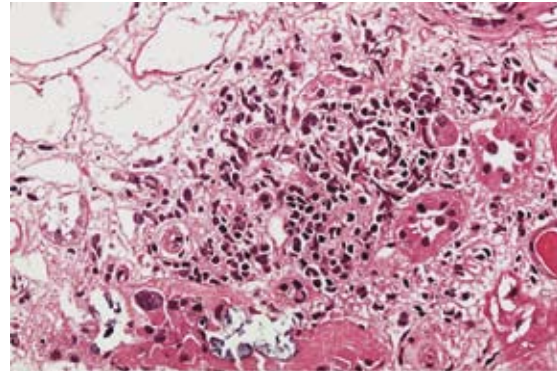


Fig. 2 High power photomicrograph shows that most of the inflammatory infiltrates are lymphocytes and occasional eosinophils (Haematoxylin & eosin, x 100).

potassium of 116 and 5.7 mmol/L, respectively. He was anaemic with a haemoglobin level of 10.2 g/dL, moderate dyslipidaemia and glycaemic control below target with an A1c of 8.1%. Blood culture, urine culture and myoglobin showed negative results. Other investigations included normal liver profile, cardiac enzymes and serum creatinine kinase. His electrocardiogram showed mild left ventricular hypertrophy, which was consistent with his echocardiography. Various serology tests including cytomegalovirus, Epstein-Barr virus and hepatitis B and C screening were negative. Unfortunately, a toxicology screen to identify any plausible cause of an offending toxin was not available to us. Ultrasonography of the abdomen revealed no evidence of obstruction or renal stones, with normal kidney size and echogenicity.

All his oral diabetic medications were promptly ceased and he underwent haemodialysis. Renal biopsy was performed shortly after. Histopathological examination revealed expanded interstitium with separation of tubules by oedema and inflammatory infiltrations consisting of lymphocytes, plasma cells and eosinophils, consistent with AIN (Figs. 1 & 2). He subsequently developed an episode of upper gastrointestinal bleeding three days after admission, and an oesophagogastroduodenoscopy (OGDS) revealed a large bleeding duodenal ulcer. When this procedure was repeated three days later, a healed ulcer was seen. In view of this, the use of steroids was avoided to prevent any further bleeding. Mycophenolate mofetil (MMF) was commenced at a dose of 500 mg twice daily in the absence of steroids. After six weeks of MMF therapy, there was gradual improvement in the renal function and he had a fairly good urine output. Serum creatinine gradually declined from 1,474 $\mu\text{mol/L}$, and stabilised at 300–314 $\mu\text{mol/L}$ on MMF therapy (Fig. 3). Two months later in a clinic follow-up, he remained asymptomatic, vital signs were stable with three oral anti-hypertensives: felodipine 10 mg once daily, atenolol 25 mg daily and minoxidil 5 mg nocte. He maintained good glycaemic control only with short acting insulin premeals, and serum creatinine remained stable at 300 $\mu\text{mol/L}$.

DISCUSSION

PPAR γ agonists, i.e. thiazolidinediones, have recently received a tremendous amount of attention, showing promising results in the prevention of diabetes mellitus, delaying the progression of diabetes mellitus and reducing cardiovascular complications.⁽¹⁻⁵⁾ They are currently being taken by millions of diabetic patients throughout the world. Thiazolidinediones were introduced in the mid-1990s. However, the unacceptable risk of fulminant hepatic failure had resulted in removal of the earlier thiazolidinedione, troglitazone, from the world market. The latter two, rosiglitazone and pioglitazone, were subsequently received with much caution.

Our patient developed acute renal failure with rosiglitazone. Prior to this, there has only been one reported case of rosiglitazone causing AIN.⁽⁶⁾ PPAR-receptors are ligand-activated nuclear transcription factors that modulate gene expression, acting mainly by increasing insulin sensitivity in peripheral tissues.⁽⁷⁾ Notably, the abundant PPAR-receptors in tissues such as monocytes, macrophages, colonic epithelial cells, pituitary cells, vascular smooth muscle and endothelial cells, as well as renal glomerular and tubular cells, suggest the probable long-term benefits or adverse effects of thiazolidinediones.⁽⁸⁾ This case ironically contradicts recent data which had demonstrated the beneficial effects of thiazolidinediones beyond that of glycaemic control, with the reduction in urinary albumin excretion and albumin-creatinine ratio with further suggestion of a renoprotective role of thiazolidinediones being of particular interest.^(9,10) Thus, we could only hypothesise that the renal insult in our patient may have been an idiosyncratic effect. The two main side effects currently associated with the use of thiazolidinediones are weight gain and fluid retention, both of which subside when the drugs are ceased. Peripheral oedema and congestive heart failure can occur in 3–5% and 1% of patients using thiazolidinediones, respectively, particularly in combination with another glucose-lowering agent, mainly insulin.⁽⁹⁾ A recent meta-

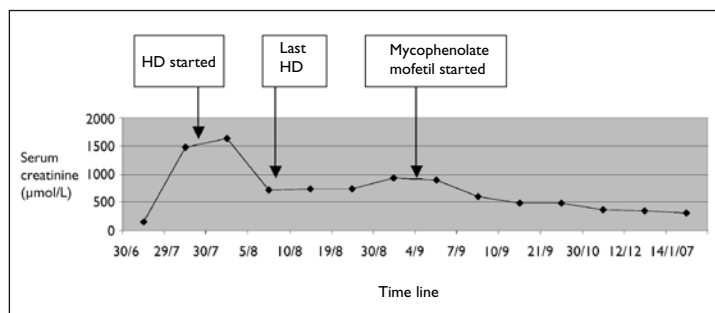


Fig. 3 Line graph shows the gradual decline of serum creatinine ($\mu\text{mol/L}$).

analysis associating rosiglitazone and an increased risk in myocardial infarction with cardiovascular deaths had certainly added further concern to the adverse effects of this drug.⁽⁹⁾ However, thiazolidinediones are generally benign to the kidney, the only main concern being fluid retention in oliguric patients. In fact, its use in chronic kidney disease, including patients on haemodialysis, had been proven to be safe as the excretion of the drug is not dependant on kidney function.⁽¹⁰⁾

AIN classically presents as acute renal failure after the use of known offending drugs, and is associated with the typical urinary findings of pyuria, haematuria and white cell casts.⁽¹¹⁾ Prognosis is good and the majority do recover, although persistent elevation of the serum creatinine may develop in up to 40% of cases.⁽¹¹⁾ Thus, this case highlighted a resistant patient with persistently-elevated serum creatinine despite cessation of the offending drug, in contrast to the previously-reported case who showed prompt recovery after only two weeks of cessation of rosiglitazone and did not require haemodialysis.⁽⁶⁾ The bleeding peptic ulcer could have contributed to further elevation of serum urea and creatinine. However, a repeat OGDS performed three days after the initial acute episode showed cessation of the bleeding and a healed ulcer, which should have led to a rapid decline in both levels but did not occur in this patient. AIN has been postulated to occur through numerous mechanisms, the most convincing being an immune-mediated response. Immunosuppressive therapies, such as corticosteroids, have been used to treat AIN that persists beyond two to three weeks of discontinuation of the offending drug, which demonstrated improvement in kidney functions.⁽¹¹⁾ However, there are no randomised controlled trials conducted to date. A steroid was used in the previous case,⁽⁶⁾ but due to the recent upper gastrointestinal bleed in our patient and the presence of a large bleeding duodenal ulcer, this treatment was considered to be risky. Another immunosuppressive agent, MMF, was subsequently administered, which has been proven to be potentially useful as an alternative therapy in AIN; however, again, current data is limited.⁽¹²⁾ The patient showed a fairly good gradual response with stabilisation

of serum creatinine, although he failed to return to his pre-morbid level.

To our knowledge, this is only the second case of rosiglitazone-induced AIN in the literature, a potential complication affecting the increasing number of patients on PPAR-agonists, particularly rosiglitazone. It also illustrated a therapeutically difficult case of resistant AIN, the limitations of steroid use, and the success of MMF in restoring renal function to partial normality.

ACKNOWLEDGEMENTS

We would like to thank the Dean of the Faculty of Medicine for allowing us to report this new and interesting complication. A special thanks to all the staff, particularly from the Nephrology and Endocrinology Units, who were involved in the management of this patient.

REFERENCES

- DREAM (Diabetes REduction Assessment with ramipril and rosiglitazone Medication) Trial Investigators, Gerstein HC, Yusuf S, et al. Effect of rosiglitazone on the frequency of diabetes in patients with impaired glucose tolerance or impaired fasting glucose: a randomised controlled trial. *Lancet* 2006; 368:1096-105.
- Azen SP, Peters RK, Berkowitz K, et al. TRIPOD (TROglitazone In the Prevention Of Diabetes): a randomized, placebo-controlled trial of troglitazone in women with prior gestational diabetes mellitus. *Control Clin Trials* 1998; 19:217-31.
- Xiang AH, Peters RK, Kjos SL, et al. Continued protection from diabetes during treatment of the TRIPOD Cohort with pioglitazone. In: New Orleans, LA: Proceedings of the 63rd Annual Meeting of the American Diabetes Association; 2003 June 13-17. Abstract 322-OR.
- Viberti G, Kahn SE, Greene DA, et al. A diabetes outcome progression trial (ADOPT): an international multicenter study of the comparative efficacy of rosiglitazone, glyburide, and metformin in recently diagnosed type 2 diabetes. *Diabetes Care* 2002; 25:1737-43.
- Dormandy J, Charbonnel B, Eckland DJ, et al. Secondary prevention of macrovascular events in patients with type 2 diabetes in the PROactive Study (PROspective pioglitazone Clinical Trial in macroVascular Events): a randomised controlled trial. *Lancet* 2005; 366:1279-89.
- Castledine C, Wright D, Kingdon E. Rosiglitazone as a cause of acute interstitial nephritis. *Nephrol Dial Transplant* 2006; 21:1994-5.
- Nissen SE, Wolski K. Effect of rosiglitazone on the risk of myocardial infarction and death from cardiovascular causes. *N Engl J Med* 2007; 356:1-15.
- Cheng AYY, Fantus IG. Oral antihyperglycemic therapy for type 2 diabetes mellitus. *CMAJ* 2005; 172:213-26.
- Calkin AC, Allen TJ. Diabetes mellitus-associated atherosclerosis. Mechanisms involved and potential for pharmacological intervention. *Am J Cardiovasc Drugs* 2006; 6:15-40.
- Scherntzner G. Kidney disease in diabetology. *Nephrol Dial Transplant* 2007; 22:703-7.
- Rosert J. Drug-induced acute interstitial nephritis. *Kidney Int* 2001; 60:804-17.
- Preddie DC, Markowitz GS, Radhakrishnan J, et al. Mycophenolate mofetil for the treatment of interstitial nephritis. *Clin J Am Soc Nephrol* 2006; 1:718-22.