

Prolonged foreign body impaction in the oesophagus

Rathore P K, Raj A, Sayal A, Meher R, Gupta B, Girhotra M

ABSTRACT

It is not unusual for a foreign body to be swallowed and become lodged in the oesophagus. It is, however, very unusual for such a foreign body to remain lodged for a period of six months. This particular case, a 37-year-old man, is interesting because of the length of time the foreign body, a denture, remained in the oesophagus without complications, its successful removal and the nature of the foreign body, which is prone to cause complications on prolonged stay or during removal.

Keywords: denture, foreign body, impacted foreign body, oesophagus

Singapore Med J 2009; 50(2): e53-e54

INTRODUCTION

Foreign bodies in the oesophagus are a common occurrence in children because of their innate curiosity, habitual insertion of objects into their mouths while playing and speaking, and the lack of posterior dentition. In the older age group, the commonest foreign body found is a denture, because of the decreased sensation of the oral cavity in denture wearers, a gradual loss of sensation and poor motor control of the laryngopharynx. This case is unique because of the duration for which the foreign body remained in the oesophagus without complications, its successful removal and the nature of the foreign body, which is prone to cause complications on prolonged stay or during removal.

CASE REPORT

A 37-year-old man presented to the ENT outpatient department of Lok Nayak Hospital with complaints of difficulty in swallowing for the past 2–3 days. On investigating his past history, it was revealed that the patient had suffered from similar acute onset complaints six months ago and was investigated, but nothing was found conclusively and therefore, the patient was kept on conservative management. The patient gradually recovered from his complaints within a week and was well until a few days prior to presentation when the symptoms recurred. There was no associated history of weight loss nor was there a history of respiratory distress, chest pain,⁽¹⁾ fever, vomiting or dark-coloured

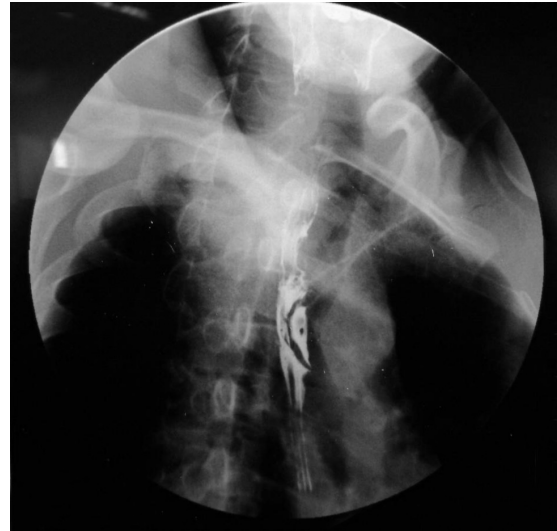

Fig. 1 Barium swallow shows an eccentric filling defect in the oesophagus at T2–T3 and T3–T4 levels.

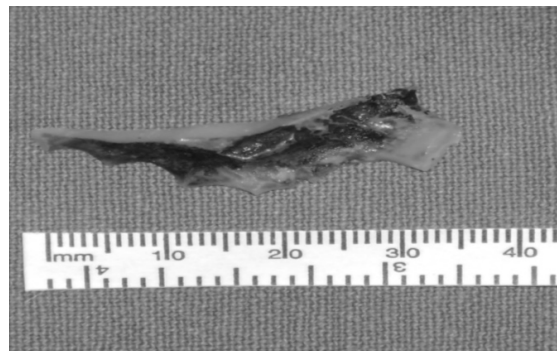


Fig. 2 Photograph shows the foreign body (partial denture) removed from the oesophagus.

stools. On per oral examination, an upper left lateral incisor was found to be missing. On questioning, the patient remembered having a denture at this site but had accidentally misplaced it six months ago.

All routine laboratory investigations were within normal limits. Chest radiograph was within normal limits and both lung fields were clear. Barium swallow (Fig. 1) showed an eccentric filling defect in the oesophagus at the T2–T3 and T3–T4 levels. The patient then had an endoscopy which showed an impacted foreign body in the oesophagus at 22 cm from the incisors. The patient was planned for its removal through rigid endoscopy. On rigid endoscopy, a foreign body was found at a distance of 22–24 cm from the incisors, with oedema and inflammation

Department of ENT and Head, Neck Surgery, MAM College and Lok Nayak Hospital, Bahadur Shah Zafar Marg, New Delhi 110002, India

Rathore PK, MBBS, MS
Professor

Raj A, MBBS, MS
Professor and Head

Sayal A, MBBS, MS
Resident

Meher R, MBBS, MS, DNB
Assistant Professor

Gupta B, MBBS, DLO, DNB
Senior Resident

Girhotra M, MBBS, MS
Senior Resident

Correspondence to:
Dr Ankush Sayal
Tel: (91) 99 1026 4564
Fax: (91) 11 2619 1663
Email: ankushsayal@yahoo.com

of the surrounding mucosa. It was removed by grasping firmly in a vertical position in order to avoid the risk of perforation. On examination, it was found to be a denture (Fig. 2). Postoperatively, the patient was relieved of the dysphagia and chest pain, and could accept both solids and liquid foods orally. He was discharged on the third day.

DISCUSSION

In the aged, the commonest foreign body found is dentures,⁽²⁾ because of a decreased sensation of the oral cavity in denture wearers, a gradual loss of sensations and poor motor control of the laryngopharynx. This case highlights the need for a high degree of suspicion as well as the importance of taking a detailed history and a good examination to detect foreign bodies.⁽³⁾ Initially, the foreign body (denture) was missed due to its radiolucent⁽⁴⁾ nature and being devoid of any wires and therefore could not be detected on routine chest radiograph.⁽⁵⁾ It is also interesting to find that the patient did not develop any complication,⁽⁶⁾ in spite of the foreign body being in the oesophagus for six months; during this period, the patient was swallowing well. It is likely that the impacted unwired dentures were less likely to cause perforations. Also, the foreign body was located longitudinally along the long axis of the oesophagus and this further reduced the chances of developing perforations and complications.

Precautions should be taken during the removal of such foreign bodies. Great care should be taken while inserting the rigid oesophagoscope, as there is a high

chance of causing perforations due to oedema of the surrounding oesophageal wall as a result of the long-standing foreign body. Also, such foreign bodies should be removed along their long axis with care taken if they have wires attached to them.⁽⁷⁾ All cases of a foreign body in the oesophagus should be started on intravenous antibiotics and steroids. In cases of radiolucent foreign bodies, it must be kept in mind that as these are not detected on routine radiographs, they can be missed and a high degree of suspicion should be maintained when dealing with such cases. It should also be remembered that dentures without wires can stay in the oesophagus without causing complications for long periods of time. Dentures should therefore be made of radiopaque material and supported well with metal wires.⁽⁸⁾

REFERENCES

1. Koyuncu N, Yilmaz S, Soysal S. An unusual cause of chest pain: foreign body in the oesophagus. *Emerg Med J* 2007; 24:e1.
2. Singh B, Puri ND, Kakar PK. A fatal denture in the oesophagus. *J Laryngol Otol* 1978; 92:829-31.
3. Lerner SS. Unusual foreign body in the esophagus. *Laryngoscope* 1961; 71:434-5.
4. Firth AL, Moor J, Goodyear PW, Strachan DR. Dentures may be radiolucent. *Emerg Med J* 2003; 20:562-3.
5. Goh YH, Tan NG. Radiological features of unusual ingested foreign bodies. *Singapore Med J* 2001; 42:129-30.
6. Gerwat J. An unusual case of foreign body perforation of the oesophagus. *J Laryngol Otol* 1973; 87:423-6.
7. Chadha SK, Gopalakrishnan S, Gopinath N. An unusual sharp foreign body in the esophagus and its removal. *Otolaryngol Head Neck Surg* 2003; 128:766-8.
8. Cottrell SG, Hanley JM. Swallowed partial denture: a case report. *Gen Dent* 2001; 49:384-5.