

Carotid body tumours: three case reports

Mathew B K, Bandgar T, Menon P S, Shah N S

ABSTRACT

A carotid body tumour is a rare presentation of an extra-adrenal pheochromocytoma. They commonly present with asymptomatic neck masses, and careful preoperative evaluation is required to find out the functional and vascular status of these tumours. We report three cases of carotid body paraganglioma, their evaluation, management and the final outcome.

Keywords: carotid body paraganglioma, carotid body tumour, paraganglioma, pheochromocytoma

Singapore Med J 2009;50(2):e58-e60

INTRODUCTION

Paraganglioma (PGL) is a rare tumour of the head and neck, which arises from the neural crest cells.⁽¹⁾ Histopathologically similar to the adrenal gland neoplasm (pheochromocytoma), it is usually benign and non-functional. It grows and expands slowly and rarely metastasises.^(2,3) Since the paraganglionic cells contain very small amounts of catecholamines, clinically-significant catecholamine release is rare.⁽¹⁾ Carotid body tumour (CBT) is the most common form of PGL of the head and neck region.⁽³⁾

CASE REPORTS

Case 1

A 60-year-old non-diabetic, non-hypertensive man presented with hoarseness of voice and right-sided ptosis of six months' duration. He had a swelling in the angle of the right jaw, which had progressively been increasing in size over the past 20 years. A family history of PGL was negative. On examination, there was a 3 cm × 3 cm pulsatile mass in the upper third of the right sternocleidomastoid, which was mobile laterally and not vertically, without an audible bruit. Right-sided Horner's syndrome and recurrent laryngeal nerve palsy were present. Doppler ultrasonography showed a highly vascular mass at the bifurcation of the common carotid artery. Magnetic resonance (MR) imaging showed a 3 cm × 3 cm × 3 cm mass in the right carotid space, with multiple flow voids with splaying of carotid bifurcation, with intense enhancement on T2-weighted images suggestive of a CBT. 24-hour urinary

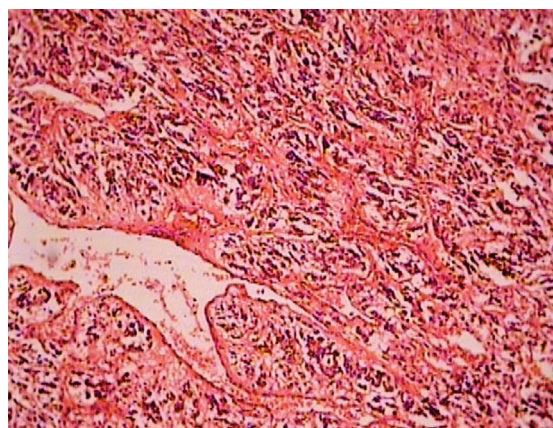


Fig. 1 Photomicrograph shows features of a carotid body tumour (Haematoxylin & eosin, × 100).

metanephrines (MN) and vanillylmandelic acid (VMA) were elevated and ¹³¹I meta-iodobenzylguanidine (¹³¹I-MIBG) scintigraphy showed uptake at the tumour site. The patient underwent successful surgical resection of the tumour after preoperative alpha blockade for two weeks. Postoperatively, he recovered from Horner's syndrome, showed improvement in hoarseness and is followed-up annually with urinary MN and MR imaging of the tumour bed. Histopathology was consistent with PGL (Fig. 1).

Case 2

An 18-year-old boy presented with a mass in the angle of the right jaw of one-year duration. On examination, there was a 8 cm × 7 cm mass, without pulsation or bruit. He was neither hypertensive nor diabetic, and did not have any family history of PGL. MR imaging showed an 8 cm × 7 cm × 5 cm hyperintense mass encasing the carotid artery. Urinary MNs, VMA and ¹³¹I-MIBG scintigraphy were normal. He underwent surgery after alpha blockade. During surgery, he incurred an injury to the right internal carotid artery, which was repaired, and he suffered a left-sided hemiplegia.

Case 3

A 45-year-old nonhypertensive woman presented with a gradually increasing painless swelling in the left parotid region for the past five years. On examination, there was a 3 cm × 3 cm mass with horizontal mobility. MR imaging showed a hyperintense mass measuring 3 cm × 3 cm × 2.5 cm in the carotid bifurcation. Urinary MNs were

Department of
Endocrinology,
Seth GS Medical
College and KEM
Hospital,
Mumbai,
Maharashtra
400012,
India

Mathew BK, MD
Registrar

Bandgar T, DM
Lecturer

Menon PS, MD
Professor

Shah NS, DM
Professor

Correspondence to:
Dr Tushar Bandgar
Tel: (91) 98 2002 5037
Fax: (91) 22 2416 2883
Email: drtusharb@gmail.com

normal. ¹³¹I-MIBG scintigraphy showed uptake in the region of the PGL without evidence of any metastases. She was referred for surgery but refused surgery and is now on follow-up with periodic imaging.

DISCUSSION

Phaeochromocytomas are extra-adrenally located in 10% of cases. 90% of these extra-adrenal PGLs are located in the abdomen, mainly in chromaffin cells of the organ of Zuckerkandl. The remaining 10% of the extra-abdominal PGL include CBT and glomus tumours.⁽²⁾ The carotid body is a vascular reddish-brown structure about the size of a grain of rice located within adventitia posteromedial to bifurcation of the common carotid artery. The carotid body acts as a chemoreceptor responding to variations in oxygen tension and carbon dioxide concentrations; henceforth alternatively named chemodectomas.⁽⁴⁾ CBT usually presents in the fourth to sixth decades of life (age range: 3 months–89 years). The average tumour size is 4.5 cm × 3.5 cm × 3 cm, with the largest ones exceeding 15 cm in diameter and weighing 200 g. There is an increased incidence in high-altitude dwellers and females.⁽⁵⁾ The incidence of bilateral CBT varies from 10% to 25% in different series.

Most of the lesions are benign, but malignant lesions are seen in 6%–12% of cases. The diagnosis of malignancy is reserved for tumours with local, regional and distant metastasis.⁽⁶⁾ There are no histological features that distinguish benign from malignant lesions. Between 10% and 50% of PGLs are hereditary (autosomal dominant) due to alterations in genes coding for succinate-ubiquinone oxidoreductase subunit D (SDHD), B (SDHB) and C (SDHC),⁽⁷⁾ which map to chromosomes 11, 1 and 1, respectively. Only patients who inherit an SDHD mutation from the father are at risk of developing PGL as the gene causing mutation gets activated during spermatogenesis and not during oogenesis (genetic imprinting). Parent-of-origin effects are not seen with SDHB or SDHC mutations. Bayley et al stated that in sporadic head and neck PGL cases, germline mutations of SDH genes were found in 25% in SDHD, 2% in SDHB and 1% in SDHC (total 28%), thus concluding that germline mutations of SDHB and SDHC play a minor role in sporadic head and neck PGL.⁽⁸⁾

Patients with CBT typically present with a painless mass in the angle of the jaw that may be partially covered by the sternocleidomastoid muscle. These vascular tumours may transmit pulsations from nearby carotid arteries or may be pulsatile inherently. At the time of diagnosis, cranial nerve palsies are present in 10% of cases with the X, XII, V and VII cranial nerves commonly involved in decreasing order of frequency, while the involvement of cervical sympathetic produces ipsilateral Horner's syndrome. Carotid sinus syndrome

with bradycardia, hypotension and unconsciousness can occur spontaneously or secondary to head movement or pressure on the tumour. Episodic symptoms of phaeochromocytoma are seen in 1%–3% of cases. Noradrenaline is the usual product and hypertension is the most frequent finding. Being unaware of such functional tumours can cause disastrous consequences during embolisation or surgery.⁽⁵⁾

The size of the tumour is important not only for the clinical manifestations, but also for a decision on treatment. In 1971, Shamblin introduced a classification system based on the tumour size, classifying small tumours which could easily be resected from the vessels as Group I. Group II includes tumours that are intimately associated and compressed carotid vessels, but that could be resected with careful subadventitial dissection. Group III consists of tumours that are large and typically encase the carotid artery, requiring complete or partial vessel resection and replacement.⁽⁹⁾ Biochemical assays are routinely employed for the diagnosis of a functioning tumour, irrespective of symptoms. The usual methods are measurement of urinary free catecholamines and its metabolites VMA and MNs in a 24-hour urine sample.

Initial imaging consists of MR imaging with contrast administration, with PGL showing an intermediate signal on T1-weighted images and a high signal on T2-weighted images. In addition, a PGL size > 2 cm produces a characteristic salt and pepper appearance which results from fast-flowing blood pools and large tumour vessels within these lesions. Total body scintigraphy using ¹²³I-MIBG is used as a screening tool to detect distant additional primary or metastatic lesion in patients or their relatives. Ilias et al compared various methods of optimal imaging for neuroendocrine tumours and stated that various positron-emission tomography (PET) ligands have been used of which dopamine, labelled with ¹⁸F, is a good PET agent (better than ¹³¹I-MIBG) for localising adrenal and extra-adrenal phaeochromocytoma and phaeochromocytomas that do not accumulate ¹³¹I-MIBG or other specific radionuclides (mainly dedifferentiated and/or rapidly growing phaeochromocytomas).⁽¹⁰⁾ Further in their review, they have commented on the importance of ¹¹¹In-DTPA-octreotide scans in the localisation of phaeochromocytoma, which is due to the affinity of this octreotide analogue to the somatostatin receptors (SST-2A, -3, -4, -5 and -1) that are found in these tumours. Studies have shown that octreoscans are not useful for localising tumours that are limited to adrenals (falsely negative when compared with ¹³¹I-MIBG), but ¹¹¹In-DTPA-octreotide studies have been positive in patients with malignant/metastatic phaeochromocytomas and PGLs, where their sensitivity was 90%.⁽¹⁰⁾ Carotid angiography remains the gold standard of diagnosis, but in practice, this study is reserved for patients with larger

tumours and those who are planned for embolisation or resection. Angiography demonstrates the tumour blood supply and widening of the carotid bifurcation by a well-defined tumour blush (lyre sign), which is pathognomonic of CBT.⁽¹¹⁾ Histopathologically, PGL are firm, rubbery well-encapsulated masses composed of nests of epithelioid cells (chief cells), with clear cytoplasm separated by delicate stroma (zellballen pattern).⁽⁴⁾

The success in treating benign and malignant PGL is based on early diagnosis, complete resection of the tumour after an adequate catecholamine blockade, which is given prophylactically. Complete resection of the primary mass is the treatment of choice. Postoperative cranial nerve deficits and arterial injury have remained a significant problem. Patients with larger tumours have an increased incidence of complications. Endovascular embolisation may reduce the operative time and limit blood loss. Most now employ this technique preoperatively for larger tumours of Shamblin Grade III. In patients who are not suited for surgery, irradiation has been attempted for symptomatic relief with varying success.^(12,13) Chemotherapy using vincristine, dacarbazine and cyclophosphamide along with ¹³¹I-MIBG therapy has been attempted for patients with systemic metastasis.⁽¹³⁾ Radiotherapy may be effective for large tumours, recurrent tumours and patients who are poor candidates for surgery.⁽¹⁴⁾

In conclusion, we have reported three cases of CBT with varying presentations, their evaluation and management. Evaluation of preoperative functionality and alpha adrenoreceptor blockade is required in these cases. Long-term follow-up is mandatory as the time interval for local recurrences and distant metastasis can vary from months to years after the initial diagnosis.

REFERENCES

1. Schwartz SI, Shires GT, Spencer FC, et al. Principles of surgery. 6th ed. New York: McGraw Hill, 1994: 273.
2. Casati A, Ferri M, Lucandri G, Fornari F, Sciacca V. [Carotid body tumors. Apropos a case and a review of the literature]. *G Chir* 1999; 20:229-32. Italian.
3. Razakaboay M, Maillefert JF, Wendling D, et al. Bone metastases from a paraganglioma. A review of five cases. *Rev Rhum Engl Ed* 1999; 66:86-91.
4. Lack EE, Cubilla AL, Woodruff JM. Paragangliomas of the head and neck region. A pathologic study of tumors from 71 patients. *Hum Pathol* 1979; 10:191-218.
5. Zak FG, Lawson W. The paraganglionic chemoreceptor system. New York: Springer, 1982: 276-85.
6. Davidovic LB, Djukic VB, Vasic DM, Sindjelic RP, Duvnjak SN. Diagnosis and treatment of carotid body paraganglioma: 21 years of experience at a clinical center of Serbia. *World J Surg Oncol* 2005; 3:10.
7. Grufferman S, Gillman MW, Pasternak LR, Peterson CL, Young WG Jr. Familial carotid body tumors: case report and epidemiologic review. *Cancer* 1980;46:2116-22.
8. Bayley JP, van Minderhout I, Weiss MM, et al. Mutation analysis of SDHB and SDHC: novel germline mutations in sporadic head and neck paraganglioma and familial paraganglioma and/or pheochromocytoma. *BMC Med Genet* 2006; 7:1.
9. Hallett JW Jr, Nora JD, Hollier LH, Cherry KJ Jr, Pairolero PC. Trends in neurovascular complications of surgical management for carotid body and cervical paragangliomas: A fifty-year experience with 153 tumors. *J Vasc Surg* 1988; 7:284-91.
10. Ilias I, Sahdev A, Reznick RH, Grossman AB, Pacak K. The optimal imaging of adrenal tumours: a comparison of different methods. *Endocr Relat Cancer* 2007; 14:587-99.
11. Olsen WL, Dillon DP, Kelly WM, et al. MR imaging of paragangliomas. *Am J Roentgenol* 1987; 148:201-4.
12. Muhm M, Polterauer P, Gstöttner W, et al. Diagnostic and therapeutic approaches to carotid body tumors. Review of 24 patients. *Arch Surg* 1997; 132:279-84.
13. Lázaro B, Klemz M, Flores MS, Landeiro JA. Malignant paraganglioma with vertebral metastasis: case report. *Arq Neuropsiquiatr* 2003; 61:463-7.
14. Sykes JM, Ossoff RH. Paragangliomas of the head and neck. *Otolaryngol Clin North Am* 1986; 19:755-67.