

Inflammatory pseudotumour arising from periampullary carcinoid: a “cancer-like” tumour in a “fake” tumour

Chang S K Y, Liang W T M, Thamboo T P

ABSTRACT

Carcinoid tumours of the gastrointestinal tract are uncommon, generally slow-growing and associated with a good prognosis. We present a 52-year-old Chinese woman with a carcinoid at the ampulla of Vater, a site far less common than other areas of the gastrointestinal tract. Preoperative imaging showed a pancreatic mass with displacement and possible invasion of the portal vein associated with peripancreatic nodal enlargement. A radical pancreaticoduodenectomy with portal vein wedge excision was performed. An intraoperative biopsy of the enlarged nodes was negative for malignancy and postoperative histology of the large pancreatic mass yielded a surprising finding of a carcinoid tumour at the ampulla of Vater with a large inflammatory pancreatic mass adherent to the portal vein. This is an uncommon case associated with “pseudotumour pancreatitis”, causing biliary and pancreatic duct obstruction mimicking a large tumour in the head of the pancreas.

Keywords: ampulla of Vater carcinoid, bile duct obstruction, carcinoid tumours, inflammatory pseudotumour, pancreas pseudotumour, periampullary carcinoid, pseudotumour pancreatitis

Singapore Med J 2009;50(3):e100-e101

INTRODUCTION

Carcinoid tumours of the gastrointestinal tract are uncommon occurrences. They are generally slow-growing and are associated with a good prognosis. Symptoms usually arise from mass effect or from neurohormonal products. We present an extremely uncommon case of carcinoid at the ampulla of Vater, inducing an inflammatory pancreatic mass with biliary and pancreatic duct obstruction, mimicking a large tumour in the head of the pancreas.

CASE REPORT

A 52-year-old Chinese woman presented with a history of malaise, progressive jaundice and tea-coloured

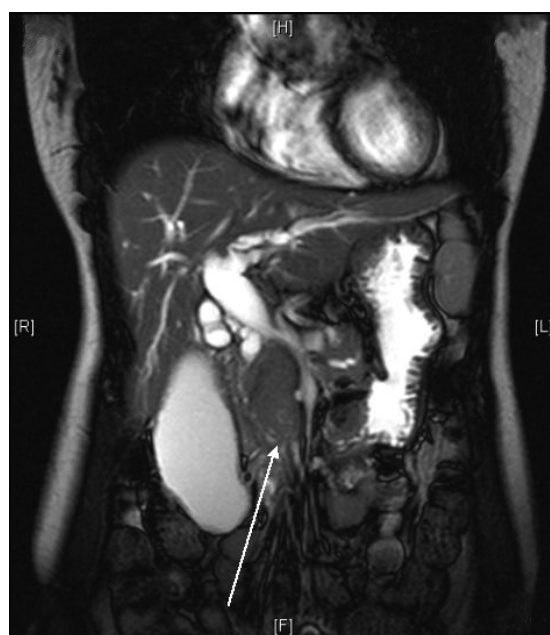

Fig. 1 Coronal fat-suppressed T2-W MR image of the abdomen shows a tumour in the head and uncinate process (arrow) causing compression and displacement with possible invasion of the portal vein.

urine, first noticed two months prior to presentation. She sought medical care only after the occurrence of epigastric pain, which had begun in the recent few weeks. Liver function tests were consistent with obstructive jaundice, with conjugated bilirubin of 95 $\mu\text{mol/L}$ (normal 0–5 $\mu\text{mol/L}$) and serum alkaline phosphatase of 648 $\mu\text{mol/L}$ (normal 40–130 $\mu\text{mol/L}$). CA19-9 was slightly elevated at 82.9 U/ml (normal < 37.0 U/ml). Ultrasonography showed dilated pancreatic, intrahepatic and extrahepatic ducts up to the distal common bile duct. Computed tomography showed a bulky pancreatic head, with no evidence of hepatic or pulmonary metastases. Magnetic resonance (MR) imaging showed a 2.8 cm \times 2.5 cm tumour in the head and uncinate process of the pancreas, suggestive of pancreatic carcinoma, causing compression and displacement with possible invasion of the portal vein (Fig. 1). The retropancreatic nodes were also found to be enlarged. As the patient was not having cholangitis, endoscopic retrograde cholangiopancreatography and endoscopic biliary drainage were not performed.

Department of Surgery,
National University Hospital,
5 Lower Kent Ridge Road,
Singapore 119074

Chang SKY, MBBS,
MMed, FRCSE
Consultant and
Research Director of
Hepatopancreatico-
biliary Division

Liang WTM, MBBS
House Officer

Department of Pathology

Thamboo TP,
MBChB, MRCPATH,
FRCPA
Consultant

Correspondence to:
Dr Chang Stephen
Kin Yong
Tel: (65) 6772 4225
Fax: (65) 6777 8427
Email: surv7@nus.edu.sg

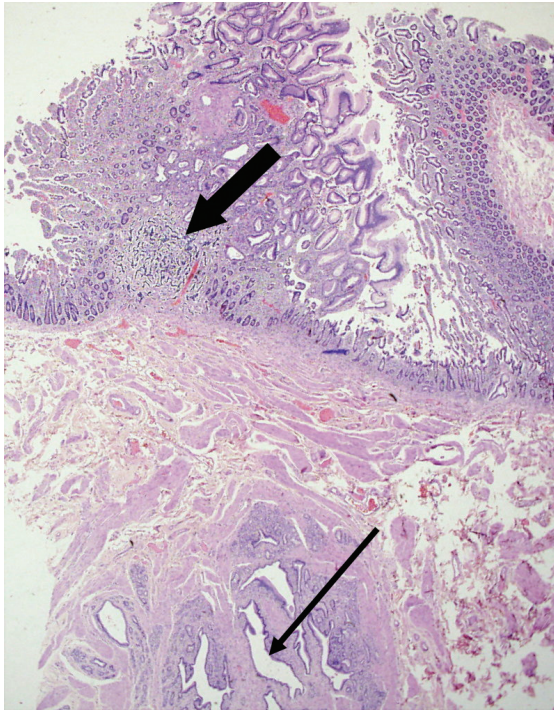


Fig. 2 Photomicrograph shows a tiny carcinoid tumour (thick arrow) in the mucosa at the ampulla of Vater. The distal common bile duct/pancreatic duct (thin arrow) is dilated. (Haematoxylin & eosin, $\times 20$).

The patient underwent elective exploratory laparotomy. A large mass in the pancreatic head and uncinate process was found displacing the portal vein to the left and was inseparable from it on a short segment of its right circumference. The segment of the portal vein that was “invaded” was isolated with control of the superior mesenteric vein, splenic vein and superior portal vein using snare tourniquet, before a wedge of it was resected with the tumour. Primary repair was then performed. The intraoperative frozen section of the pancreatic margin was negative for malignancy. Histopathological examination revealed an unexpected finding of a 0.1 cm carcinoid tumour in the mucosa at the ampulla of Vater (Fig. 2). The firm pancreatic head/uncinate “mass” was due to marked chronic pancreatitis with intralobular and interlobular fibrosis. No pancreatic malignancy was present. All 22 lymph nodes harvested were likewise negative for malignancy.

DISCUSSION

Carcinoids at the ampulla of Vater are exceedingly uncommon, with less than 80 cases reported in the literature so far. Due to their anatomical location, they can obstruct the pancreatic duct and present with acute or chronic pancreatitis.⁽¹⁾ Biliary obstruction is an uncommon presentation.⁽²⁾

In our patient, due to the location of the carcinoid, it can be postulated that it had obstructed the pancreatic and biliary ducts directly, although it was more likely that the obstruction of the biliary duct is secondary

to the “pseudotumour pancreatitis” that was found in the vicinity of the carcinoid. Given that our patient had no risk factors for chronic pancreatitis and no previous symptom of pancreatitis, we speculate that the presence of the carcinoid tumour in the ampulla could have incited an inflammatory response around it, giving rise to the “pseudotumour pancreatitis”. The term “pseudotumour pancreatitis” has been used to describe a sequelae of chronic pancreatitis that results in a mass that mimics a tumour.⁽³⁾ This can produce imaging findings very similar to those of a pancreatic tumour. There are overlapping imaging features such as the dilation of bile and pancreatic ducts, as in our case. However, this is the first reported case where the inflammatory mass had encroached onto the portal vein, causing displacement and what seems like “invasion”, mandating its excision.

Based on preoperative imaging, the disease appeared locally advanced with associated portal vein constriction and displacement as well as lymph node involvement. With this extent of the “disease”, it would have been an option to perform a palliative procedure and treat her with non-surgical modalities instead of a radical resection. This may possibly account for some of the historical cases of long-term survivors treated non-surgically for supposedly “locally advanced” disease. However, portal vein excision has been increasingly accepted as part of radical pancreaticoduodenectomy with good results in recent years.⁽⁴⁾ In view of the slow growing non-aggressive behaviour of these carcinoid tumours, surgical resection followed by the re-establishment of biliary continuity is the treatment of choice for such tumours. In our case, a Whipple operation was performed and the patient recovered well. The overall five-year survival for carcinoids at the ampulla of Vater is quoted to be 40%–60%.⁽⁵⁾ This has been shown to be an interesting case of a small carcinoid at the ampulla of Vater, giving rise to pseudotumour pancreatitis that obstructed both the biliary and pancreatic ducts, and “invaded” the portal vein.

REFERENCES

1. Mergener K, Gottfried MR, Feldman JM, Branch MS. Carcinoid of the ampulla of Vater presenting as acute pancreatitis. *Am J Gastroenterol* 1996; 91:2426-7.
2. Mulder CJ, Festen HP, Mertens JC, et al. Carcinoid tumor of the ampulla of Vater presenting with biliary obstruction: report of four cases. *Gastrointest Endosc* 1987; 33:385-7.
3. Adsay NV, Basturk O, Klimstra DS, Kloppel G. Pancreatic pseudotumors: non-neoplastic solid lesions of the pancreas that clinically mimic pancreas cancer. *Semin Diagn Pathol* 2004; 21:260-7.
4. Poon RT, Fan ST, Lo CM, et al. Pancreaticoduodenectomy with en bloc portal vein resection for pancreatic carcinoma with suspected portal vein involvement. *World J Surg* 2004; 28:602-8.
5. Bickerstaff DR, Ross WB. Carcinoid of the biliary tree: A case report and review of the literature. *J R Coll Surg Edinb* 1987; 32:48-51.