

Acute gastroduodenal injury after ingestion of diluted herbicide pendimethalin

Tsukada K, Azuhata H, Katoh H, Kuwano H

ABSTRACT

The herbicide, pendimethalin, is used worldwide, but its acute toxicity is not yet widely known. There have been some reported acute pendimethalin poisoning cases in humans and most of them intentionally ingested the concentrated formulation. We describe a 73-year-old man who developed corrosive gastroduodenal injury after accidental ingestion of the diluted (300 times with water) pendimethalin formulation. He had a history of reflux oesophagitis and had been taking omeprazol (10 mg/day) for a year. He consumed alcohol two hours after the accidental ingestion and then had nausea and epigastric pain. Endoscopy performed three days post-exposure revealed gastroduodenal injury. As he had consumed alcohol every day for years and had no history of gastroduodenal ulcer, the accidental ingestion may be associated with this injury. He was successfully treated by increasing his dosage of omeprazol (20 mg/day) for two weeks. This case indicates that ingestion of a small quantity of pendimethalin can provoke gastroduodenal injury.

Keywords: alcohol, corrosive gastroduodenal injury, herbicide, pendimethalin, poisoning

Singapore Med J 2009; 50(3): e105-e106

INTRODUCTION

Pendimethalin is a widely-used herbicide for the control of annual grasses and certain broadleaf weeds in commercial crops.⁽¹⁾ It has been classified as a group C possible human carcinogen by the United States Environmental Protection Agency.⁽²⁾ There are some reports of acute pendimethalin poisoning in humans, and most cases have followed the deliberate ingestion of a concentrated formulation of pendimethalin.⁽³⁾ We report a patient who suffered gastroduodenal injury after accidental ingestion of a diluted pendimethalin formulation.

CASE REPORT

A 73-year-old man used the commercial herbicide (30% of pendimethalin and 55% of xylene; BASF Agro Ltd, Tokyo, Japan) and accidentally ingested a small quantity

of its dilution (300 times with water) on June 2, 2007. He had a history of reflux oesophagitis and had been taking omeprazol (10 mg/day) for a year. He had consumed

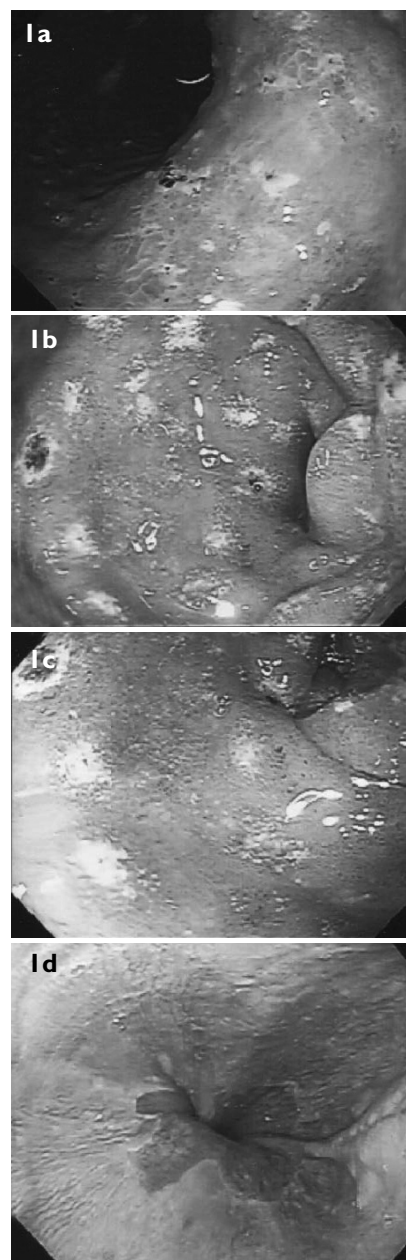


Fig. 1 Endoscopy performed on day three post-exposure shows multiple erosions in the (a,b) stomach and (c) duodenum. (d) Reflux oesophagitis (Los Angeles classification A) was observed.

Kawanishi Red Cross Hospital,
Mochizuki 318,
Saku,
Nagano 384-2292,
Japan

Tsukada K, MD
Chairman of Surgery

Azuhata H, MD
Associate Chairman

Department of General
Surgical Science,
Gunma University,
Graduate School of
Medicine,
Showamachi 3-39-22,
Maebashi,
Gunma 371-8511,
Japan

Katoh H, MD
Associate Professor

Kuwano H, MD
Chairman

Correspondence to:
Dr Katsuhiko Tsukada
Tel: (81) 267 533011
Fax: (81) 267 535901
Email: katukada@topaz.ocn.ne.jp

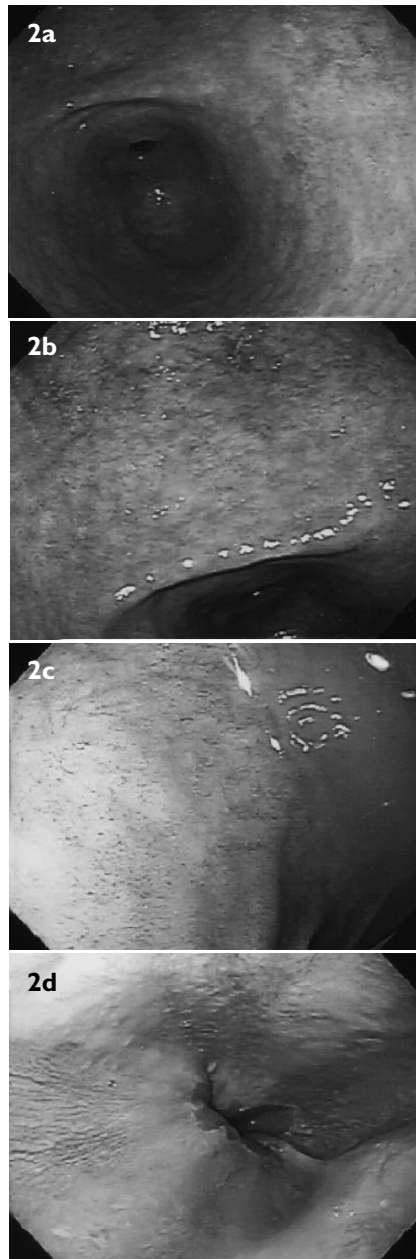


Fig. 2 Endoscopy performed after 14 days of treatment with oral omeprazol shows no mucosal injury in the (a,b) stomach, (c) duodenum, or (d) oesophagus.

alcohol every day for years and had no history of gastroduodenal ulcer. Endoscopy (in December 2006 and in March 2007) had revealed grade-A reflux oesophagitis, but no gastroduodenal lesion. As he had no symptoms or signs, he consumed a meal along with some alcohol (about 60 g ethanol in 300 ml) two hours after ingestion. He then suffered nausea and epigastric pain, and underwent endoscopy on June 5, 2007. Endoscopy showed grade 2b injuries in the stomach (Figs. 1a–b) and duodenum (Fig. 1c) by Zargar et al's modified classification.⁽⁴⁾ There was grade-A reflux oesophagitis (Los Angeles classification)⁽⁵⁾ (Fig. 1d). After receiving an increased dose of omeprazol (20 mg/day) for two weeks, he underwent endoscopy again. There was no mucosal injury in the gastroduodenal lesion (Fig. 2).

DISCUSSION

Chuang et al reported 71 pendimethalin poisoning cases in Taiwan.⁽³⁾ They reported that 20 of the cases had no symptoms or signs, 38 had mild effects such as nausea, vomiting and sore throat, and seven had effects such as severe retching, haematemesis and seizures. Four patients died as a result of also taking other herbicides and because of inadequate airway management. Their patients had ingested a concentrated formulation and the average ingested amount was 106.1 ml. In our patient, the pendimethalin formulation was diluted 300 times with water and the ingested amount was very small. He had a long history of alcohol intake and no history of peptic ulcer. He had symptoms just two hours after accidental ingestion. These indicate that the diluted pendimethalin may have played a pivotal role in this patient. As pendimethalin has cytotoxicity in the mammalian system,⁽⁶⁾ combined pendimethalin-ethanol exposure may have led to the gastroduodenal mucosal injury. Another possible mechanism is that this formulation also contains 55% of xylene and it may have played a pivotal role in the mucosal injury. As xylene is a component of gasoline and its ingestion irritates the gastric mucosa,⁽⁷⁾ it may have exacerbated the ethanol-induced mucosal injury. It has been reported that oesophageal injury frequently occurs in patients with oral toxication of acid agents or of glyphosate-surfactant,^(4,8) but there was no remarkable mucosal damage in the oesophagus of this patient. Although the possibility that other factors caused mucosal injury cannot be completely excluded, combined herbicide/ethanol exposure might have played a pivotal role in this patient. This case indicates that ingestion of a small quantity of herbicide-pendimethalin can cause gastroduodenal injury and that physicians should pay more attention to these patients.

REFERENCES

1. Engebretson J, Hall G, Hengel M, Shibamoto T. Analysis of pendimethalin residues in fruit, nuts, vegetables, grass, and mint by gas chromatography. *J Agric Food Chem* 2001; 49:2198-206.
2. US Environmental Protection Agency. R.E.D. Facts: Pendimethalin. Washington, DC: US EPA; 1997.
3. Chuang CC, Wang ST, Yang CC, Deng JF. Clinical experience with pendimethalin (STOMP) poisoning in Taiwan. *Vet Hum Toxicol* 1998; 40:149-50.
4. Zargar SA, Kochhar R, Nagi B, Mehta S, Mehta SK. Ingestion of corrosive acids. Spectrum of injury to upper gastrointestinal tract and natural history. *Gastroenterology* 1989; 97:702-7.
5. Lundell LR, Dent J, Bennett JR, et al. Endoscopic assessment of oesophagitis: clinical and functional correlates and further validation of the Los Angeles classification. *Gut* 1999; 45:172-80.
6. Patel S, Bajpayee M, Pandey AK, Parmar D, Dhawan A. In vitro induction of cytotoxicity and DNA strand breaks in CHO cells exposed to cypermethrin, pendimethalin and dichlorvos. *Toxicol In Vitro* 2007; 21:1409-18.
7. Reese E, Kimbrough RD. Acute toxicity of gasoline and some additives. *Environ Health Perspect* 1993; 101 Suppl 6:115-31.
8. Chang CY, Peng YC, Hung DZ, et al. Clinical impact of upper gastrointestinal tract injuries in glyphosate-surfactant oral intoxication. *Hum Exp Toxicol* 1999; 18:475-8.