

CME Article

Colonic pseudo-obstruction

Durai R

ABSTRACT

Colonic pseudo-obstruction is often confused with mechanical intestinal obstruction. It occurs when there is an autonomic imbalance resulting in sympathetic over-activity affecting some part of the colon. The patient is often elderly with numerous comorbidities. Once mechanical obstruction is excluded by contrast enema, the patient should be treated conservatively with nasogastric and flatus tubes for at least 48 hours, and precipitating factors should be treated. When pseudo-obstruction does not settle with waitful watching, prokinetic agents and/or colonoscopic decompression can be tried. When there is a risk of impending perforation of the caecum from massive colonic dilatation and colonic ischaemia, it should be dealt with by caecostomy or hemicolectomy. In spite of available medical and surgical interventions, the outcome remains poor.

Keywords: caecostomy, colonic pseudo-obstruction, intestinal pseudo-obstruction, neostigmine, Ogilvie's syndrome

Singapore Med J 2009;50(3):237-244

INTRODUCTION

Intestinal pseudo-obstruction denotes symptoms and signs of intestinal obstruction in the absence of a mechanically-obstructing lesion. It is a form of motility disorder leading to ineffective intestinal propulsion. This condition causes significant morbidity and mortality in elderly hospitalised patients and the commonest presentation is abdominal distension. It is also known as hypoganglionosis, chronic adynamic ileus, pseudo-Hirschprung's disease and megacystis-microcolon-intestinal hypoperistalsis syndrome. The first case of intestinal pseudo-obstruction was described by Ingelfinger in 1943. In 1948, Sir Ogilvie reported two cases of colonic pseudo-obstruction in patients with malignant infiltration of the coeliac plexus. The exact prevalence of intestinal pseudo-obstruction is unknown. Elective orthopaedic procedures requiring prolonged bed rest are associated with the development of pseudo-obstruction, with an incidence of 1.5% after total hip replacement and 2.3% after total knee replacement.⁽¹⁾ The incidence of pseudo-obstruction is higher (18.5%) in mentally-disabled patients.⁽²⁾ Intestinal pseudo-obstruction is rare after open heart surgery, neurosurgery

and lumbar spine surgery. However, any prolonged immobilisation could result in intestinal pseudo-obstruction. This review focuses mainly on colonic pseudo-obstruction in terms of aetiopathology, clinical features and management based on recent evidence.

METHODS

Studies, case reports and review articles which were published during the period 1958–2007 were identified by a PubMed search using the keywords “pseudo-obstruction”, “intestinal pseudo-obstruction” and “Ogilvie's syndrome”. Other resources included textbooks.

TYPES

Acute intestinal pseudo-obstruction occurs in the elderly as a sudden onset of abdominal symptoms. If pseudo-obstruction is congenital and persists for the first two months of life, or if the disorder is acquired and persists for more than six months, then it is considered as chronic.

AETIOLOGY

Intestinal pseudo-obstruction has been associated with diverse aetiologies which are discussed below in detail. In some cases (idiopathic type), no underlying cause may be found.

Electrolyte imbalance: Low levels of potassium, sodium, phosphate, calcium and magnesium may be associated with intestinal pseudo-obstruction. Electrolyte imbalance is often the result of malabsorption that may be associated with pseudo-obstruction rather than be the cause of it.

Infection: Epstein-Barr virus and cytomegalovirus infection may be associated with pseudo-obstruction.

System failure: Organ failures, such as renal failure or respiratory failure (e.g. chronic obstructive airways disease) can cause pseudo-obstruction.

Trauma: Hip and knee joint replacements, retroperitoneal injuries and postoperative immobility can result in intestinal pseudo-obstruction.

Malignancy and endocrine problems: Hypothyroidism and hypoparathyroidism can both cause pseudo-obstruction.⁽³⁾ It can occur as a paraneoplastic disorder in malignant thymoma and small-cell lung cancer.

Drugs: Baclofen, morphine, antidepressants, vinca alkaloids and cytarabine can all cause this condition.

Autoimmune conditions: Systemic lupus erythematosus

Department of
Surgery,
Queen Mary's
Hospital,
Sidcup DA14 6LT,
The United Kingdom

Durai R, MS, MRCS
Specialist Registrar

Correspondence to:
Mr Rajaraman Durai
Department of Surgery,
University Hospital
Lewisham,
Lewisham High Street,
London,
SE13 6LH,
The United Kingdom
Tel: (44) 20 8333 3000
Fax: (44) 20 8333 3333
Email: dr_durai@
yahoo.com

(SLE), myasthenia gravis, other autoimmune conditions with antibodies against voltage-gated K channels⁽⁴⁾ and autoimmune enteric leiomyositis⁽⁵⁾ all lead to pseudo-obstruction.

Others: Multiple sclerosis,⁽⁶⁾ amyloidosis⁽⁷⁾ and mitochondrial disorders can cause pseudo-obstruction.⁽⁸⁾

PATHOLOGY

Intestinal pseudo-obstruction may be myogenic or neurogenic in origin. In neurogenic cases, it is due to an imbalance between the sympathetic and parasympathetic supplies of the colonic smooth muscle.⁽⁹⁾ Abdominal viscera are supplied by both sympathetic and parasympathetic nerves. The sympathetic nerves arise from the lower thoracic and lumbar ganglia. The preganglionic nerves from these ganglia form a synapse in the preaortic ganglia. The sympathetic nerves arising from these ganglia supply the intestines. The parasympathetic nervous supply comes from the vagus nerve which supplies the right half of the colon up to the splenic flexure, and the rest of the colon is supplied by sacral nerve roots. Decreased parasympathetic tone or increased sympathetic tone of the left colon can cause functional obstruction.⁽¹⁰⁾ The autonomic dysfunction is localised mostly to the post-ganglionic pathways.⁽¹¹⁾ The autonomic nervous system controls the so-called enteric nervous system. The enteric nervous system consists of a network of nerves which lie in the submucosa and intermuscular layers. There are two main neurotransmitters in the enteric nervous system. They are acetylcholine, which increases intestinal secretions and motility, and noradrenaline, which decreases both intestinal secretions and motility.

Fasting gastrointestinal motility in humans is characterised by regular cyclic activity of the migrating motor complex (MMC). Patients with intestinal pseudo-obstruction may show abnormal bursts of MMC causing uncoordinated contractile activity of the intestines.⁽¹²⁾ Interstitial cells of cajal (ICC) are specialised pacemaker-like cells found throughout the gastrointestinal tract and are essential for normal gastrointestinal motility. They may be absent or deranged in intestinal pseudo-obstruction.^(9,13) ICC form extensive networks of electrically coupled cells. Certain ICCs act as pacemaker cells and other ICCs appear to be involved in the relaxation of smooth muscles triggered by nitric oxide (NO).⁽¹⁴⁾ The sustained production of NO, which is a result of the oxidation of L-arginine amino acid due to increased nitrous oxide synthase activity and a deficiency of c-kit cells in the intestine, may be related to the pathogenesis of pseudo-obstruction.⁽¹⁵⁾ Dilatation of other viscera, such as the renal pelvis, ureter or urinary bladder, may be present in some patients, confirming autonomic imbalance.⁽¹⁶⁾ There may be a deficiency

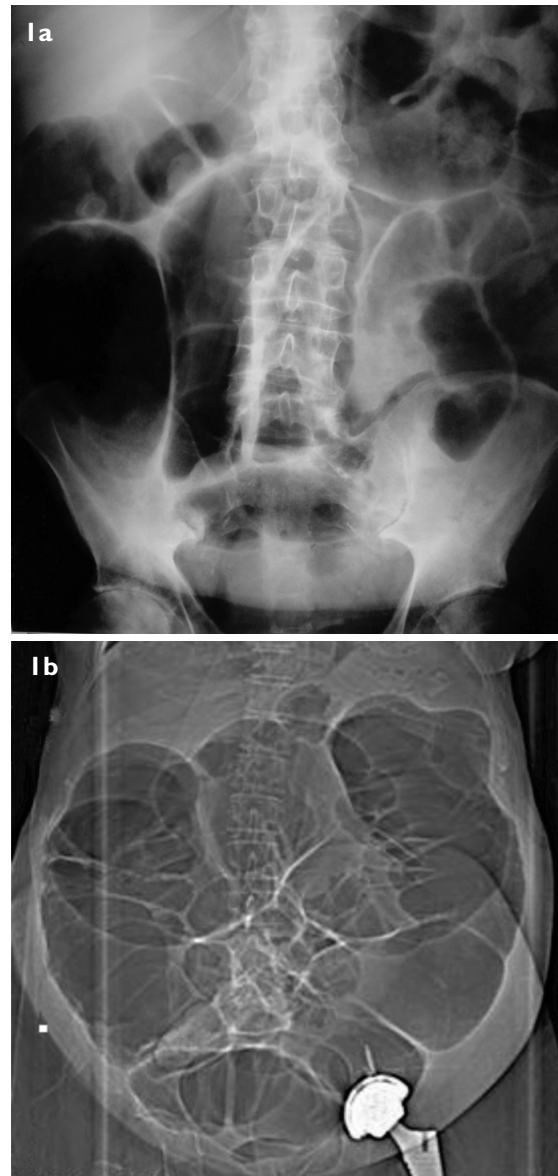


Fig. 1 (a) Supine radiograph of the abdomen of a patient with intestinal pseudo-obstruction shows a dilated large bowel. It resolved after insertion of a rectal tube. (b) Axial CT image shows intestinal pseudo-obstruction three days after arthroplasty of the left hip. It resolved after opioids were stopped.

of alpha-actin in the inner circular layer of the small intestinal smooth muscle in pseudo-obstruction.^(17,18) In autoimmune conditions, there may be high anti-neuronal and anti-calcium channel antibodies.⁽¹⁹⁾ When pseudo-obstruction occurs as a paraneoplastic syndrome, there may be a production of antineuronal antibodies and auto-antibodies against voltage-gated potassium channels⁽⁴⁾ and enteric neuronal degeneration.⁽²⁰⁾ In myogenic cases of pseudo-obstruction, the pathology lies in the muscle and the myocytes often undergo atrophy and are weak. Such visceral myopathy may occur in diseases such as connective tissue disorders, resulting in ineffective intestinal propulsion.

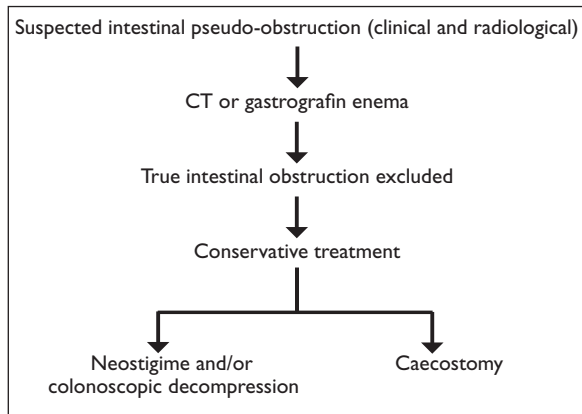


Fig. 2 Flow chart shows the suggested plan of managing a suspected case of intestinal pseudo-obstruction.

CLINICAL FEATURES

Intestinal pseudo-obstruction may present as abdominal distention with or without pain, constipation, nausea and vomiting after eating.^(21,22) It can manifest at any age, and in chronic cases, there will be a degree of malabsorption and malnutrition. Acute colonic pseudo-obstruction is commonly found in elderly patients in the postoperative period. Mild forms usually settle without any intervention. In moderate to severe forms, the patient may have massive abdominal distension causing diaphragmatic splinting and difficulty in breathing. Recent evidence shows that the incidence of caecal perforation in intestinal pseudo-obstruction can be up to 15%.⁽²³⁾ Caecal distension may interfere with the perfusion of its wall, resulting in ischaemia, and increased caecal pressure could lead to perforation. After caecal perforation, the patient will present with features of diffuse peritonitis.

DIAGNOSIS

The diagnosis is made upon a combination of clinical and radiographical findings and exclusion of mechanical obstruction.

Radiographs: Abdominal radiographs may show a dilated small and/or large bowel. Air may be present up to the rectum. However, the large bowel is often cut off at the splenic flexure, rectosigmoid junction or at the hepatic flexure (Fig. 1a). In such cases, a contrast enema needs to be performed in order to exclude the possibility of mechanical intestinal obstruction.

Contrast enema: This is the gold standard investigation of choice to exclude mechanical obstruction and confirm the diagnosis.⁽²⁴⁾ When there is a clinical suspicion regarding whether the patient had a bowel perforation, gastrografen enema should be used. Signs suggestive of intestinal pseudo-obstruction are the absence of stricture, disorganised, decreased or absent motility in any segment of the gastrointestinal tract, and decreased

Table I. Non-surgical treatment of pseudo-obstruction.

- (1) Ensure nil by mouth
- (2) Insert nasogastric tube
- (3) Insert rectal flatus tube
- (4) Correct electrolyte imbalance
- (5) Adjust posture
- (6) Correct any predisposing cause
- (7) Assess the colonic diameter via abdominal radiograph
- (8) Stop any opioids and anticholinergics

or absent haustrations and/or redundancy in the colon.⁽²⁵⁾ When gastrografen enema shows equivocal results, barium enema will be helpful, although some surgeons disagree.⁽²⁶⁾

Computed tomography (CT): CT is often useful in excluding mechanical obstruction particularly out of hours when gastrografen enema may not be feasible (Fig. 1b). CT can assess any bowel wall thickening, luminal growths, mesenteric and para-aortic lymph nodes, retroperitoneum, liver and spleen.

Endoscopy: Colonoscopy is both diagnostic and therapeutic in excluding colonic lesions and decompressing the dilated colon. An intestinal biopsy can be obtained that may be useful in excluding secondary causes of intestinal pseudo-obstruction, such as neuronal dysplasia or changes in smooth muscle actin. Capsular endoscopy is contraindicated in pseudo-obstruction because it may be retained for a long time.⁽²⁷⁾

Manometry and intestinal transit scintigraphy: This is often used in children to assess the extent and severity of pseudo-obstruction, particularly in cases of Hirschsprung's disease.⁽²⁸⁾ The motility patterns may vary from normal colonic motility to global dysmotility with massive distension.^(29,30) Some patients may present persistent segmental dysmotility.

TREATMENT

The approach to suspected pseudo-obstruction is shown in Fig. 2, and non-surgical treatment that is available for intestinal pseudo-obstruction is shown in Table I. The main aim of the treatment is to restore nutrition and hydration, improve intestinal propulsion with prokinetics and suppress bacterial overgrowth. The idiopathic type of pseudo-obstruction is often refractory to both medical and surgical treatment.⁽³¹⁾ Where the underlying cause is known, such as myxoedema, hypoparathyroidism or pheochromocytoma, it should be treated. When SLE is associated with pseudo-obstruction, it may respond to immunosuppression. The management of pseudo-obstruction is discussed under three headings, namely: medical, endoscopy and surgery.

Table II. Medicines used in acute pseudo-obstruction.

Drug	Dose	Mechanism of action	Advantage	Note
Erythromycin	0.5 g tds or qds	Motilin agonist, main use in gastroparesis	Cheap	Less effective if the patient is taking opioids
Cisapride	20 mg/day	Acts on 5-HT-4 receptors	Useful in diabetic gastroparesis	Banned in the UK
Domperidone	20 mg tds	Blocks the dopamine receptors in the gut	Does not readily enter the blood-brain barrier	Can cause hyperprolactinaemia
Metaclopramide	10 mg tds	Blocks dopaminergic (D2) receptors	Cheap	Can cause extra pyramidal symptoms
Neostigmine	2 mg IV	Acetylcholinesterase inhibitor	Effective	Needs monitoring in the intensive therapy or high-dependency unit

MEDICAL TREATMENT

Treatment includes nasogastric drainage, repeated enemas, rectal flatus tube insertion, correction of electrolyte imbalance and stoppage of drugs such as opioids. Any precipitating factor should be corrected wherever possible.

Postural change: The change of position of the patient may help to resolve pseudo-obstruction. Knee-chest or prone position with the hip elevated may result in spontaneous resolution. However, these postures may not be possible because of comorbidities such as obesity and obstructive airway disease.

Hyperbaric oxygen: Hyperbaric oxygenation may be effective in the management of chronic idiopathic intestinal pseudo-obstruction due to myopathy.⁽³¹⁾ There is not enough evidence available to define its role and mechanism of action in pseudo-obstruction.

Antibiotics: Intermittent antibiotic therapy may be needed to alleviate diarrhoea or steatorrhoea due to bacterial overgrowth in the small intestine. Antibiotics that may be useful in this situation include metronidazole, ciprofloxacin and doxycycline. Antibiotic prophylaxis may be useful to eradicate the bacteria in the small bowel and would possibly reduce the postoperative abdominal sepsis from contamination by small bowel contents.⁽³²⁾

Prokinetic agents: A summary of the drugs that are useful in pseudo-obstruction are shown in Table II. Erythromycin is often useful in improving gut motility. It exerts its prokinetic effect by acting as a motilin agonist.⁽³³⁾ According to a study, gastric emptying, measured by the sulphamethizole method, and intestinal transit, evaluated using radiopaque markers, were markedly improved by treatment with erythromycin.⁽³⁴⁾ The efficacy of prokinetic agents appears to be variable.⁽³⁵⁾ Intravenously-administered erythromycin may be useful in treating postoperative ileus and chronic intestinal pseudo-obstruction.⁽³⁶⁾ It can cause bloating, abdominal pain, nausea and vomiting. Repeated intravenous administration through the peripheral vein may cause

phlebitis. A trial of cisapride may be considered for patients with acute intestinal pseudo-obstruction when other therapeutic manoeuvres have failed.⁽³⁷⁾ Effective treatment for chronic idiopathic intestinal pseudo-obstruction may be a combination of erythromycin and cisapride.⁽³⁸⁾ Cisapride can cause long QT syndrome leading to cardiac arrhythmias. Therefore, it has been withdrawn from use in several countries.

Cholinesterase inhibitors: Cholinesterase inhibitors are effective in relieving acute colonic pseudo-obstruction. Intravenous neostigmine is the best pharmacological treatment,^(39,40) leading to rapid colonic decompression. Neostigmine inhibits acetylcholinesterase and stimulates both the nicotinic and muscarinic receptors. The therapeutic effect on pseudo-obstruction is because of its parasympathomimetic action. It increases parasympathetic activity leading to hyperperistalsis. In a randomised controlled trial, ten out of 11 patients who received 2 mg of neostigmine successfully passed flatus within 30 minutes with a median of four minutes.⁽⁴¹⁾ The side effects of neostigmine include increased salivation and bronchial secretion, severe bronchospasm, cardiac arrhythmias, asystole, hypotension, muscle cramps and seizures. All these are the outcome of excessive parasympathetic activity. Therefore, the patient should always be monitored and any toxicity should be reversed by atropine. The patient also requires admission to a high-dependency unit or cardiac care unit for the administration of neostigmine. Recent myocardial infarction, asthma and mechanical intestinal obstruction are contraindications for administering neostigmine. New colokinetic agents, including 5-HT receptor agonists and motilides, may represent other useful therapeutic options for Ogilvie's syndrome.⁽³⁹⁾

Somatostatin analogues: Octreotide is useful in paraneoplastic syndromes and scleroderma. It increases intestinal motility independent of motilin. Scleroderma patients do not have significant MMCs in the intestines and the octreotide, by an unknown mechanism, increases

Table III. Reports of success rate of various methods in pseudo-obstruction.

Reference	Method used	Success rate (%)
Emmanuel et al ⁽³⁶⁾	Erythromycin	40
Ponec et al ⁽⁴¹⁾	Neostigmine	91
Perlemuter et al ⁽⁵¹⁾	Octreotide in connective tissue disease	100*
Lee et al ⁽⁵²⁾	Epidural	62
Jetmore et al ⁽⁵³⁾	Colonoscopic decompression	64

*One study from Japan reported that octreotide may not be successful in pseudo-obstruction associated with an advanced systemic sclerosis.

Table IV. Recurrence of pseudo-obstruction and morbidity associated with each method.

Reference	Method used	Recurrence (%)	Morbidity
Farinon et al ⁽⁵⁴⁾	Colonoscopy	29	Pain, risk of perforation
Lee et al ⁽⁵²⁾	Epidural	None	Safe
Ponec et al ⁽⁴¹⁾	Neostigmine	20	Abdominal pain, cardiac arrhythmia, excess salivation, vomiting
Dalgic et al ⁽⁵⁵⁾	Erythromycin	50	Abdominal pain, liver function disturbance, tachyphylaxis

the MMC in such patients. Octreotide inhibits several gastrointestinal hormones and can alter blood sugar levels. Usually it is well tolerated without side effects.

Plasmapheresis: This may be useful in selective cases of paraneoplastic disorders where pseudo-obstruction is associated with autoantibodies.⁽⁴⁾

Spinal anaesthesia: Spinal/epidural anaesthesia causing resolution of some cases of intestinal pseudo-obstruction has been well-documented.⁽¹⁰⁾ It is due to a blockade of sympathetic activity which may be responsible for intestinal pseudo-obstruction.

Nutrition: In chronic and recurrent pseudo-obstruction, there may be bacterial overgrowth in the small bowel leading to malabsorption. Total parenteral nutrition may be required in such cases, particularly in children, and its long-term use is associated with chronic cholestasis and potential hepatic failure.⁽⁴²⁾

ENDOSCOPIC DECOMPRESSION

Successful colonoscopic decompression was first described by Kukora and Dent in 1977.⁽⁴³⁾ The success rate is about 80%.⁽⁴⁴⁾ Failure is often due to thick viscid stool. Colonoscopy may be difficult in these patients because of the stool volume and poor bowel preparation. Bowel preparations may not be acceptable or possible in patients with pseudo-obstruction. It may result in increased abdominal distension and the precipitation of vomiting and perforation. While performing colonoscopy, the amount of air insufflation should be kept to a minimum because it can cause further caecal distension leading to perforation. Successful colonoscopic decompression can be combined with the insertion of a flatus tube to prevent the recurrence of pseudo-obstruction. In a study of 22

patients who underwent colonoscopic decompression,⁽⁴⁵⁾ the pseudo-obstruction was resolved completely in 17 patients (77%). Three patients (14%) underwent an operation because of caecal dilatation refractory to colonoscopic decompression. A long intestinal tube may help in pseudo-obstruction. The tip of the long tube can be placed in the caecum with a colonoscope, and its position can be confirmed on an abdominal radiograph. Intermittent aspiration of the tube with a syringe may decompress the colon. Tables III and IV show the success and recurrence rates associated with various methods that are used in pseudo-obstruction.

SURGERY

Surgery for intestinal pseudo-obstruction should be limited to patients who are refractory to medical therapy with deteriorating pseudo-obstruction, particularly those with impending or real ischaemia of the caecum, and should be focused on the patient's presenting symptoms. **Percutaneous endoscopic colostomy (PEC):** Caecostomy can be performed under open, endoscopic as well as laparoscopic guidance. It is required when conservative and endoscopic treatments fail to relieve pseudo-obstruction. PEC is an effective option for selected patients with chronic intestinal pseudo-obstruction.^(46,47) Trocar caecostomy may be useful if the patient is very unfit and very moribund.

Colectomy: Patients with pseudo-obstruction often suffer from numerous comorbidities and therefore may not be good candidates for any major surgery. When the conservative measures fail, surgery may be the only available option. When there is perforation or gangrene of the bowel, the affected region should be resected. Right

hemicolectomy can be performed in the case of caecal perforation. If the pseudo-obstruction is confined to the left colon, loop transverse colostomy may provide a diversion and help to solve the crisis. When the caecum is ischaemic and the rest of the colon is oedematous, subtotal colectomy and end ileostomy may be a good option.

Intestinal transplantation: Small bowel or multivisceral transplantation is feasible in children and adults with chronic pseudo-obstruction so that they can be weaned from parenteral nutrition.⁽⁹⁾ It is useful for patients with irreversible intestinal failure who can no longer be maintained on parenteral nutrition.^(48,49) There is no such option available for colonic pseudo-obstruction without involving the small bowel.

PROGNOSIS

The median hospital stay for patients with intestinal pseudo-obstruction is five days.⁽⁴⁴⁾ Surgical intervention is often associated with increased morbidity and mortality. The mortality associated with caecal perforation or ischaemia is approximately 40%–50%.⁽⁵⁰⁾ The long-term outcome for severe intestinal pseudo-obstruction is generally poor, despite surgical and medical therapies.⁽⁹⁾

CONCLUSION

Intestinal pseudo-obstruction is a disorder of intestinal motility. After excluding mechanical obstruction, these patients should be initially managed conservatively. When conservative treatment is not successful, neostigmine and colonoscopic decompression may be attempted. Surgery in the form of caecostomy or colonic resection should be reserved for patients who are resistant to medical treatment and those with complications. Surgery is associated with postoperative complications.

REFERENCES

- Nelson JD, Urban JA, Salsbury TL, Lowry JK, Garvin KL. Acute colonic pseudo-obstruction (Ogilvie syndrome) after arthroplasty in the lower extremity. *J Bone Joint Surg Am* 2006; 88:604-10.
- Khalid K, Al-Salamah SM. Spectrum of general surgical problems in the developmentally disabled adults. *Saudi Med J* 2006; 27:70-5.
- Taybi H, Keele D. Hypoparathyroidism: a review of the literature and report of two cases in sisters, one with steatorrhea and intestinal pseudo-obstruction. *Am J Roentgenol Radium Ther Nucl Med* 1962; 88:432-42.
- Viallard JF, Vincent A, Moreau JF, et al. Thymoma-associated neuromyotonia with antibodies against voltage-gated potassium channels presenting as chronic intestinal pseudo-obstruction. *Eur Neurol* 2005; 53:60-3.
- Haas S, Bindl L, Fischer HP. Autoimmune enteric leiomyositis: a rare cause of chronic intestinal pseudo-obstruction with specific morphological features. *Hum Pathol* 2005; 36:576-80.
- Lane SW, Pender MP. Intestinal pseudo-obstruction complicating multiple sclerosis. *Intern Med J* 2005; 35:191-2.
- Legge DA, Wollaeger EE, Carlson HC. Intestinal pseudo-obstruction in systemic amyloidosis. *Gut* 1970; 11:764-7.
- Gilbert J, Ibdah JA. Intestinal pseudo-obstruction as a manifestation of impaired mitochondrial fatty acid oxidation. *Med Hypotheses* 2005; 64:586-9.
- Stanghellini V, Cogliandro RF, De Giorgio R, et al. Natural history of chronic idiopathic intestinal pseudo-obstruction in adults: a single center study. *Clin Gastroenterol Hepatol* 2005; 3:449-58.
- Mashour GA, Peterfreund RA. Spinal anesthesia and Ogilvie's syndrome. *J Clin Anesth* 2005; 17:122-3.
- Khurana RK, Schuster MM. Autonomic dysfunction in chronic intestinal pseudo-obstruction. *Clin Auton Res* 1998; 8:335-40.
- Watanabe Y, Ito T, Ando H, Seo T, Nimura Y. Manometric evaluation of gastrointestinal motility in children with chronic intestinal pseudo-obstruction syndrome. *J Pediatr Surg* 1996; 31:233-8.
- Jain D, Moussa K, Tandon M, Culpepper-Morgan J, Proctor DD. Role of interstitial cells of Cajal in motility disorders of the bowel. *Am J Gastroenterol* 2003; 98:618-24.
- Vanderwinden JM. Role of interstitial cells of Cajal and their relationship with the enteric nervous system. *Eur J Morphol* 1999; 37:250-6.
- Wang ZQ, Watanabe Y, Toki A, et al. Involvement of endogenous nitric oxide and c-kit-expressing cells in chronic intestinal pseudo-obstruction. *J Pediatr Surg* 2000; 35:539-44.
- Yan JC, Chao YC, Chang WG, Young TH, Shyu RY. Chronic idiopathic intestinal pseudo-obstruction. *Zhonghua Yi Xue Za Zhi (Taipei)* 2000; 63:251-5.
- Silk DB. Chronic idiopathic intestinal pseudo-obstruction: the need for a multidisciplinary approach to management. *Proc Nutr Soc* 2004; 63:473-80.
- Knowles CH, Silk DB, Darzi A, et al. Deranged smooth muscle alpha-actin as a biomarker of intestinal pseudo-obstruction: a controlled multinational case series. *Gut* 2004; 53:1583-9.
- Simpson DA, Pawlak AM, Tegmeyer L, Doig C, Cox D. Paraneoplastic intestinal pseudo-obstruction, mononeuritis multiplex, and sensory neuropathy/neuronopathy. *J Am Osteopath Assoc* 1996; 96:125-8.
- Sorhaug S, Steinshamn SL, Waldum HL. Octreotide treatment for paraneoplastic intestinal pseudo-obstruction complicating SCLC. *Lung Cancer* 2005; 48:137-40.
- Warner E, Jeejeebhoy KN. Successful management of chronic intestinal pseudo-obstruction with home parenteral nutrition. *JPEN J Parenter Enteral Nutr* 1985; 9:173-8.
- Mann SD, Debinski HS, Kamm MA. Clinical characteristics of chronic idiopathic intestinal pseudo-obstruction in adults. *Gut* 1997; 41:675-81.
- Kiss L, Nica C. [Acute colonic pseudo-obstruction or Ogilvie syndrome]. *Chirurgia (Bucur)* 2000; 95:437-45. Romanian.
- Chapman AH, McNamara M, Porter G. The acute contrast enema in suspected large bowel obstruction: value and technique. *Clin Radiol* 1992; 46:273-8.
- Byrne WJ, Cipel L, Ament ME, Gyepes MT. Chronic idiopathic intestinal pseudo-obstruction syndrome. Radiologic signs in children with emphasis on differentiation from mechanical obstruction. *Diagn Imaging* 1981; 50:294-304.
- Orr KB. Acute colonic pseudo-obstruction: comment. *Aust N Z J Surg* 1998; 68:863-4.
- Storch I, Barkin JS. Contraindications to capsule endoscopy: do any still exist? *Gastrointest Endosc Clin N Am* 2006; 16:329-36.
- Martin MJ, Steele SR, Noel JM, Weichmann D, Azarow KS. Total colonic manometry as a guide for surgical management of functional colonic obstruction: Preliminary results. *J Pediatr Surg* 2001; 36:1757-63.
- Martin MJ, Steele SR, Mullenix PS, et al. A pilot study using

- total colonic manometry in the surgical evaluation of pediatric functional colonic obstruction. *J Pediatr Surg* 2004; 39:352-9.
30. Panganamamula KV, Parkman HP. Chronic intestinal pseudo-obstruction. *Curr Treat Options Gastroenterol* 2005;8:3-11.
 31. Yokota T, Suda T, Tsukioka S, et al. The striking effect of hyperbaric oxygenation therapy in the management of chronic idiopathic intestinal pseudo-obstruction. *Am J Gastroenterol* 2000; 95:285-8.
 32. Anuras S, Christensen J. Recurrent or chronic intestinal pseudo-obstruction. *Clin Gastroenterol* 1981; 10:177-89.
 33. Longo WE, Vernava AM 3rd. Prokinetic agents for lower gastrointestinal motility disorders. *Dis Colon Rectum* 1993; 36:696-708.
 34. Minami T, Nishibayashi H, Shinomura Y, Matsuzawa Y. Effects of erythromycin in chronic idiopathic intestinal pseudo-obstruction. *J Gastroenterol* 1996; 31:855-9.
 35. Verne GN, Sninsky CA. Chronic intestinal pseudo-obstruction. *Dig Dis* 1995; 13:163-81.
 36. Emmanuel AV, Shand AG, Kamm MA. Erythromycin for the treatment of chronic intestinal pseudo-obstruction: description of six cases with a positive response. *Aliment Pharmacol Ther* 2004; 19:687-94.
 37. Mazloun BW, Barnes JB, Lee M. Cisapride as a successful treatment for acute intestinal pseudo-obstruction. *South Med J* 1996; 89:828-30.
 38. Yanagisawa M, Kusano M, Doi I, et al. [Effective treatment in combination with erythromycin and cisapride for chronic idiopathic intestinal pseudo-obstruction (CIIP)]. *Nippon Shokakibyō Gakkai Zasshi* 1998; 95:1022-6. Japanese.
 39. De Giorgio R, Stanghellini V, Barbara G, et al. Prokinetics in the treatment of acute intestinal pseudo-obstruction. *IDrugs* 2004; 7:160-5.
 40. Park CH, Joo YE, Kim HS, et al. Neostigmine for the treatment of acute hepatic encephalopathy with acute intestinal pseudo-obstruction in a cirrhotic patient. *J Korean Med Sci* 2005; 20:150-2.
 41. Ponc R, Saunders MD, Kimmey MB. Neostigmine for the treatment of acute colonic pseudo-obstruction. *N Engl J Med* 1999; 341:137-41.
 42. Barr JM. Understanding pediatric intestinal pseudo-obstruction: implications for nurses. *Gastroenterol Nurs* 1998; 21:11-3.
 43. Trevisani GT, Hyman NH, Church JM. Neostigmine: safe and effective treatment for acute colonic pseudo-obstruction. *Dis Colon Rectum* 2000; 43:599-603.
 44. Alwan MH, van Rij AM. Acute colonic pseudo-obstruction. *Aust N Z J Surg* 1998; 68:129-32.
 45. Bode WE, Beart RW Jr, Spencer RJ, et al. Colonoscopic decompression for acute pseudo-obstruction of the colon (Ogilvie's syndrome). Report of 22 cases and review of the literature. *Am J Surg* 1984; 147:243-5.
 46. Thompson AR, Pearson T, Ellul J, Simson JN. Percutaneous endoscopic colostomy in patients with chronic intestinal pseudo-obstruction. *Gastrointest Endosc* 2004; 59:113-5.
 47. Ramage JI Jr, Baron TH. Percutaneous endoscopic cecostomy: a case series. *Gastrointest Endosc* 2003; 57:752-5.
 48. Masetti M, Di Benedetto F, Cautero N, et al. Intestinal transplantation for chronic intestinal pseudo-obstruction in adult patients. *Am J Transplant* 2004; 4:826-9.
 49. Pironi L, Spinucci G, Paganelli F, et al. Italian guidelines for intestinal transplantation: potential candidates among the adult patients managed by a medical referral center for chronic intestinal failure. *Transplant Proc* 2004; 36:659-61.
 50. Saunders MD, Kimmey MB. Systematic review: acute colonic pseudo-obstruction. *Aliment Pharmacol Ther* 2005; 22:917-25.
 51. Perlemuter G, Cacoub P, Wechsler B, et al. [Chronic intestinal pseudo-obstruction secondary to connective tissue diseases]. *Gastroenterol Clin Biol* 2001; 25:251-8. French.
 52. Lee JT, Taylor BM, Singleton BC. Epidural anesthesia for acute pseudo-obstruction of the colon (Ogilvie's syndrome). *Dis Colon Rectum* 1988; 31:686-91.
 53. Jetmore AB, Timmcke AE, Gathright JB, Jr, et al. Ogilvie's syndrome: colonoscopic decompression and analysis of predisposing factors. *Dis Colon Rectum* 1992; 35:1135-42.
 54. Farinon AM, Stroppa I, Torquati A, D'Antini P. Acute pseudo-obstruction of the colon (Ogilvie's syndrome): advances in management. *Ann Ital Chir* 1997; 68:331-6.
 55. Dalgic B, Sari S, Dogan I, Unal S. Chronic intestinal pseudo-obstruction: report of four pediatric patients. *Turk J Gastroenterol* 2005; 16:93-7.

SINGAPORE MEDICAL COUNCIL CATEGORY 3B CME PROGRAMME
Multiple Choice Questions (Code SMJ 200903A)

	True	False
Question 1. Regarding intestinal pseudo-obstruction:		
(a) It is common in children.	<input type="checkbox"/>	<input type="checkbox"/>
(b) It is common in demented elderly patients.	<input type="checkbox"/>	<input type="checkbox"/>
(c) The commonest symptom is vomiting.	<input type="checkbox"/>	<input type="checkbox"/>
(d) It occurs more commonly after hip replacement compared to knee replacement.	<input type="checkbox"/>	<input type="checkbox"/>
Question 2. The following may cause pseudo-obstruction:		
(a) Morphine.	<input type="checkbox"/>	<input type="checkbox"/>
(b) Chronic obstructive pulmonary disease.	<input type="checkbox"/>	<input type="checkbox"/>
(c) Hypothyroidism.	<input type="checkbox"/>	<input type="checkbox"/>
(d) Systemic lupus erythematosus.	<input type="checkbox"/>	<input type="checkbox"/>
Question 3. Regarding the pathogenesis of pseudo-obstruction:		
(a) Decreased sympathetic activity can lead to pseudo-obstruction.	<input type="checkbox"/>	<input type="checkbox"/>
(b) Interstitial cells of cajal are found in excess.	<input type="checkbox"/>	<input type="checkbox"/>
(c) It can affect the urinary system.	<input type="checkbox"/>	<input type="checkbox"/>
(d) It can occur as a paraneoplastic syndrome.	<input type="checkbox"/>	<input type="checkbox"/>
Question 4. Regarding the diagnosis of pseudo-obstruction:		
(a) A radiograph alone is enough to diagnose pseudo-obstruction.	<input type="checkbox"/>	<input type="checkbox"/>
(b) Barium meal follow-through is the investigation of choice.	<input type="checkbox"/>	<input type="checkbox"/>
(c) Contrast enema is the investigation of choice.	<input type="checkbox"/>	<input type="checkbox"/>
(d) Capsular endoscopy is often useful in confirming pseudo-obstruction.	<input type="checkbox"/>	<input type="checkbox"/>
Question 5. Regarding the management of pseudo-obstruction:		
(a) Best pharmacological treatment is neostigmine.	<input type="checkbox"/>	<input type="checkbox"/>
(b) Epidural blockade may relieve pseudo-obstruction.	<input type="checkbox"/>	<input type="checkbox"/>
(c) Success rate of endoscopic decompression is 20%.	<input type="checkbox"/>	<input type="checkbox"/>
(d) When non-surgical treatments fail, the only option is subtotal colectomy.	<input type="checkbox"/>	<input type="checkbox"/>

Doctor's particulars:

Name in full: _____

MCR number: _____ Specialty: _____

Email address: _____

SUBMISSION INSTRUCTIONS:

(1) Log on at the SMJ website: <http://www.sma.org.sg/cme/smj> and select the appropriate set of questions. (2) Select your answers and provide your name, email address and MCR number. Click on "Submit answers" to submit.

RESULTS:

(1) Answers will be published in the SMJ May 2009 issue. (2) The MCR numbers of successful candidates will be posted online at www.sma.org.sg/cme/smj by 20 May 2009. (3) All online submissions will receive an automatic email acknowledgment. (4) Passing mark is 60%. No mark will be deducted for incorrect answers. (5) The SMJ editorial office will submit the list of successful candidates to the Singapore Medical Council.

Deadline for submission: (March 2009 SMJ 3B CME programme): 12 noon, 15 May 2009.