

Magnetic resonance imaging-guided closed reduction treatment for developmental dysplasia of the hip

Vandevenne J E, Lincoln T, Butts Pauly K, Rinsky L, Lang P K

ABSTRACT

Introduction: This study aimed to describe the radiological aspects and procedural steps of magnetic resonance (MR) imaging-guided closed reduction for the treatment of developmental dysplasia of the hip (DDH).

Methods: Infants were positioned on a custom-made hip spica table attached to a vertically open double doughnut-shaped MR imaging unit (GE Signa SP, 0.5T) affording access to one orthopaedic surgeon and one radiologist. Standard MR imaging sequences and rapid dynamic MR imaging sequences, including fast spin-echo, fast gradient-echo and a fluoroscopic echo-planar sequence, were available. Procedural steps were described and illustrated as a guide for the radiologist actively collaborating with the orthopaedic surgeon.

Results: Five separate procedural steps were defined, describing the imaging action and the radiologist's focus related to the clinical action. These procedural steps included patient positioning, static imaging to evaluate hip congruency and factors impeding reduction, dynamic stress testing and reducing the hip while using dynamic motion MR imaging sequences to visualise reduction or dislocation, cast application with intermittent imaging confirmation of the femoral head position, and postprocedural static imaging.

Conclusion: The role of the radiologist was well-defined during each procedural step of the MR imaging-guided closed reduction focusing on the use of specific sequences and image interpretation. Knowledge of these procedural steps may be helpful for efficient collaboration with the orthopaedic surgeon and successful MR imaging-guided treatment of DDH.

Keywords: closed hip joint reduction, developmental dysplasia of the hip, hip dislocation, imaging-guided closed reduction, magnetic resonance imaging-guided procedure

Singapore Med J 2009; 50(4): 407-411

INTRODUCTION

Developmental dysplasia of the hip (DDH) includes frank dislocation (luxation), partial dislocation (subluxation), instability of the femoral head and acetabular dysplasia. Newborn screening surveys have suggested a prevalence as high as one in 100 newborns with evidence of instability, and one to one and a half cases of dislocation per 1,000 newborns.⁽¹⁾ Treatment is directed at reducing the subluxed or dislocated hip and establishing normal congruence between the femoral head and the acetabulum. Treatment options with prolonged immobilisation of the hips include the application of a Pavlik harness, or closed and open reduction procedures.

Closed reduction with casting is commonly performed in the operating room, often with the use of peroperative ultrasonography, fluoroscopic guidance and/or arthrography. Postprocedural computed tomography (CT) or magnetic resonance (MR) imaging is frequently performed to provide transectional imaging confirmation of the position of the femoral heads after casting. This closed reduction procedure is usually performed repetitively every two or three months because the baby quickly outgrows the cast extending over the abdomen, pelvis and upper legs. MR imaging-guided closed reduction is a valuable alternative for treating DDH. Although its feasibility has been reported to involve close collaboration between the radiologist and orthopaedic surgeon during the procedure, MR imaging-guided closed reduction is not yet widely used.^(2,3) The goal of this report was to describe and illustrate the radiological aspects and procedural steps of MR imaging-guided closed reduction for the treatment of DDH.

METHODS

Procedures were performed using a 0.5T open MR unit

Department of Radiology, Stanford University Medical Center, 300 Pasteur Dr, Stanford, CA 94305, USA

Vandevenne JE, MD
Research Fellow

Butts Pauly K, PhD
Associate Professor at the Lucas Center for MR Spectroscopy and Imaging

Lang PK, MD, MBA
Assistant Professor

Department of Orthopaedic Surgery

Lincoln T, MD
Assistant Professor

Rinsky L, MD
Clinical Professor

Correspondence to:
Dr Jan E Vandevenne
Department of Radiology,
Ziekenhuizen Oost-Limburg,
Schiepse Bos 6,
B-3600 Genk,
Belgium
Tel: (32) 8932 4542
Fax: (32) 8932 7926
Email: vdvennej@hotmail.com

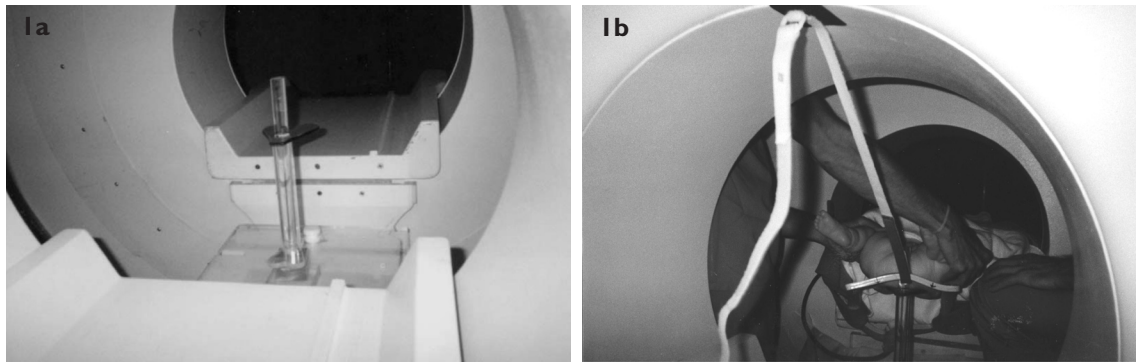


Fig. 1 Set-up of the hip spica table and positioning of the baby within the open MR imaging unit. (a) Photograph of the custom-built, plastic hip spica table placed in the centre of the double doughnut-shaped open MR imaging unit. The spica table is composed of a horizontal base plate, a round vertical pole and a small horizontal plate. The base plate is fitted on the connecting bar between the two doughnut rings of the magnet. On this base, the vertical pole is constructed bearing a small horizontal teardrop-shaped plate to support the baby's buttocks. The latter plate is available in several sizes adjustable to the patient and at the same horizontal level as the patient table proper of the MR imaging unit. (b) Photograph shows that the baby's upper body (shoulder blades and head) is placed on the MR patient table proper, which is only partially moved towards the centre of the magnet while the buttocks rest on the teardrop-shaped plate in the centre of the magnet. Note the easy access to the baby for two physicians performing the Ortolani manoeuvre in an attempt to reduce the dislocated hip. The quadrangular, flexible surface coil is positioned immediately below the baby's hips using Velcro strips attached to the magnet, and not interfering with the clinical stress testing. During casting, straps had to be detached to lower the coil and allow for circumferential casting of the pelvis and abdomen. Intermittently, the straps are reattached to reposition the coil close to the baby's hips for imaging during casting.

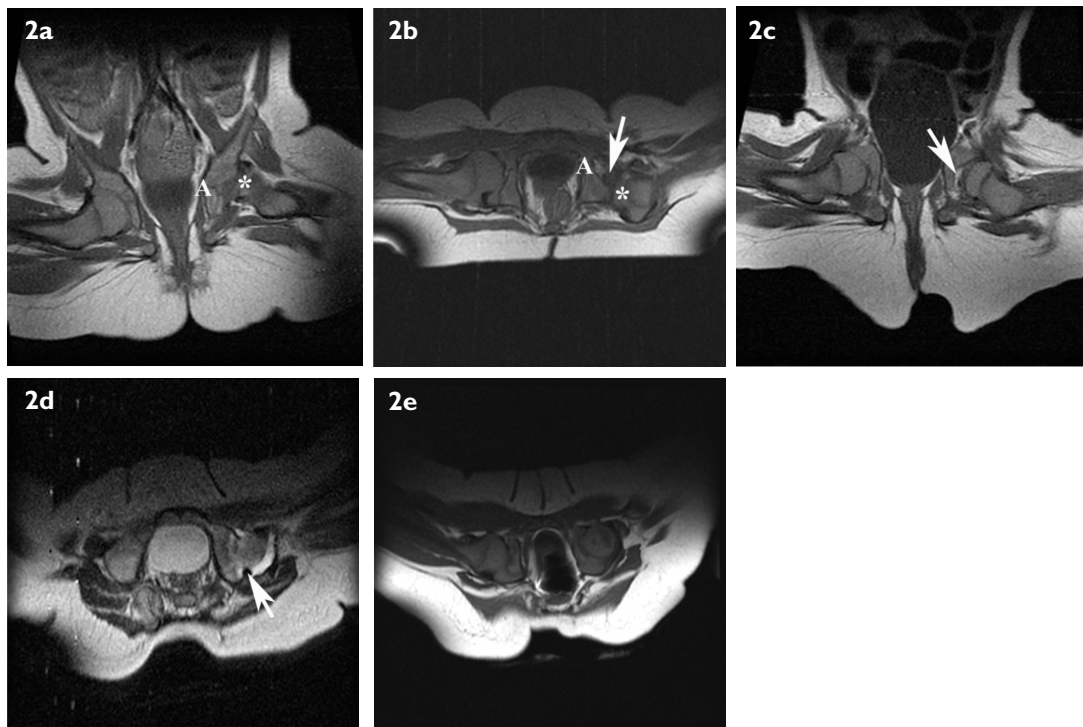


Fig. 2 A ten-month-old female infant diagnosed at birth with bilateral hip dysplasia. Successful treatment of the right hip was achieved with a Pavlik harness, but the left hip persisted to be dislocated even after bracing. Closed reduction of the left hip with spica casting was performed using MR imaging guidance. (a) Coronal and (b) axial spin-echo T1-W MR images show the posterosuperiorly dislocated left femoral head (*). The left acetabulum (A) is relatively shallow. On the axial image, low-signal intensity soft tissue is present within the acetabulum presumed to represent inverted labrum and/or elongated ligamentum teres (arrow). (c) Coronal spin-echo T1-W MR image after closed reduction shows that the left proximal femoral epiphysis is now well-centred within the acetabulum, although some fatty tissue remained interposed between the cartilaginous femoral head and acetabulum (arrow). The left femoral head is slightly smaller compared to the right. (d) Axial spin-echo T2-W MR image after closed reduction shows marked joint effusion and a thickened, blunted labrum posteriorly (arrow). (e) Axial spin-echo T1-W MR image performed three months later at a recast procedure in the open MR unit shows that the left proximal femoral epiphysis is deeply seated within and well covered by the acetabulum. The interposing fatty tissue is no longer present. This was the last cast that had to be applied, subsequently followed by a period of bracing. The five-year clinical and radiographical follow-up showed no residual sign of hip dysplasia.

Table I. Procedural steps for MR-assisted closed reduction treatment of dysplasia of the hip.

Procedural step	Clinical action	Imaging action (axial and coronal planes)	Radiologist's focus
Patient positioning	General anaesthesia.	Coil placement below the buttocks, attached with Velcro straps to the wall of the MR unit.	Patient safety, secure positioning of shoulder blades resting on MR table and buttocks resting on hip spica table.
Static imaging	None.	SET1 (TR/TE 500/15 msec) FSET2 (TR/TE 3500/15 msec)	Hip congruency, shape of acetabulum, position of femoral head, and factors impeding reduction: inverted labrum, short adductor tendon, interposing pulvinar, elongated ligamentum teres, hydrlops.
Dynamic stress testing and reducing the hip	Barlow and Ortolani manoeuvres, determining the safe zone*, finding a stable hip position. Adductor tenotomy if required.	FSET1 (500/27 msec): 3 ima/18sec FGR T1 (14.7/7 msec): 1 ima/2sec EPI T1 (40/15 msec): 3.5 ima/sec EPI was reconstructed to 12 ima/sec resulting in a fluoroscopic kind of image viewing.	Hip congruency, visualise reduction or dislocation of femoral head when eliciting a 'clunk' clinically, factors impeding complete reduction (see above in this table) or sustained reduction (too shallow acetabulum).
Cast application	Cast application inside the MR unit.	Lowering the coil for casting, and intermittently repositioning the coil for imaging FSET1 (500/27 msec)	Confirming well-centred position of femoral head in acetabulum.
Static imaging	None.	SET1 (TR/TE 500/15 msec) FSET2 (TR/TE 3500/15 msec)	Postprocedural imaging to evaluate hip congruency and factors impeding complete reduction (see above).

*The safe zone is a clinically determined range of adduction-abduction angles where the flexed hip is felt to be in a stable position. It is safe to cast the hip in this position. Too much adduction may result in subluxation, too much abduction may result in ischaemia of the femoral head.

(Signa-SP, GE Medical Systems, Milwaukee, WI, USA) placed in a fully licensed operating suite. This MR imaging system had a double doughnut hardware configuration with a central vertical opening, giving the radiologist and orthopaedic surgeon direct access from both sides to the infant. Liquid crystal panels displayed the MR images within this vertical opening. Headphones with speakers and a microphone ensured direct verbal communication between the physicians inside the MR imaging suite and the technician at the MR console. A hip spica table was custom-built using epoxy ethylene plastic (Lucite, DuPont Company, Wilmington, DE, USA), adjustable to patient anatomy (size of the hips, length of the trunk) (Fig. 1a). A quadrangular surface transmit receiver coil was used, hanging directly under the baby's hips (Fig. 1b).

On this 0.5T MR unit, three rapid sequences were available for dynamic motion MR imaging during clinical testing of the hips. The shorter the acquisition time, the lower was the spatial resolution and the anatomical detail. A fast spin echo (FSE) T1-weighted sequence provided up to three adjacent images in 18 seconds (TR/TE 500/27 msec, 24 cm × 24 cm field-of-view, matrix of 256 × 128, 5-mm slice thickness). The fast gradient echo (FGR) sequence produced one image every two seconds in a loop of 100 images, with the option of switching the imaging plane in the coronal and axial direction (TR/TE 14.7/7 msec, 28 cm × 28 cm field-of-view, matrix of 256 × 192, 10-mm slice thickness). The 'fluoroscopic' multishot echo planar imaging (EPI) MR imaging sequence (TR/TE 40/15) provided 3.5 images per second reconstructed at

12 images per second. In the latter sequence, the imaging plane could interactively be redirected in the x-, y- and z-axis without interrupting image acquisition. As a guide for the radiologist who was actively collaborating with the orthopaedic surgeon during the whole MR imaging-guided closed reduction procedure, procedural steps were defined from the entrance of the patient to the final discharge from the operating suite. For each step, specific imaging action and the radiologist's focus related to the clinical action was stipulated.

RESULTS

The procedural steps are summarised in Table I. Note that all procedural steps were performed inside the MR imaging unit. The 'fluoroscopic' multishot EPI sequence and the FGR sequence were used to demonstrate dislocation and reduction of the femoral head during clinical stress testing, but further anatomic detail was limited. Although the presence of interposing soft tissue between the femoral head and the acetabulum could be suspected, the spatial resolution of these sequences was too low to differentiate the nature of the interposing soft tissue. The FSE sequence provided higher anatomical detail at the cost of imaging time. This sequence visualised the degree of acetabular and femoral head dysplasia more clearly. Interposing soft tissue structures, such as an enlarged pulvinar, interposing adductor tendon or elongated ligamentum teres could be recognised (Figs. 2–4). Conventional spin echo sequences were used to confirm the position of the hips prior to and after the casting. These images provided the highest spatial

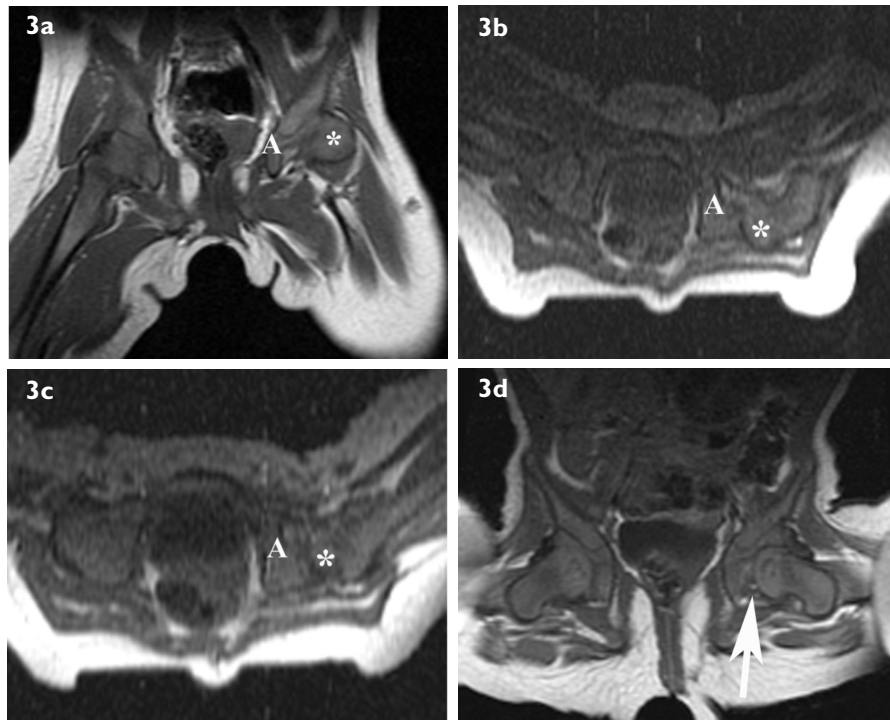


Fig. 3 A nine-month-old infant diagnosed at the age of eight months with DDH on the left side. A three-week Pavlik harness treatment was unsatisfactory and closed reduction was performed within the open MR unit. (a) Coronal spin-echo T1-W MR image shows the posterosuperiorly dislocated left femoral head (*) and the shallow left acetabulum (A). (b & c) Axial fast spin-echo T1-W dynamic motion MR images performed during the Ortolani reduction manoeuvre show a repositioning of the proximal femoral epiphysis from posteriorly into the acetabular cup (A). Coverage of the proximal femoral epiphysis (*) is poor posteriorly and a tendency towards posterior subluxation is found. Adductor tenotomy was performed within the open MR imaging unit to allow for sufficient abduction and the tendency for subluxation was no longer present. Note the flattening of the buttocks resting on the horizontal plate of the plastic spica table within the MR imaging unit. (d) Coronal spin-echo T1-W MR image after closed reduction shows that the left proximal femoral epiphysis is now well-centred within the acetabulum, although a relatively large amount of fatty tissue remained interposed between the acetabulum and medial side of the femoral head consistent with pulvinar hypertrophy (arrow). At three-month follow-up, a new cast was applied, followed by bracing for one year. Six-year follow-up clinical examination was unremarkable and radiographical follow-up only demonstrated a slight irregularity of the left acetabulum.

and contrast resolution, and were useful in evaluating labral pathology in addition to the other findings mentioned earlier (Figs. 2 & 3).

DISCUSSION

MR imaging is the preferred modality for visualising the anatomic structures of the paediatric hip joint in general and specifically in DDH, and has been used to visualise intra-articular structures, to assess articular relations in the hip joint and to predict reduction.^(4,5) Using an open magnet configuration, dynamic motion imaging of the hip joint to analyse stability and to visualise dislocation and reduction has been reported.⁽²⁾ After closed or open reduction procedures, MR imaging was useful to confirm reduction and to evaluate soft tissue interposition.⁽⁶⁾ The MR imaging-guided closed reduction procedure described in this report was developed by combining these capabilities of MR imaging to visualise the dysplastic hip joint pre-treatment, during clinical testing and reduction, and post-treatment. MR imaging-guidance of closed reduction procedures in close collaboration with the orthopaedic surgeon

performing clinical stress testing, adductor tenotomy and casting added the extra dimension of treating patients within the MR imaging unit. Hence, the confirmation of its name, “magnetic resonance treatment” (MRT).

MR imaging-guided treatment of DDH had important advantages for the patients. This transectional imaging modality is capable of providing images of the osteoarticular relations of the hip joint with high temporal resolution during hip reduction and clinical testing of hip stability, and images with anatomical details were provided once the femoral head was well-centred in the acetabulum. Arthrography, intraoperative fluoroscopy and postoperative CT were not required. This is valuable particularly in patients of this age group, because children are considerably more sensitive to radiation than adults and also have a longer life expectancy, resulting in a larger window of opportunity for expressing radiation damage. Ultrasonography has been reported as an alternative modality for imaging during and after closed reduction. It was valuable during clinical testing of the safe zone, but had its limitations for visualisation of the hip joint

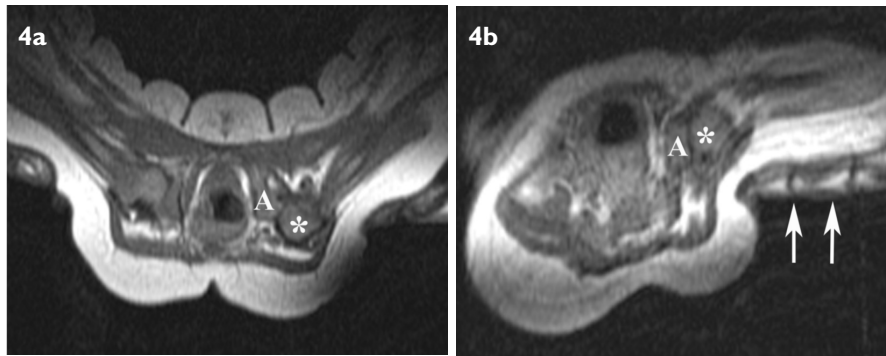


Fig. 4 A two-month-old infant diagnosed at the age of four weeks with left hip dysplasia. (a & b) Axial fast spin-echo T1-W dynamic motion MR images performed during the Ortolani reduction manoeuvre show a partial reduction of the posteriorly-dislocated femoral head (*). Note the fingers (arrows) of the physician performing pressure in an attempt to reposition the femoral head within the acetabulum (A). A stable reduction could not be achieved and this patient had to proceed to open surgical reduction.

during casting and after the cast had been applied. In these cases, a lateral fenestration or a larger perineal opening in the cast was created to allow for visualisation of the hip joint at postoperative and follow-up ultrasonographical examinations.⁽⁷⁾

MR imaging-guided closed reduction has not been widely used. There may be several reasons for this, which include the availability of the MR imaging unit utilised, the interest of the radiologist and orthopaedic surgeon to collaborate, and the procedural time. Although the closed reduction procedure was described using a double doughnut-shaped MR imaging unit with a vertically open gap, other open configurations of MR imaging units with sufficient access to these small-sized patients might be used provided that specific hip-holders are built, and adequate imaging coils and sequences are available. Collaboration of the radiologist with the orthopaedic surgeon may be stimulated based on sound knowledge of the procedural steps and the expected imaging findings, as reported in this paper. Procedural time was reported to be the same for repeat castings and up to 50% longer for first closed reduction procedures, as compared to fluoroscopic-guided procedures.⁽³⁾

The MR technique during the closed reduction procedure could be further improved upon in terms of coil development and sequence development. The MR imaging coil needed to be removed intermittently during casting. An adjusted coil design incorporated within the hip spica table would be helpful in improving the MR image quality and not interfering with the casting, such as a circular coil inside the vertical pole or a surface coil inside the horizontal plate supporting the buttocks. Developing MR imaging sequences to evaluate the perfusion of the femoral head in the abducted hip joint could be extremely helpful for predicting ischaemia of the femoral head early on, imposing to reposition the femoral head within the same procedure. Promising results have been reported in piglet

hip joints without the use of intravenous gadolinium.⁽⁸⁾ In conclusion, the role of the radiologist was well-defined during each procedural step of the MR imaging-guided closed reduction focusing on the use of specific sequences and image interpretation. Knowledge of these procedural steps may be helpful for efficient collaboration with the orthopaedic surgeon and the successful MR imaging-guided treatment of DDH.

ACKNOWLEDGEMENTS

This research was supported by research grants from the Royal Belgian Society of Radiology and the Research and Education Fund of the European Congress of Radiology.

REFERENCES

1. Committee on Quality Improvement, Subcommittee on Developmental Dysplasia of the Hip. American Academy of Pediatrics. Clinical practice guideline: early detection of developmental dysplasia of the hip. *Pediatrics* 2000; 105:896-905.
2. Tennant S, Kinmont C, Lamb G, Gedroyc W, Hunt DM. The use of dynamic interventional MRI in developmental dysplasia of the hip. *J Bone Joint Surg Br* 1999; 81:392-7.
3. Lincoln TL, Vandevienne JE, Rinsky LA, Butts K, Lang P. Dynamic magnetic resonance guided treatment of developmental dysplasia of the hip. *J Pediatr Orthop B* 2000; 11:279-83.
4. Dillon JE, Connolly SA, Connolly LP, Kim YJ, Jaramillo D. MR imaging of congenital/developmental and acquired disorders of the pediatric hip and pelvis. *Magn Reson Imaging Clin N Am* 2005; 13:783-97.
5. Kashiwagi N, Suzuki S, Kasahara Y, Seto Y. Prediction of reduction in developmental dysplasia of the hip by magnetic resonance imaging. *J Pediatr Orthop* 1996; 16:254-8.
6. Westhoff B, Wild A, Sella K, Krauspe R. Magnetic resonance imaging after reduction for congenital dislocation of the hip. *Arch Orthop Trauma Surg* 2003; 123:289-92.
7. van Douveren FQ, Pruijs HE, Sackers RJ, Nieuwstein RA, Beek FJ. Ultrasound in the management of the position of the femoral head during treatment in a spica cast after reduction of hip dislocation in developmental dysplasia of the hip. *J Bone Joint Surg Br* 2003; 85:117-20.
8. Jaramillo D, Connolly SA, Vajapeyam S, et al. Normal and ischemic epiphysis of the femur: diffusion MR imaging study in piglets. *Radiology* 2003; 227:825-32.