

Surfactant therapy in acute respiratory distress syndrome due to hydrocarbon aspiration

Horoz O O, Yildizdas D, Yilmaz H L

ABSTRACT

Hydrocarbon aspiration causes acute lung injury, which may lead to acute respiratory distress syndrome. Surfactant has been shown to be beneficial in experimentally-induced hydrocarbon-associated acute respiratory distress syndrome. However, there has not been a clinical study evaluating the effect of surfactant application on hydrocarbon aspiration in humans. We report a 17-month-old boy with acute respiratory distress syndrome due to hydrocarbon aspiration and was successfully treated with surfactant application.

Keywords: acute respiratory distress syndrome, hydrocarbon aspiration, surfactant therapy

Singapore Med J 2009;50(4):e130-e132

INTRODUCTION

Hydrocarbons are organic substances that contain carbon and hydrogen, and are found in liquid form at room temperature. All petroleum distillates, including kerosene, gasoline, mineral seal oils and naphtha are hydrocarbons.⁽¹⁾ Hydrocarbon poisoning continues to be an important cause of poisoning-related morbidity and mortality in developing countries. Most poisonings were accidental and occurred in the under-five age group.⁽²⁾ Hydrocarbon aspiration (HA) is known to cause significant pulmonary disease by inducing an inflammatory response and haemorrhagic exudative alveolitis, and loss of surfactant function. The major pulmonary complications of hydrocarbon aspiration include asphyxia, necrotising chemical pneumonitis, lipoid pneumonia, and haemorrhagic pulmonary oedema, which quickly progresses to shock and respiratory arrest.⁽³⁾ The mainstay of HA is supportive therapy. The use of steroids is not fully supported in the literature.⁽⁴⁾ We report a 17-month-old boy with a HA-associated acute respiratory distress syndrome (ARDS) successfully treated with exogenous surfactant.

CASE REPORT

A 17-month-old boy was admitted to the Paediatric Emergency Department of Cukurova University, Faculty

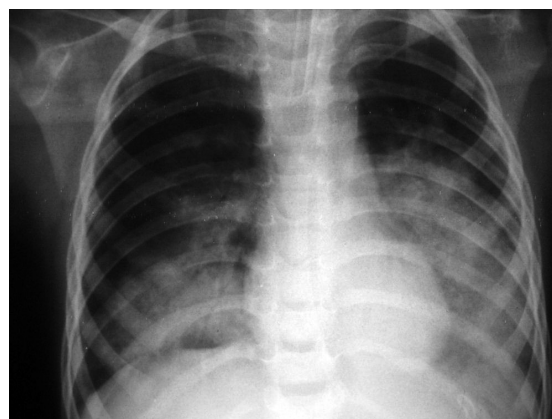


Fig. 1 Chest radiograph shows bilateral alveolar consolidations at the lower lobes, predominantly in the left lung.

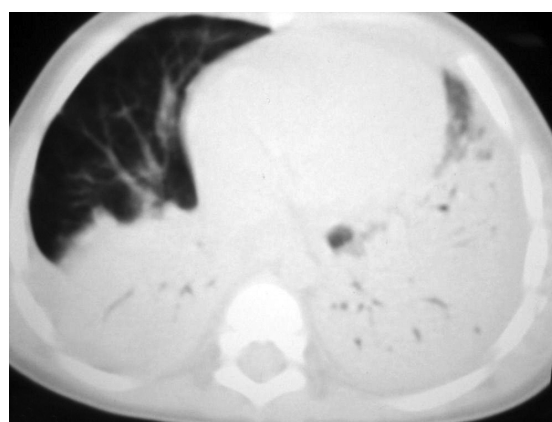

Fig. 2 CT image of the thorax shows consolidation of the lung, predominantly in the gravity-dependent areas.

of Medicine, Balcali Hospital, Turkey. He had cough, and gradually increased respiratory failure occurred following accidental ingestion of cleaning naphtha. His past medical history was unremarkable. At the time of admission, he had been found unconscious with tachypnoea (40/min) and cyanosis. Due to the severity of the respiratory failure, the patient was immediately intubated and transferred to the Paediatric Intensive Care Unit (PICU). At admission, his body temperature was 37.5°C, heart rate 183/min and blood pressure 80/40 mmHg. Lung examination revealed coarse breath sounds with inspiratory and expiratory crackles throughout, and no wheezing. His cardiac examination was normal except

Division of Paediatric Intensive Care, Department of Pediatrics, Faculty of Medicine, Cukurova University, 01330 Adana, Turkey

Horoz OO, MD
Consultant

Yildizdas D, MD
Associate Professor
and Senior Consultant

Paediatric
Emergency Care

Yilmaz HL, MD
Associate Professor
and Consultant

Correspondence to:
Dr Dincer Yildizdas
Tel: (90) 322 338 7441
Fax: (90) 322 338 7441
Email: dyildizdas@
cu.edu.tr

for tachycardia. He had positive peripheral pulses with 4 secs of capillary refill. Central venous pressure was 11 cmH₂O. Arterial blood gases obtained immediately before intubation and on room air were as follows: pH 7.27, arterial carbon dioxide tension (PaCO₂) 35 mmHg; arterial oxygen tension (PaO₂) 35 mmHg; arterial oxygen saturation (SaO₂) 75%, base excess (BE) -10 mM; and bicarbonate (HCO₃) 12 mEq/L. Blood count and routine serum biochemistry tests were normal.

Chest radiographs showed bilateral alveolar consolidations at the lower lobes, predominantly in the left lung (Fig. 1). His electrocardiogram showed a sinus tachycardia. Thoracic computed tomography revealed consolidation of the lung predominantly in the gravity-dependent areas (Fig. 2). After the patient was admitted to PICU, pressure-controlled mode ventilation was initiated (fraction of inspired oxygen [FiO₂] 1.0; positive end-expiratory pressure [PEEP] 8 cmH₂O; peak inspiratory pressure 30 cmH₂O; respiratory rate 30/min). Dopamine was immediately started at a dose of 10 µg/kg/min and titrate of 15 µg/kg/min to restore the normal blood pressure level. Prophylactic antibiotic therapy was also initiated with IV ceftriaxone 100 mg/kg/day twice daily. Despite this management, on the third day of admission, worsening in the patient's oxygenation, evidenced by a decrease in PaO₂/FIO₂ ratio to 80, and frequent desaturation to as low as SaO₂ < 80%, occurred. At that time, blood gases analysis was as follows: pH 7.27; PaCO₂ 35 mmHg; PaO₂ 40 mmHg; SaO₂ 75%; BE -10mM; HCO₃ 16 mEq/L. Although recruitment manoeuvres were performed, no improvement was obtained in the patient's oxygenation status.

At this point, a decision was made to instill surfactant intratracheally. Surfactant (Survanta, Abbott, USA) was given at a dose of 200 mg/kg intratracheally. Within two hours, the patient dramatically responded to this treatment, with improvement in blood gases parameters as follows: PaO₂ increased from 40 to 90 mmHg, SaO₂ increased from 75% to 95%. 12 hours later, as we observed a minimal decrease (from 95% to 88%) in SaO₂, we repeated the surfactant instillation using the same dose. After the second surfactant application, the patient's respiratory and haemodynamic status had stabilised. Control chest radiograph also showed a significant resolution of the pulmonary infiltrates (Fig. 3). 24 hours after the last surfactant application, dopamine was stopped and the patient was subsequently weaned from the mechanical ventilation. Recovery was complete, and he discharged from PICU on the 18th day of admission, without any sequelae.

DISCUSSION

The respiratory system is the main target organ

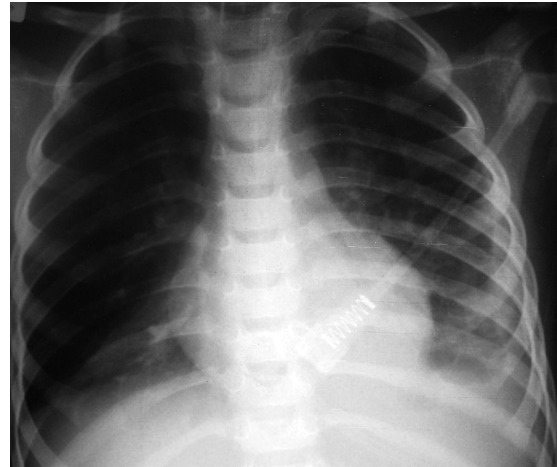


Fig. 3 Control chest radiograph shows a significant resolution of pulmonary infiltrates post surfactant therapy.

affected following HA in children.⁽⁵⁾ The major pulmonary complications of HA include asphyxia, necrotising chemical pneumonitis, lipoid pneumonia, and haemorrhagic pulmonary oedema, which quickly progresses to shock and respiratory arrest.⁽³⁾ While multiple factors may initiate the formation of the protein-rich inflammatory pulmonary oedema that is the hallmark of ARDS,⁽⁶⁾ the final common pathway in ARDS may be surfactant deficiency. Because the mechanism of injury disrupts pulmonary surfactant, instillation of an exogenous surfactant is a theoretically-plausible therapy. Indeed, the benefit of surfactant application in ARDS has been demonstrated in animal models.⁽⁷⁻⁹⁾ However, in trials conducted in the adult population with ARDS, exogenous surfactant administration was not shown to be associated with improved oxygenation compared to controls, and did not alter the mortality rate.⁽¹⁰⁻¹²⁾ In contrast, in the paediatric population, surfactant application has been demonstrated to be associated with improvement in oxygenation and most ventilation-associated parameters.⁽¹³⁻¹⁶⁾

Current therapy in HA is primarily supportive with mechanical ventilation and PEEP. The role of steroids in the treatment of chemical pneumonia, following accidental naphtha ingestion, is still controversial.^(4,17) Patwari and Michelson reported a case of HA which developed ARDS and improved after administration of inhaled nitric oxide. However, as they also suggested, further studies are needed to determine the effect of inhaled nitric oxide in the management of ARDS due to HA.⁽¹⁸⁾ The influence of surfactant application on survival and pulmonary functions in hydrocarbon-induced ARDS was only investigated in an experimental study by Widner et al.⁽⁸⁾ They observed a significant improvement in survival and pulmonary functions, following surfactant

instillation in acute lung injury experimentally induced with hydrocarbon in animals. Similarly, in the present case of ARDS due to HA, pulmonary functions of the patient dramatically improved following surfactant application, and he was ultimately discharged with complete recovery. To the best of our knowledge, this is the first paper reporting the efficacy of surfactant instillation in HA in humans.

In summary, data related to the treatment of HA is limited, and the mortality rate has remained at approximately 2%, since the early 1960s, despite improvements in ventilatory support and adjunctive therapies.⁽¹⁹⁾ Surfactant seems to be a beneficial treatment option in patients with ARDS due to HA. However, further clinical studies are needed to confirm the efficacy of surfactant application in children who suffer from this relatively common problem.

REFERENCES

- Osterhoudt KC, Burns Ewald M, Shannon M, Henretig FM. Toxicologic emergencies. In: Fleisher GR, Ludwig S, Henretig FM; eds. *Textbook of Pediatric Emergency Medicine*. 5th ed. Philadelphia: Lippincott Williams and Wilkins, 2006: 951.
- Jayashree M, Singhi S, Gupta A. Predictors of outcome in children with hydrocarbon poisoning receiving intensive care. *Indian Pediatr* 2006; 43:715-9.
- Karlson KH Jr. Hydrocarbon poisoning in children. *South Med J* 1982; 75:839-40.
- Steele RW, Conklin RH, Mark HM. Corticosteroids and antibiotics for the treatment of fulminant hydrocarbon aspiration. *JAMA* 1972; 219:1434-7.
- Lifshitz M, Sofer S, Gorodischer R. Hydrocarbon poisoning in children: a 5-year retrospective study. *Wilderness Environ Med* 2003; 14:78-82.
- Petty TL. Acute respiratory distress syndrome (ARDS). *Dis Mon* 1990; 36:1-58.
- van Daal GJ, So KL, Gommers D, et al. Intratracheal surfactant administration restores gas exchange in experimental adult respiratory distress syndrome associated with viral pneumonia. *Anesth Analg* 1991; 72:589-95.
- Widner LR, Goodwin SR, Berman LS, et al. Artificial surfactant for therapy in hydrocarbon-induced lung injury in sheep. *Crit Care Med* 1996; 24:1524-9.
- Kerr CL, Ito Y, Manwell SE, et al. Effects of surfactant distribution and ventilation strategies on efficacy of exogenous surfactant. *J Appl Physiol* 1998; 85:676-84.
- Anzueto A, Baughman RP, Guntupalli KK, et al. Aerosolized surfactant in adults with sepsis-induced acute respiratory distress syndrome. Exosurf Acute Respiratory Distress Syndrome Sepsis Study Group. *N Engl J Med* 1996; 334:1417-21.
- Spragg RG, Lewis JF, Walrath HD, et al. Effect of recombinant surfactant protein C-based surfactant on the acute respiratory distress syndrome. *N Engl J Med* 2004; 351:884-92.
- Davidson WJ, Dorscheid D, Spragg R, et al. Exogenous pulmonary surfactant for the treatment of adult patients with acute respiratory distress syndrome: results of a meta-analysis. *Crit Care* 2006; 10: R41.
- Willson DF, Zaritsky A, Bauman LA, et al. Instillation of calf lung surfactant extract (calfactant) is beneficial in pediatric acute hypoxemic respiratory failure. Members of the Mid-Atlantic Pediatric Critical Care Network. *Crit Care Med* 1999; 27:188-95.
- López-Herce J, de Lucas N, Carrillo A, Bustinza A, Moral R. Surfactant treatment for acute respiratory distress syndrome. *Arch Dis Child* 1999; 80:248-52.
- Möller JC, Schaible T, Roll C, et al. Surfactant ARDS Study Group. Treatment with bovine surfactant in severe acute respiratory distress syndrome in children: a randomized multicenter study. *Intensive Care Med* 2003; 29:437-46.
- Hermon MM, Golej J, Burda G, et al. Surfactant therapy in infants and children: three years experience in a pediatric intensive care unit. *Shock* 2002; 17:247-51.
- Gurkan F, Bosnak M. Use of nebulized budesonide in two critical patients with hydrocarbon intoxication. *Am J Ther* 2005; 12:366-7.
- Patwari PP, Michelson K. Use of inhaled nitric oxide for hydrocarbon aspiration. *Chest* 2005; 128:445S.
- Arena JM. Hydrocarbon poisoning—current management. *Pediatr Ann* 1987; 16:879-83.