

A “hard” neck lump

Leong S C, Karkos P D

ABSTRACT

We discuss a case of an asymptomatic cervical rib presenting as a hard neck lump in a 56-year-old woman. Cervical rib is a common condition associated with thoracic outlet syndrome. The diagnosis, investigation and management of this condition is an important differential diagnosis that an ENT surgeon should know in a patient presenting with a neck mass.

Keywords: cervical rib, neck lump, thoracic outlet syndrome

Singapore Med J 2009;50(4):e141-e142

INTRODUCTION

Cervical rib is a congenital anomaly which is usually asymptomatic. It occurs in 0.4% of the population, of whom 70% are bilateral.⁽¹⁾ Cervical rib is symptomatic in only 10% of cases where it causes compression of the brachial plexus, subclavian artery and subclavian vein at the thoracic outlet, i.e thoracic outlet syndrome. Cervical rib varies from unilateral enlargement of the transverse processes of C7 to bilateral completely developed ribs. Occasionally, fibrous bands connecting the tip of a cervical rib with the first thoracic rib may also present as thoracic outlet syndrome.

CASE REPORT

A 56-year-old woman was referred with a hard palpable mass in the left anterior triangle. It was detected incidentally on routine examination, but because she was a life-long smoker, her general practitioner was concerned that this may be a sinister lesion. A complete neurological and musculoskeletal examination of the upper limb was normal, as was a comprehensive ear, nose and throat work-up. The chest radiograph showed bilateral, well-formed cervical ribs, with the left being more prominent (Fig. 1).

DISCUSSION

A cervical rib is a supernumerary or accessory rib arising from the seventh cervical vertebra. It occurs more commonly in females than in males, but is usually asymptomatic. Unlike a cervical rib which is benign and may not require any treatment, other causes of a hard neck lump should be thoroughly investigated. In a patient with a history of smoking, cervical lymphadenopathy secondary

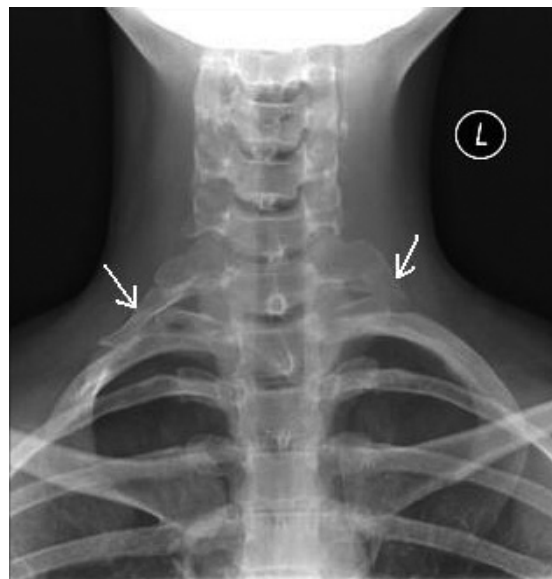


Fig. 1 Frontal radiograph shows bilateral cervical ribs (arrows).

to metastatic upper aerodigestive tract squamous cell carcinoma should be regarded as a likely diagnosis, until proven otherwise. Furthermore, lymphadenopathy from distant carcinoma, such as the breast and lung, should also be suspected. Other causes of a hard neck lump include thyroid lesions such as anaplastic carcinoma. In these instances, ultrasonography and fine-needle aspiration of the neck lump would be the preferred first investigation, in addition to a thorough examination of the ears, nose and throat. On further correspondence with her general practitioner, it was revealed that this patient had lost considerable weight from dieting in the past year. This would explain the recent detection of the cervical rib, where previously the bony protuberance would have been masked by thick cutaneous tissues.

While the cervical rib in this patient was totally innocuous, it can cause thoracic outlet syndrome by increasing the angulation of the subclavian artery and first thoracic nerve over the first rib.⁽²⁾ Clinical manifestations of thoracic outlet syndrome may include pain in the neck and shoulder which radiates into the upper extremity, paresis or paralysis of brachial plexus innervated muscles, paraesthesias, oedema and even ischaemia of the upper limb. Clinical examination may reveal excessive sweating, cyanosis or coldness of the fingers with wasting of the small muscles of the hand. The shoulder on the affected side may be lower or both shoulders may sag. An abnormally-elevated subclavian

**Department of
Otolaryngology,
Warrington Hospital,
Lovely Lane,
Warrington,
Cheshire WA5 1QG,
The United Kingdom**

Leong SC, MRCSE,
DO-HNS,
Specialist Registrar

Karkos PD, AFRCS,
MPhil,
Specialist Registrar

Correspondence to:
Mr Samuel Leong
Tel: (44) 7 7959 63905
Fax: (44) 2 9208 74093
Email: samuelleong@
tiscali.co.uk

artery may be evident above the clavicle. The thoracic outlet stress test is performed by placing the hand behind the head. This produces numbness of the fingers in 80% of cases. The elevated arm stress test is an alternative clinical assessment. This is performed by holding the upper extremity in the "hands-up" position. In this position, the patient then repeatedly flexes and extends the fingers for three minutes, and a positive test is when the patient is unable to complete this duration. However, this test is physically demanding and thus of limited value in the elderly or ill patient.⁽³⁾ The Adson test causes pain and diminution of the radial pulse when the head is extended and bent to the opposite side, and the patient takes a deep breath and holds it, followed by rotation to stretch or tether the brachial plexus and artery between the anterior and middle scalenes.

Symptomatic cervical rib can be managed conservatively with ultrasound, electrical stimulation, superficial heat, stretching exercises, postural correction exercises, and strength and endurance exercises.⁽⁴⁾ Mobilisation and manipulation may be performed by a physiotherapist, osteopath or chiropractor. The aim is to release tight, contracted or restricted vertebral segments and soft tissue. Surgery involves excision of

the cervical rib as well as the first thoracic rib. In some patients, reduction of large, pendulous breasts may also be beneficial.⁽⁵⁾ Due to the relatively uncommon presentation of cervical rib, patients presenting with a hard neck lump should be thoroughly assessed to rule out any sinister pathology. It is important for both general practitioners and ENT surgeons to be able to examine for thoracic outlet syndrome in a patient presenting with a hard neck lump. Given that patients presenting with neck pain are more common, the clinical tests discussed would be an invaluable clinical tool in the armamentarium of any ENT specialist.

REFERENCES

1. Huang JH, Zager EL. Thoracic outlet syndrome. *Neurosurgery* 2004; 55:897-902.
2. Sanders RJ, Hammond SL, Rao NM. Diagnosis of thoracic outlet syndrome. *J Vasc Surg* 2007; 46:601-4.
3. Plewa MC, Delinger M. The false-positive rate of thoracic outlet syndrome shoulder maneuvers in healthy subjects. *Acad Emerg Med* 1998; 5:337-42.
4. Urschel HC, Kourlis H. Thoracic outlet syndrome: a 50-year experience at Baylor University Medical Center. *Proc (Bayl Univ Med Cent)* 2007; 20:125-35.
5. Barkhordarian S. First rib resection in thoracic outlet syndrome. *J Hand Surg (Am)* 2007; 32:565-70.