

Percutaneous transcatheter aortic valve replacement: first transfemoral implant in Asia

Chiam P T L, Koh T H, Chao V T T, Lee C Y, See Tho V Y, Tan S Y, Lim S T, Hwang N C, Sin Y K, Chua Y L

ABSTRACT

Surgical aortic valve replacement (AVR) is the standard of care for patients with symptomatic severe aortic stenosis (AS), providing relief of symptoms and prolonging survival. However, many patients are either denied or not offered surgery due to high surgical risk or non-operability for open AVR. The technology of percutaneous aortic valve implantation emerged in 2002, and has since evolved rapidly with satisfactory results. Currently, almost all the procedures are performed predominantly in Europe and North America. The first-in-Asia percutaneous transcatheter aortic valve implantation via the transfemoral route is described. A 77-year-old man with symptomatic severe AS and at high surgical risk was successfully treated, with sustained clinical improvement and satisfactory haemodynamic results at 30-day follow-up.

Keywords: aortic valve stenosis, bioprosthesis, cardiothoracic surgery, heart valve prosthesis implantation, percutaneous prosthesis implantation, percutaneous transcatheter aortic valve implantation

Singapore Med J 2009;50(5):534-537

INTRODUCTION

Surgical aortic valve replacement (AVR) is the standard of care for patients with symptomatic severe aortic stenosis (AS), providing relief of symptoms and prolonging survival.⁽¹⁾ However, a significant proportion of patients with symptomatic severe AS are either denied or not offered surgery due to high surgical risk or non-operability for open AVR.⁽²⁾ In 2002, the first human percutaneous aortic valve implantation was reported.⁽³⁾ This technology has since evolved tremendously. There are currently two transcatheter heart valves (THV) in clinical trials, with each achieving over > 1,500 implants, mainly in Europe and North America.⁽⁴⁾ This article describes the first ever percutaneous aortic valve implantation for symptomatic severe AS in Asia.

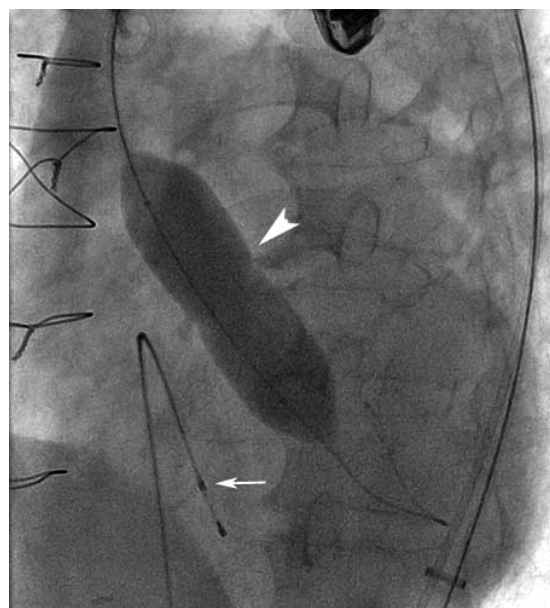


Fig. 1 Fluoroscopic image shows a valvuloplasty balloon (arrowhead). Arrow denotes pacing wire.

CASE REPORT

A 77-year-old man presented with symptomatic severe AS, and worsening functional status (NYHA [New York Heart Association] class II to III), over a six-month period. Past medical history included coronary artery bypass graft (CABG) surgery 15 years ago, percutaneous coronary intervention (stenting) to the left anterior descending artery (LAD) and ramus intermedius five years ago, hypertension, dyslipidaemia and ex-smoking. Echocardiographical assessment showed severe AS with an aortic valve area (AVA) of 0.6 cm² and a mean pressure gradient of 57 mmHg across the aortic valve. The aortic annulus measured 20 mm in diameter. There was mild to moderate mitral regurgitation (MR). Left ventricular ejection fraction (LVEF) was 40%. Cardiac catheterisation showed an occluded left internal mammary artery to the LAD graft, patent saphenous vein grafts to the obtuse marginal branch of the left circumflex artery and the right coronary artery. The LAD and ramus intermedius artery stents were patent. Mean pressure gradient was 53 mmHg with a calculated AVA of 0.6 cm². Iliofemoral angiogram showed patent non-tortuous

Department of
Cardiology,
National Heart
Centre,
17 Third Hospital
Avenue,
Singapore 168752

Chiam PTL, MBBS,
MMed, MRCP
Consultant

Koh TH, MBBS,
MMed
Senior Consultant
and Medical Director

Lee CY, MBBS,
MMed
Senior Consultant

Tan SY, MBBS,
MRCP
Consultant

Lim ST, MBBS,
MMed, MRCP
Senior Consultant
and Head

Department of
Cardiothoracic
Surgery

Chao VTT, MBBS,
FRCS
Consultant

Sin YK, MBBS,
FRCS
Senior Consultant
and Head

Chua YL, MBBS,
FRCS
Senior Consultant

Department of
Cardiothoracic
Anaesthesia

See Tho VY, MBBS,
MMed
Consultant

Hwang NC, MBBS,
FFARCSI
Senior Consultant
and Head

Correspondence to:
Dr Paul TL Chiam
Tel: (65) 6436 7540
Fax: (65) 6227 3562
Email: paul.chiam.
t.l@nhc.com.sg

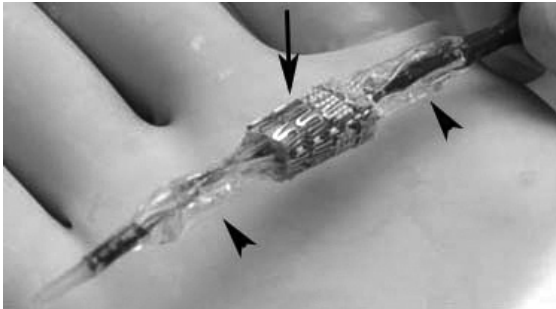


Fig. 2 Photograph shows the Sapien THV (arrow) crimped onto a balloon (arrowheads).

iliac and femoral arteries. The patient was assessed and declined for surgical AVR by two senior cardiothoracic surgeons. Although the logistic EuroSCORE was 17%, the perioperative risk was deemed to be high as a chest computed tomography showed that the cardiac structures were adherent to the anterior chest wall. The novel technique of percutaneous aortic valve implantation was therefore offered as a “last resort” alternative to surgical AVR. Informed consent was obtained from the patient and family.

The procedure was performed in the cardiac catheterisation laboratory under general anaesthesia. A cannula was placed in the right radial artery for continuous blood pressure (BP) monitoring, and a Swan-Ganz catheter was placed in the right internal jugular vein for central venous pressure monitoring. Transoesophageal echocardiography (TEE) was performed to confirm aortic annulus dimension and to provide imaging during the procedure. Left groin venous and arterial accesses were obtained for the placement of a pacing wire in the right ventricular apex and a pigtail catheter in the aortic root. Surgical cut-down of the right external iliac artery was performed, and a size 22-French sheath was inserted. The valve was crossed retrograde using standard technique. A long, stiff 0.035-inch wire was placed in the left ventricular apex. Balloon valvuloplasty was successfully performed with a 20 mm × 5 cm Z-Med balloon (Numed, Ontario, Canada) under rapid ventricular pacing (Fig. 1). Systolic BP was maintained above 100 mmHg before and after rapid pacing using vasopressors as required. A 23-mm Sapien THV (Edwards Lifesciences, Irvine, CA, USA), was then manually crimped onto a 23 mm × 3 cm balloon (Fig. 2), and advanced to the aortic annulus. Optimal THV position was assessed with fluoroscopy and TEE (Fig. 3). This THV was then deployed under rapid pacing by inflating the balloon (Fig. 4).

Immediately post-deployment TEE showed a stable THV position, a mean pressure gradient of 6 mmHg and trivial paravalvular leak. Root aortogram revealed minimal aortic regurgitation and patent coronary arteries

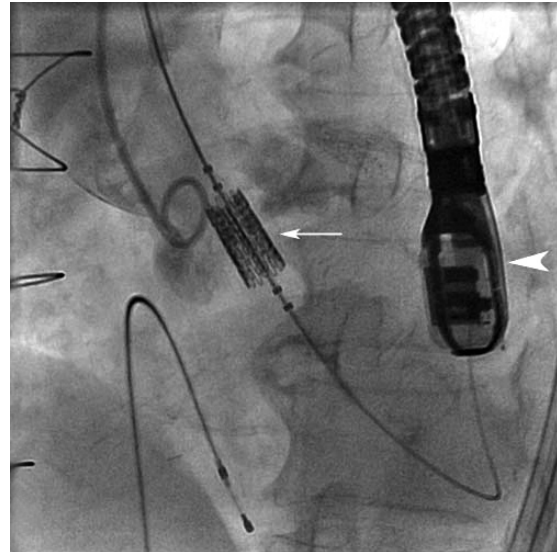


Fig. 3 Aortogram shows the Sapien THV placed in the aortic annulus (arrow). Arrowhead denotes the TEE probe.

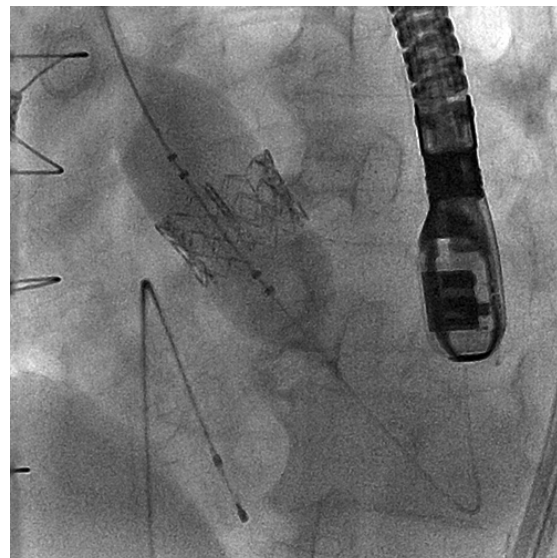


Fig. 4 Fluoroscopic image shows deployment of the Sapien THV.

(Fig. 5). Anaesthesia was reversed, and the patient was extubated on-table. Recovery was uneventful except for a moderate-sized right groin haematoma, which resolved spontaneously. The patient was well at 30-day follow-up and reported marked improvement in functional status to NYHA class I. Echocardiographical assessment showed a LVEF of 46%, a mean pressure gradient of 20 mmHg across the aortic valve, trivial aortic paravalvular leak, and mild MR.

DISCUSSION

Although surgical AVR is the gold standard therapy for patients with symptomatic severe AS, a significant proportion of patients are not offered or are denied this treatment.⁽²⁾ Balloon valvuloplasty was developed in the

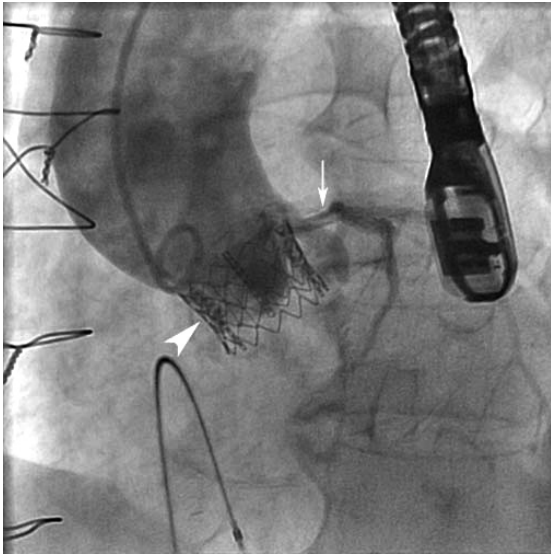


Fig. 5 Root aortogram shows a patent left coronary artery (arrow). The native right coronary artery was previously occluded. Arrowhead denotes the expanded THV.

hope of offering symptomatic relief to some of these patients, but restenosis was almost universal within 1–2 years, and it also did not change the dismal prognosis of the disease.⁽⁵⁾ Percutaneous transcatheter aortic valve implantation, therefore, emerged as an alternative to surgical AVR. There are two THVs that have obtained the European CE mark of approval – the balloon-expandable Sapien valve and the self-expandable CoreValve (CoreValve, Irvine, CA, USA, recently acquired by Medtronic Inc, Minneapolis, MN, USA). The Sapien THV consists of three bovine pericardial leaflets mounted within a stainless steel frame. These devices have been used mainly in selected centres in Europe and North America, with the Sapien valve also undergoing a FDA-sanctioned randomised trial comparing percutaneous technology vs. surgical AVR vs. medical therapy in North America (PARTNER trial). Few institutions are performing this procedure outside of Europe and North America, and this is the first implant in the Asian continent.

Currently, patients considered for this therapy are considered at high surgical risk as assessed either by the logistic EuroSCORE (> 20%) or the STS (Society of Thoracic Surgeons) score (> 10%), or are non-operable for surgical AVR (e.g. porcelain aorta, radiation chest).⁽⁶⁾ Although our patient had a logistic EuroSCORE of 17%, the surgical risk was deemed to be high due to adherent cardiac structures to the anterior chest wall from the previous CABG. Percutaneous transcatheter therapy offered this patient an alternative treatment after being declined for surgical AVR over the past six months. The patient's clinical improvement and

haemodynamic findings at 30 days are consistent with the reported literature. Despite the fact that the native leaflets are not removed, valve areas of 1.5–1.6 cm² have been consistently achieved with mean pressure gradients around the range of 10–20 mmHg.^(7,9) The trivial paravalvular leak in this patient is not expected to pose any significant problem in the future as most studies show that these leaks either disappear or remain stable, and that mild-moderate paravalvular leaks are well tolerated.⁽⁶⁾

This emerging therapy, although very promising and exciting, has several problems and potential complications. The learning curve is steep,^(8,9) and though improved from the early experience, procedural success rates are still approximately 90%–95% (Vancouver experience, Webb JG, personal communication).^(9,10) Periprocedural stroke risk is 5%–6% for the transfemoral route of THV implantation. Device embolisation into the ascending aorta or back into the left ventricle can occur particularly if there was suboptimal positioning during THV deployment. Occlusion of the coronary artery by a bulky calcified native leaflet may occur rarely. Significant heart block necessitating permanent pacemaker implantation has been documented, and serious vascular injury, including perforation leading to mortality has also been reported.^(7-9,11,12) Thus at this time, this therapy should only be considered for patients with symptomatic severe AS and at high surgical risk or are non-operable for surgical AVR.

In conclusion, percutaneous aortic valve implantation is emerging as an alternative to surgical AVR for selected patients with symptomatic severe AS, who are at high surgical risk or are non-operable. The technology has evolved very rapidly with satisfactory results, mainly in major institutions in Europe and North America. In this first-in-Asia case of percutaneous transfemoral implant of a transcatheter heart valve, a patient with symptomatic severe AS and at high surgical risk was successfully treated, with good clinical outcome and satisfactory haemodynamic results at 30-day follow-up.

ACKNOWLEDGEMENT

The authors would like to thank Dr John Webb from St. Paul's Hospital, Vancouver, British Columbia, Canada, for his technical assistance during the procedure.

REFERENCES

1. Kvidal P, Bergström R, Hörte LG, Ståhle E. Observed and relative survival after aortic valve replacement. *J Am Coll Cardiol* 2000; 35:747-56.
2. Iung B, Cachier A, Baron G, et al. Decision-making in elderly patients with severe aortic stenosis: why are so many denied surgery? *Eur Heart J* 2005; 26:2714-20.

3. Cribier A, Eltchaninoff H, Bash A, et al. Percutaneous transcatheter implantation of an aortic valve prosthesis for calcific aortic stenosis: first human case description. *Circulation* 2002; 106:3006-8.
4. Chiam PT, Ruiz CE. Percutaneous transcatheter aortic valve implantation: Evolution of the technology. *Am Heart J* 2009; 157:229-42.
5. Otto CM, Mickel MC, Kennedy JW, et al. Three-year outcome after balloon aortic valvuloplasty. Insights into prognosis of valvular aortic stenosis. *Circulation* 1994; 89:642-50.
6. Chiam PT, Ruiz CE. Percutaneous transcatheter aortic valve implantation: assessing results, judging outcomes and planning trials. The interventionalist perspective. *J Am Coll Cardiol Interv* 2008; 1:341-50.
7. Cribier A, Eltchaninoff H, Tron C, et al. Treatment of calcific aortic stenosis with the percutaneous heart valve: mid-term follow-up from the initial feasibility studies: the French experience. *J Am Coll Cardiol* 2006; 47:1214-23.
8. Webb JG, Pasupati S, Humphries K, et al. Percutaneous transarterial aortic valve replacement in selected high-risk patients with aortic stenosis. *Circulation* 2007; 116:755-63.
9. Grube E, Buellesfeld L, Mueller R, et al. Progress and current status of percutaneous aortic valve replacement: Results of three device generations of the CoreValve Revalving system. *Circ Cardiovasc Intervent* 2008; 1:167-75.
10. Eltchaninoff H, Zajarias A, Tron C, et al. Transcatheter aortic valve implantation: technical aspects, results and indications. *Arch Cardiovasc Dis* 2008; 101:126-32.
11. Sinhal A, Altwegg L, Pasupati S, et al. Atrioventricular block after transcatheter balloon expandable aortic valve implantation. *J Am Coll Cardiol Interv* 2008; 1:305-9.
12. Piazza N, Onuma Y, Jesserun E, et al. Early and persistent intraventricular conduction abnormalities and requirements for pacemaking after percutaneous replacement of the aortic valve. *J Am Coll Cardiol Interv* 2008; 1:310-6.

2009 SMJ Best Research Paper Awards

The Singapore Medical Association will be presenting awards for the Best Research Paper published in the Singapore Medical Journal (SMJ) in 2009. All original research papers that are published in the SMJ during the one year period from January 1, 2009 to December 31, 2009 will be considered for this award.

The following are the judging criteria:

- **The paper with the most potential impact on clinical practice**
- **Most rigorous study design/research methodologies**
- **Comprehensive data analysis and balanced discussion**
- **Data interpretation**

Distinguished members of the medical profession will be invited to serve on our panel of judges for selecting the winning papers.

The authors of the winning papers selected by our panel of judges will receive cash prizes for the first, second and third places. Prize winners will also receive a commemorative trophy and certificate.

We thank you for your support of the SMJ. The quality of our journal depends on the quality of your submissions.