

Tenosynovial giant cell tumour of the posterior cruciate ligament and its arthroscopic treatment

Aksoy B, Ertürer E, Toker S, Seçkin F, Şener B

ABSTRACT

Tenosynovial giant cell tumours originate from synovial tissues of the joints, tendon sheaths, mucosal bursas or fibrous tissues adjacent to tendons. Tenosynovial giant cell tumours are rarely intra-articular. We report a giant cell tumour of the tendon sheath arising from the posterior cruciate ligament diagnosed by magnetic resonance imaging and resected arthroscopically in a 54-year-old woman.

Keywords: arthroscopic resection, giant cell tumour of the tendon sheath, pigmented villonodular tenosynovitis, posterior cruciate ligament, tendon sheath lesion, tenosynovial giant cell tumour

Singapore Med J 2009;50(6):e204-e205

INTRODUCTION

Tenosynovial giant cell tumours, also known as pigmented villonodular tenosynovitis, arise from the synovial tissue of the joint, tendon sheath, mucosal bursa or fibrous tissue adjacent to the tendon.⁽¹⁾ These tumours predominantly involve the palmar side of fingers and toes, and seldom larger joints like the knees and ankles.⁽²⁾ Tenosynovial giant cell tumours of the tendon sheath are rarely intra-articular.⁽³⁾ In the literature, there has only been one reported case of tenosynovial giant cell tumour arising from the posterior cruciate ligament (PCL).⁽⁴⁾ In this report, we present a rare location of a tenosynovial giant cell tumour arising from the PCL and its treatment with arthroscopy.

CASE REPORT

A 54-year-old woman was referred to our clinic for right knee pain of two years. She did not feel any pain at rest but in walking and climbing up and down the stairs. She did not have knee trauma. She had active and full range of motion of the knee. On physical examination, there was no lateral and medial joint space tenderness. The knee was found to be stable in Lachman, anterior drawer, posterior drawer and medial-lateral stress tests.

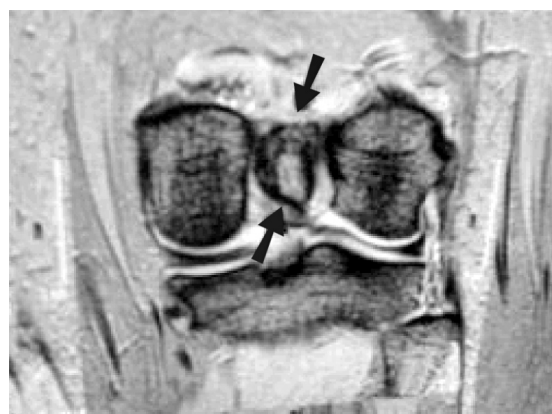


Fig. 1 Coronal T2-W MR image shows a 22 mm × 18 mm hyperintense regular contoured mass, localised in the posterior cruciate ligament (arrows).

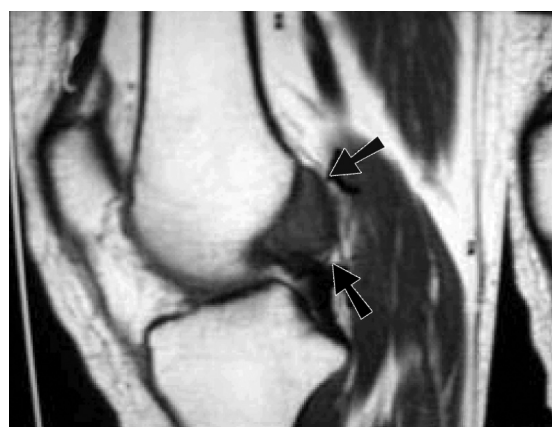


Fig. 2 Sagittal T1-W MR image shows a 22 mm × 18 mm hypointense regular contoured mass, localised in the posterior cruciate ligament (arrows).

No bone pathology was detected in anteroposterior and lateral knee radiographies. All laboratory tests were within normal ranges. On magnetic resonance (MR) imaging, a regular contoured mass localised in the PCL was detected (Figs.1 & 2).

In the light of these findings, we performed an arthroscopy from standard portals. At the arthroscopy, a soft tissue mass that was yellow, pink and partially shiny white in colour was localised in the femoral attachment of the PCL. There was no meniscal and articular cartilage lesion. The mass was totally resected with a shaver

Orthopaedics and Traumatology Clinic, Sisli Etfal Research and Training Hospital, Istanbul 34000, Turkey

Aksoy B, MD
Associate Professor

Ertürer E, MD
Orthopaedic Surgeon

Seçkin F, MD
Orthopaedic Surgeon

Şener B, MD
Orthopaedic Surgeon

Department of Orthopaedics and Traumatology, Dumlupinar University School of Medicine, Kutahya 43270, Turkey

Toker S, MD
Assistant Professor

Correspondence to:
Dr Serdar Toker
Tel: (90) 274 228 0434
Fax: (90) 274 265 2277
Email: tokerserdar@hotmail.com

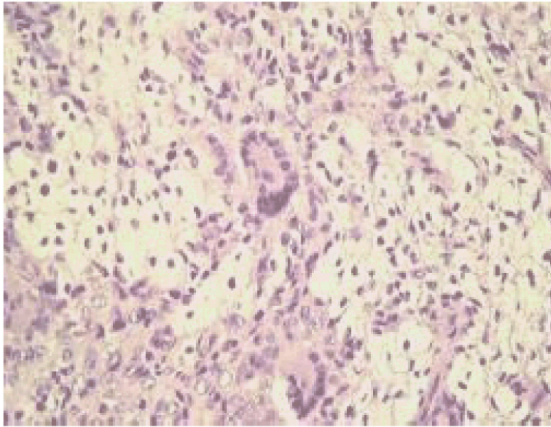


Fig. 3 Photomicrograph shows cells with normochromatic nuclei, with isositosis and isocaryosis, confirming giant cell tumour of the tendon sheath (Haematoxylin & eosin, $\times 40$).

and thermal ablation device. The histopathological examination revealed that the lesion composed of sheets of round or polygonal cells that blended with hypocellular collagenised zones. Multinucleated giant cells were scattered throughout the lesion. Xanthoma cells and haemosiderin granules were present (Fig. 3). The lesion was diagnosed as tenosynovial giant cell tumour. The patient had no more complaints after the operation, and there was no recurrence at 36 months' follow-up.

DISCUSSION

Tenosynovial giant cell tumours are generally differentiated into subgroups according to the region of occurrence and growing properties. These types have different clinical properties and biological behaviour.⁽¹⁾ Tenosynovial giant cell tumours are classified as localised and diffuse tumours.⁽⁴⁾ Localised tumours are benign soft tissue tumours that predominantly involve the palmar side of the fingers and toes. These tumours are typically painless and grow slowly. The incidence in males is two times that of females, and the mean age of patients is 30–50 years.^(1,2) These tumours typically do not involve the larger joints and are very rarely placed intra-articularly.⁽³⁾ They are generally small (< 4 cm in diameter) and well-

contoured masses, although tumours of up to 8 cm in diameter have been reported.⁽¹⁾ A 10%–20% recurrence rate has been reported after local excision.^(1,2) As giant cell tumours do not have characteristic clinical features, they are usually diagnosed by investigations based on suspicion.^(2,3) 10%–14% of patients show cortical bone erosions.⁽¹⁾

The nature of this lesion is still controversial. Jaffe et al considered it a reactive process, hence the name, nodular tenosynovitis.⁽⁵⁾ Most authors currently regard it as being neoplastic, a hypothesis supported by the presence in this lesion of clonal chromosomal aberrations.⁽⁶⁾ MR imaging has been reported to be the best diagnostic technique for this entity.⁽⁷⁾ In this case, we report a histopathologically-proven giant cell tumour of the tendon sheath arising from the PCL that was diagnosed by MR imaging and totally resected arthroscopically. This is the second case in the literature. We conclude that localised giant cell tumour of the tendon sheath can be placed as a unique lesion in the PCL, and a total arthroscopic resection is possible.

REFERENCES

1. Enzinger FM, Weiss SW. Benign tumors and tumor-like lesions of synovial tissue. In: Enzinger FM, Weiss SW, eds. *Soft Tissue Tumors*. 3rd ed. St Louis: CV Mosby, 1995: 735-55.
2. Kuhnen C, Müller KM, Rabstein S, Kasprzyński A, Herter P. [Tenosynovial giant cell tumor]. *Pathologe* 2005; 26:96-110. German.
3. Otsuka Y, Mizuta H, Nakamura E, et al. Tenosynovial giant-cell tumor arising from the anterior cruciate ligament of the knee. *Arthroscopy* 1996; 12:496-9.
4. Sheppard DG, Kim EE, Yasko AW, Ayala A. Giant-cell tumor of the tendon sheath arising from the posterior cruciate ligament of the knee: a case report and review of the literature. *Clin Imaging* 1998; 22:428-30.
5. Jaffe HL, Lichtenstein L, Sutro CJ. Pigmented villonodular synovitis, bursitis, and tenosynovitis. *Arch Pathol* 1941; 31:731-65.
6. Sciot R, Rosai J, Dal Cin P, et al. Analysis of 35 cases of localized and diffuse tenosynovial giant cell tumor: a report from the Chromosomes and Morphology (CHAMP) study group. *Mod Pathol* 1999; 12:576-9.
7. Kitagawa Y, Ito H, Amano Y, Sawaizumi T, Takeuchi T. MR imaging for preoperative diagnosis and assessment of local tumor extent on localized giant cell tumor of tendon sheath. *Skeletal Radiol* 2003; 32:633-8.