

Open simultaneous double dislocation of the metacarpophalangeal and interphalangeal joints of the thumb with ulnar collateral ligament avulsion

Singh V K, Singh P K, Kalairajah Y

ABSTRACT

Double dislocations of the thumb at the metacarpophalangeal joint (MCPJ) and interphalangeal joint (IPJ) occurring at the same time are seldom seen in medical practice. The sporadic occurrence of this interesting injury makes it difficult to formulate a clear management protocol. We report an unusual combination of injury involving a right thumb of a 60-year-old man, where the IPJ was dislocated dorsally with a volar dislocation of the MCPJ. It was an open injury with avulsion of the ulnar collateral ligament of the MCPJ. The dislocation was treated successfully by closed reduction in the casualty department, under a ring block. The ulnar collateral ligament was repaired later in the operating theatre. At six months' follow-up, the patient had a full painless range of movement in his thumb with no instability. To our knowledge, this is the first reported case of a thumb double dislocation where the injury was open at both joints. This is also the first case where a volar dislocation of the MCPJ was treated successfully by closed reduction, with an excellent functional outcome.

Keywords: double thumb dislocations, interphalangeal joint dislocation, metacarpophalangeal joint dislocation, thumb dislocations

Singapore Med J 2009;50(6):e206-e210

INTRODUCTION

Dislocation involving two adjacent joints in the same finger is a rare injury.⁽¹⁾ Open double dislocation of the thumb involving the metacarpophalangeal joint (MCPJ) and interphalangeal joint (IPJ) fortunately remains an extremely uncommon entity. Nevertheless, whenever encountered, this rare injury poses a special challenge to a hand surgeon in terms of both management as well

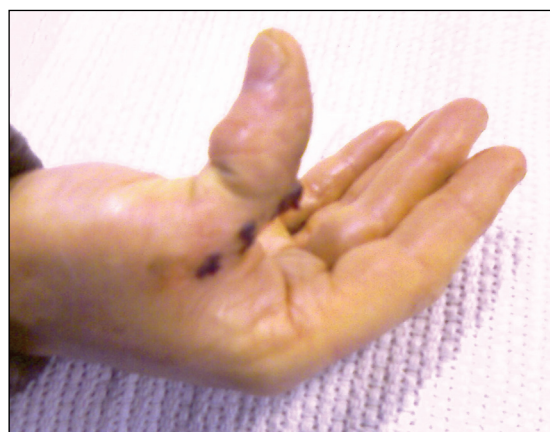

Fig. 1 Photograph shows open dislocation of the metacarpophalangeal and interphalangeal joints of the right thumb, resulting in gross deformity.

as rehabilitation. The reduction is especially difficult to achieve by closed manipulation in the presence of a volar dislocation at the MCPJ. Only five similar cases have been found in the literature; two of them had a similar injury pattern as our case, with volar dislocation of the MCPJ.⁽¹⁻⁵⁾ However, both cases required an open reduction with a suboptimal functional outcome. This case remains a singularity in terms of the unique injury pattern, as well as a successful closed reduction, resulting in an excellent functional outcome.^(4,5)

CASE REPORT

A 60-year-old retired man, on his way home after having a few drinks at a party, fell into a pothole. He landed awkwardly on his dominant right hand, hitting the ground with his thumb and twisting it violently backwards. He presented to the casualty department with a painful deformed thumb, along with an open wound (Fig. 1). After giving him adequate analgesics, a thorough examination was performed. The thumb was grossly deformed at both the MCPJ and IPJ. There was a bone-deep laceration of approximately 3.5 cm in size, extending from the MCPJ to the IPJ on the volar aspect. All active and passive movements were lost in

Department of Trauma & Orthopaedics Surgery, Luton and Dunstable Hospitals NHS Foundation Trust, Lewsey Road, Luton, LU4 0DZ, The United Kingdom

Singh VK, DOrth, MRCS, MCh Registrar

Kalairajah Y, FRCS Consultant

Department of Neurovascular Surgery, Royal Hallamshire Hospital, Sheffield, S10 2JF, The United Kingdom

Singh PK, MBBS, MS, MRCS Research Fellow

Correspondence to: Mr Vinay K Singh
Tel: (44) 79 6363 6753
Fax: (44) 15 8249 7403
Email: we.publish@googlegmail.com

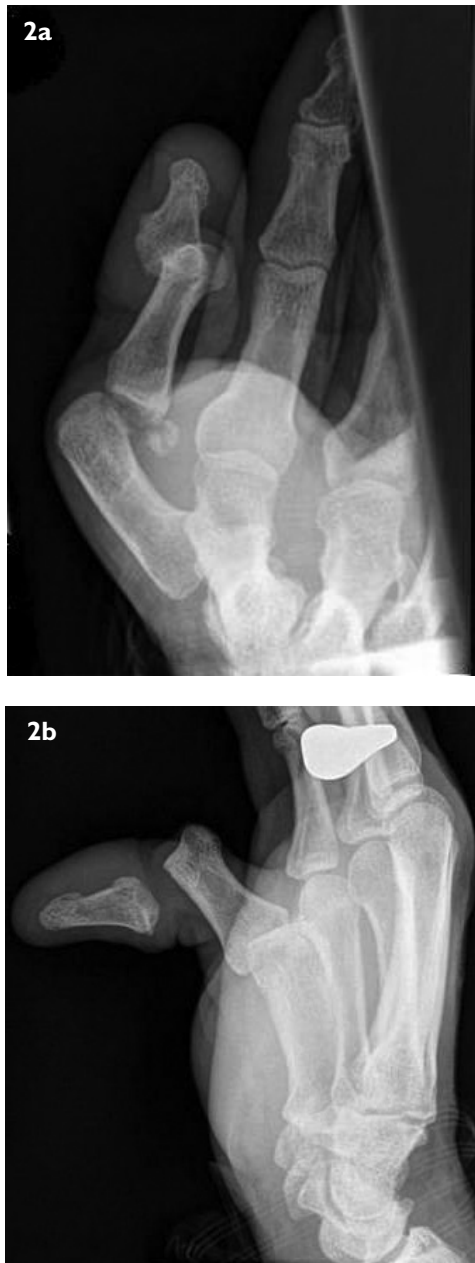

Fig. 2 Anteroposterior and lateral radiographs show the characteristic injury pattern, with volar and dorsal dislocations of the (a) metacarpophalangeal joint, and (b) interphalangeal joint.

the injured thumb. However, despite the severity of the injury, the distal neurovascular status was intact. An urgent radiograph revealed a unique pattern of injury. Both the MCPJ and IPJ were dislocated to the volar and dorsal side, respectively, along with an associated injury to the ulnar collateral ligament (Fig. 2). Due to the complexity of the injury, the case was discussed with the consultant orthopaedic surgeon on call. Owing to the non-availability of an emergency theatre and to avoid further delay, a decision was taken to attempt a close reduction in the casualty ward, with a thorough wound toilet.

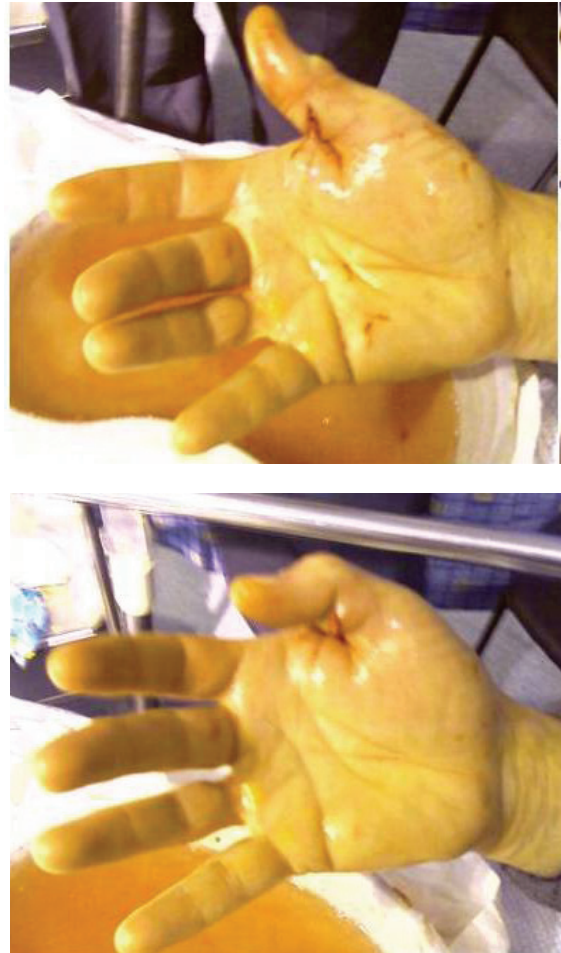


Fig. 3 Photographs show a good range of movement immediately post-reduction.

The wound was washed freely with normal saline. The patient was given a light sedation, along with a ring block under anaesthetic supervision. The MCPJ was reduced first by gently flexing and levering the proximal phalanx dorsally while stabilising the metacarpal with the other hand. Once a successful reduction was achieved at the MCPJ, reduction of the IPJ was then performed by using the conventional method, as described by McLaughlin,⁽⁶⁾ while maintaining the MCPJ in the reduced position. The patient regained a normal range of movement immediately post-reduction (Fig. 3). The satisfactory position of both joints was confirmed by a check radiograph (Fig. 4). The IPJ was stable but the MCPJ was unstable to valgus stress.

The patient was taken to the operating theatre the following morning where his wound was closed, and the ruptured volar plate and ulnar collateral ligament were repaired by a hand surgeon, using Mitek® (DePuy Mitek, Johnson & Johnson, Raynham, MA, USA) suture. The postoperative period remained uneventful, and the patient was subsequently discharged the following

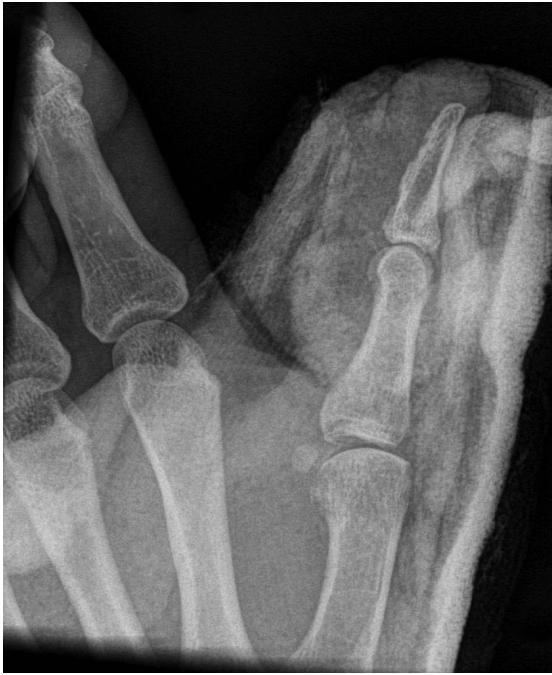

Fig. 4 Post-reduction radiograph shows the anatomical reduction of both joints.

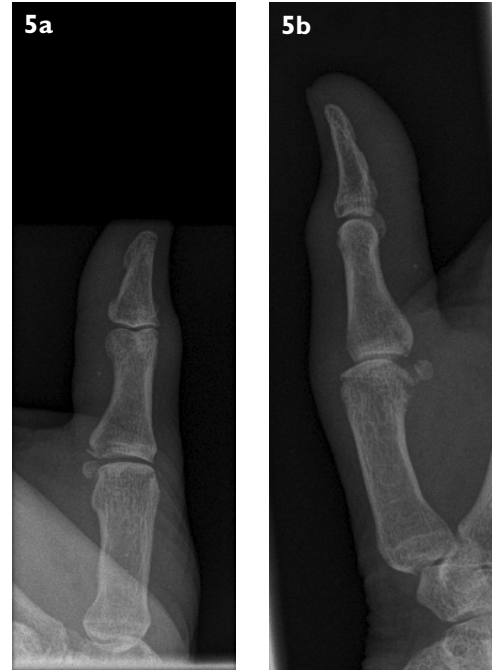

Fig. 5 (a) Anteroposterior and (b) lateral radiographs of the right thumb show well-aligned metacarpophalangeal and interphalangeal joints at six weeks' follow-up, with no associated complications.

day, with a thumb spica for three weeks. The patient was referred for hand therapy after three weeks. At six months' follow-up, he had regained a full, painless range of movement in his thumb with no signs of instability (Fig. 5).

DISCUSSION

From the functional standpoint, the hand is one of the most important organs of the body. The significance of the hand, in turn, largely depends upon the pincer action of the thumb.⁽⁶⁾ The extreme mobility of the first metacarpal bone makes the thumb functionally as important as all the remaining fingers together. Due to the high functional salience, even the slightest degree of impairment may not be acceptable.⁽⁷⁾ The double dislocation of the thumb involving the MCPJ and IPJ are providentially not common. A very scanty body of literature is available on the subject, with only five similar cases having been previously reported (Table I).⁽¹⁻⁵⁾ The first case of simultaneous double dislocation of the thumb involving the MCPJ and IPJ was reported by Levy and Liberty in 1979.⁽¹⁾ Four other cases were added by different authors over the next 30 years.⁽²⁻⁵⁾

In order to assess the outcome and to achieve an anatomical reduction, it is vital to know the joints and normal range of movement at the thumb. The MCPJ of the thumb is a capsular synovial condyloid joint formed by the head of the first metacarpal and proximal phalanx.⁽⁸⁾

It allows flexion, extension, abduction, adduction and a limited amount of rotation. The normal range of motion in the MCPJ of the thumb varies widely from 5° to 115°.⁽⁹⁾ On the other hand, the IPJ is essentially a simple hinge joint based on bicondylar anatomy. It allows some degree of hyperextension (15°) and up to 90° flexion.⁽¹⁰⁾ The IPJ is inherently more stable than the MCPJ because of its bicondylar configuration. The collateral ligaments are similar in the IPJ and MCPJ, and play an important role in providing stability to these joints.

Simultaneous double dislocation is a fascinating injury, and the nature of dislocation usually depends on the direction of the force and position of the injured finger at the time of injury. Different authors have offered a number of explanations, but the mechanism of injury described by Ikpe as well van Ransbeeck and De Smet is almost universally agreed upon.^(11,12) They attributed the injury to the hyperextension force acting on both joints, where the severity of the force tears the volar plates at both the joints, quickly dislocating the distal joint first, followed by the proximal one. The mechanism may explain the double digital dislocation with displacement of both the joints in the same direction. However, it is difficult to explain the displacement of both the joints in opposite directions based on this mechanism. In an attempt to elucidate this differential dislocation, we suggest the concept of "double-impact". At the time of the fall, the tip of the thumb struck the ground, causing

Table I. Reported cases of double dislocations involving the thumb.

Study	Age (years) / gender	Side	Mode of injury	Injury	Management	Functional outcome
Levy and Liberty ⁽¹⁾ (1979)	17 / M	Right	Football injury (thumb abducted and flexed)	MCPJ: dorsal (C); IPJ: volar (O)	CR of MCPJ; CR of IPJ	Excellent, with full range of movement.
Cleak ⁽²⁾ (1981)	67 / M	Right	Fall (extended MCPJ & IPJ and abducted CMC)	MCPJ: volar (O); IPJ: dorsal (C)	OR of MCPJ; CR of IPJ	IPJ: loss of 30° flexion; MCPJ: loss of 35° flexion.
Meriaux et al ⁽³⁾ (1983)	35 / M	Right	Road traffic collision	MCPJ: volar (C); IPJ: dorsal (O)	OR of MCPJ; CR of IPJ	Satisfactory, MCPJ: identical to opposite side; IPJ: mobility decreased very slightly, by 10°. The force of grip reduced by 20%.
Lee et al ⁽⁴⁾ (1996)	33 / M	Right	Hand caught by power drill (twisting injury)	MCPJ: dorsal (O); IPJ: dorsal (O)	OR of MCPJ; OR of IPJ	Gangrene of thumb distal to IPJ due to neurovascular injury.
Tabib and Sayegh ⁽⁵⁾ (2002)	53 / M	Right	Fall (extended MCPJ and IPJ)	MCPJ: dorsal (C); IPJ: dorsal (O)	CR of MCPJ; OR of IPJ	IPJ: loss of 20° flexion; MCPJ: loss of 15° flexion.
Singh et al (current case) (2008)	60 / M	Right	Fall (hyperextension of MCPJ & axial loading of thumb)	MCPJ: volar (O); IPJ: dorsal (O); + UCL of MCPJ	CR of MCPJ; CR of IPJ; operative repair of UCL of MCPJ	Excellent, with full range of movement.

MCPJ: metacarpophalangeal joint; IPJ: interphalangeal joint; CMC: carpometacarpal joint; UCL: ulnar collateral ligament; OR: open reduction; CR: closed reduction; (O): open injury; (C): closed injury.

the extreme hyperextension and rupture of the volar plates of both joints, as proposed earlier. The first impact thus dislocated the distal joint immediately to the dorsal side. The second impact occurred in quick succession when the distal end of the proximal phalanx struck the hard surface. The second impact pushed the distal end of proximal phalanx dorsally. Axial loading of the proximal phalanx at the time of the second impact dislocated the MCPJ to the volar side, which had already sustained a volar plate tear.

Most dislocations of the thumb at the MCPJ are dorsal, and volar dislocation is rare.^(4,5) Volar dislocations of the MCPJ are usually unstable and notoriously difficult to reduce by closed manipulation as they usually have soft tissue interposition. The fact is supported by two previous reports of double dislocation of the thumb with volar dislocation of the MCPJ. Both cases had to be reduced by open reduction.^(4,5) Interposition of the volar plate and flexor tendon can convert a simple dislocation to a complex one, requiring an open reduction.^(13,14) In our case, we had a successful closed reduction in a single attempt. It could be attributed to adequate anaesthesia, good reduction technique, or a lack of soft tissue interposition.

After the reduction of a dislocation, it is vital to check the stability of the joint in its normal anatomical

movements. In the present case, the IPJ was incredibly stable and the patient had a good range of movement immediately post-reduction. However, some instability was noted on valgus stress to the MCPJ. Therefore, the avulsed ulnar collateral ligament was fixed electively. Due to the high functional denotation, the surgeon's responsibility was to try to preserve the pincer mechanism of the thumb. Kapandji's method for clinical evaluation of the thumb can serve as a useful reference system.⁽¹⁵⁾ At six months' follow-up, our patient was able to touch the proximal crease of the little finger with the tip of the thumb, corresponding to Kapandji's stage 9.⁽¹⁵⁾

Double dislocation of the thumb with simultaneous involvement of the IPJ and MCPJ remains a rare injury. The physician should bear in mind the possibility of coexisting multiple injuries in the same digit, even after a trivial fall. It is imperative not to be distracted by the obvious dislocation of one joint, and to perform a thorough examination lest a vital injury be missed. In view of the functional significance of the thumb, an early involvement of a hand surgeon may be prudent. Volar dislocations of the MCPJ are notoriously unstable and are mostly associated with soft tissue interposition, making them resistant to closed reduction. Adequate pain relief and a meticulous technique remain the essence of

a successful closed reduction. An inappropriate reduction technique in an inexperienced hand can convert a simple dislocation into a complex one, requiring open reduction. Irrespective of the method of reduction, it is vital not to immobilise the finger for more than three weeks in order to optimise its functional outcome.

REFERENCES

1. Levy IM, Liberty S. Simultaneous dislocation of the interphalangeal and metacarpophalangeal joints of the thumb: a case report. *J Hand Surg Am* 1979; 4:489-90.
2. Cleak DK. Simultaneous dislocation of the interphalangeal and metacarpophalangeal joints in a thumb. *Hand* 1981; 13:167-8.
3. Meriaux JL, Leviet D, Djermag Y, Vilain R. [A case of simultaneous luxation of the metacarpophalangeal and interphalangeal joints of the thumb]. *Rev Chir Orthop Reparatrice Appar Mot* 1983; 69:481-2. French.
4. Lee JC, See HF, Low CO. Simultaneous open dislocations of the interphalangeal and metacarpo-phalangeal joints in a thumb—a case report. *Singapore Med J* 1996; 37:318-9.
5. Tabib W, Sayegh S. Simultaneous dislocation of the metacarpophalangeal and interphalangeal joints of the thumb. *Scand J Plast Reconstr Surg Hand Surg* 2002; 36:376-8.
6. McLaughlin HL. *Trauma*. Philadelphia: WB Saunders Co, 1959: 134.
7. Tubiana R, Thomine JM, Mackin E. *Examination of the Hand and Wrist*. 2nd ed. London: Martin Dunitz Ltd, 1998: 125-6.
8. Kahler DM, McCue FC 3rd. Metacarpophalangeal and proximal interphalangeal joint injuries of the hand, including the thumb. *Clin Sports Med* 1992; 11:57-76.
9. Palmer AK, Louis DS. Assessing ulnar instability of the metacarpophalangeal joint of the thumb. *J Hand Surg Am* 1978; 3:542-6.
10. Craig SM. Anatomy of the joints of the fingers. *Hand Clin* 1992; 8:693-700.
11. Ikpeme JO. Dislocation of both interphalangeal joints of one finger. *Injury* 1977; 9:68-70.
12. van Ransbeeck H, De Smet L. Double dislocation of both interphalangeal joints in a finger. Case report and literature review. *Acta Orthop Belg* 2004; 70:72-5.
13. Dutton RO, Meals RA. Complex dorsal dislocation of the thumb metacarpophalangeal joint. *Clin Orthop Relat Res* 1982; 164:160-4.
14. Hughes LA, Freiberg A. Irreducible MP joint dislocation due to entrapment of FPL. *J Hand Surg Br* 1993; 18:708-9.
15. Kapandji AI. Clinical evaluation of the thumb's opposition. *J Hand Ther* 1992; 5:102-6.