

# Anterior uveitis as a clinical presentation of orbital inflammatory disease in an adult

Pang C E, Teoh S C B

## ABSTRACT

We report an unusual case of orbital inflammatory disease presenting as anterior uveitis in an adult. A 35-year-old Chinese man presented with acute anterior uveitis unresponsive to topical steroids, and progressed to manifest optic disc swelling and posterior scleritis. Computed tomography showed a mass-like soft tissue swelling within the intraconal fat indenting the posterior medial aspect of the globe. The diagnosis of orbital inflammatory disease was made, and the patient was treated with systemic corticosteroids with prompt resolution of symptoms and signs. Anterior uveitis can be considered an unusual ophthalmic manifestation of orbital inflammatory disease in adults.

**Keywords:** anterior uveitis, orbital inflammatory disease, orbital pseudotumour

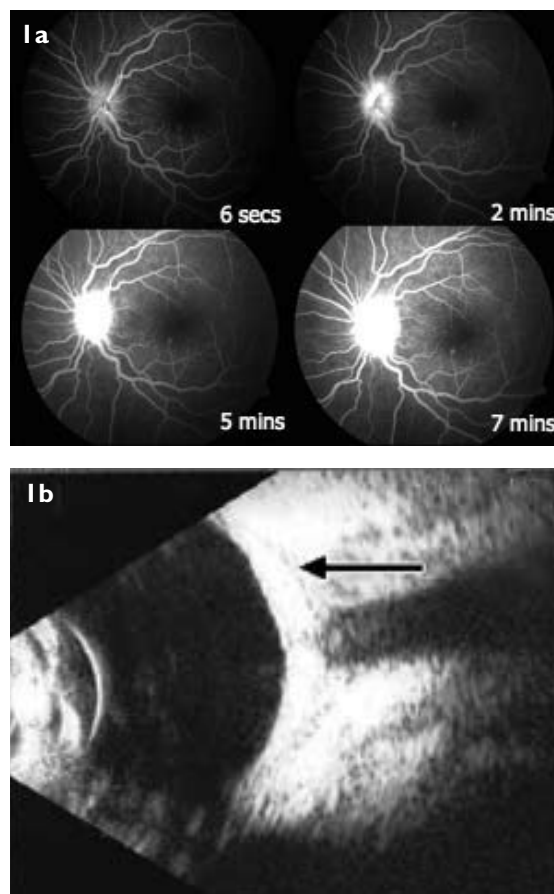
*Singapore Med J 2009;50(7):e229-e231*

## INTRODUCTION

Orbital inflammatory disease describes a broad spectrum of diseases involving inflammation and infiltration of the orbit, causing a mass effect. It has widely varying presentations, including proptosis (66%), palpable mass (65%), eyelid swelling (55%), increased orbital pressure (55%) and motility restriction (48%).<sup>(1)</sup> Anterior uveitis occurring as part of an orbital inflammatory disease has been described previously in a few case reports involving paediatric patients, but has not been reported in adults until now. Here, we describe an unusual case of orbital inflammatory disease presenting as anterior uveitis, which responded well to systemic corticosteroids.

## CASE REPORT

A 35-year-old Chinese man, with no significant medical history, presented complaining of his first episode of unilateral left eye redness and pain for six days. There was no associated blurring of vision or swelling. He had fever on the first day, which resolved spontaneously. There was no other significant systemic history. He had



**Fig. 1** (a) Fundal fluorescein angiograms of the left eye show disc hyperfluorescence at various time intervals. (b) B-scale US image of the left eye shows posterior scleral thickening and the characteristic "T" sign (arrow).

no ulcers, joint pains, rashes or cough. Visual acuity was 20/25 in the affected eye and 20/20 in the fellow eye. Slit lamp examination revealed conjunctival injection and anterior chamber activity cells grade 2+, flare grade 2+ but no hypopyon. There were fine keratic precipitates but no posterior synechiae or iris nodules. Posterior segment examination was normal at this first visit. There were no vitreous cells, no disc swelling and no macula oedema. Intraocular pressure was 21 mmHg. There was no proptosis, no tenderness to palpation and no limitation or pain with extraocular movement. The examination of the fellow eye was unremarkable.

The provisional diagnosis was acute anterior uveitis,

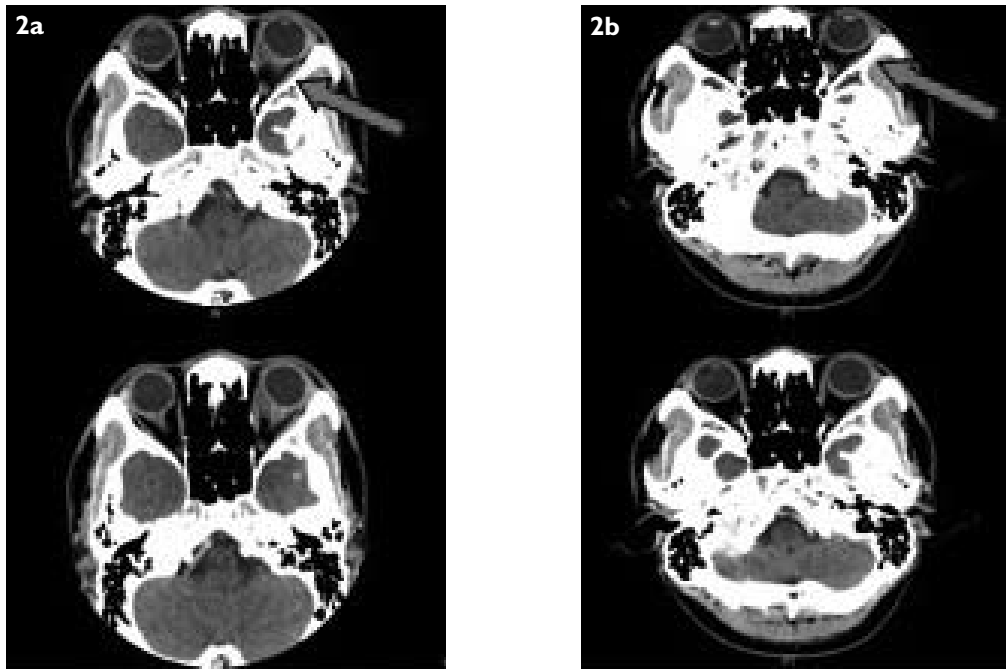
Singapore National Eye Centre,  
11 Third Hospital Avenue,  
Singapore 168751

Pang CE, MRCSE Registrar

The Eye Institute,  
Tan Tock Seng Hospital,  
11 Jalan Tan Tock Seng,  
Singapore 308433

Teoh SCB, FRCSE Associate Consultant

**Correspondence to:**  
Dr Claudine Elizabeth Pang  
Tel: (65) 9879 9757  
Fax: (65) 6383 8913  
Email: claudine28@gmail.com



**Fig. 2** (a) Axial CT images of the orbits before treatment show intraconal soft tissue swelling with indentation of the globe (arrow). (b) Axial CT images of the orbits after treatment at six months show resolution of the left orbital soft tissue mass (arrow).

and the patient was treated with topical corticosteroids and cycloplegics in the form of gutte prednisolone 1% hourly and gutte homatropine 2% twice daily. On review three days later, the patient complained of increased painless blurring of vision. Visual acuity had worsened to 20/60. The left eye was injected with increase in anterior chamber activity (cells grade 3+), vitreous flare with cells 1+ and significant optic disc swelling with adjacent retinal striae. Intraocular pressure was normal. The fellow eye remained unaffected.

Investigations done showed that inflammatory markers were markedly elevated. Erythrocyte sedimentation rate (ESR) was 214 mm/hr and C-reactive protein (CRP) was 43 mg/L. The autoimmune screen (anti-nuclear antibody, double-stranded DNA, anticardiolipin, lupus anticoagulant) and infective screen (syphilis screen, Mantoux test, chest radiography) were all normal. Fundal fluorescein angiogram (Fig. 1a) showed hyperfluorescence of the disc, consistent with the disc swelling. The retinal vessels were normal. B-scale ultrasonography (US) (Fig. 1b) showed diffuse thickening of the posterior sclera with a characteristic "T" sign, which usually signifies posterior scleritis. There were also moderate vitreous opacities in the left eye, significantly more than in the right eye. Computed tomography (CT) of the orbits (Fig. 2a) showed thickened left optic nerve with perineural enhancement and an ill-defined mass-like soft tissue swelling within the intraconal fat posterior to the left globe. Posterior scleral thickening of the left globe was also seen with

indentation of the posterior medial aspect. The conal muscles, lacrimal gland and right orbit were normal. These findings were suggestive of orbital inflammatory disease.

The patient was treated with pulsed intravenous 1 g methylprednisolone for three days, followed by oral prednisolone at 1mg/kg/day in a tapering schedule. Topical prednisolone 1% was also administered in a tailing dose. On review after completing three days of intravenous methylprednisolone, the patient was subjectively better, and the optic disc swelling was resolving. One week later, visual acuity improved to 20/20 in the affected eye with a reduction in anterior and posterior segment inflammation, and resolution of optic disc swelling. Repeat CT done six months later showed that the left orbital soft tissue mass had resolved (Fig. 2b).

## DISCUSSION

Anterior uveitis as a presentation of orbital inflammatory disease was first reported in the paediatric population in 1978.<sup>(2)</sup> Since then, other reports have followed to associate paediatric orbital pseudotumour with iritis. Bloom et al reported two cases of children with uveitis and who were ultimately diagnosed with orbital pseudotumour.<sup>(3)</sup> No proptosis was noted in either child. Mottow and Jakobiec studied 29 patients aged  $\leq 20$  years with orbital pseudotumour, and reported 35% presenting with papilloedema and iritis.<sup>(4)</sup> Notably, the case we report here presented in a similar manner.

Certain atypical features in this case were

inconsistent with the diagnosis of simple anterior uveitis. Firstly, ESR and CRP were significantly elevated, suggestive of a concomitant systemic inflammation. Secondly, clinical deterioration despite institution of intensive topical steroids was observed, and thirdly, the development of optic disc swelling and posterior scleral thickening strongly suggest the possibility of differential diagnoses, including orbital inflammatory disease, lymphoma and posterior scleritis. Posterior scleritis is classically described to present with significant ocular pain. The lack of pain in this case suggests that the posterior scleral thickening is likely due to contiguous inflammation adjacent to the inflammatory mass rather than primary posterior scleritis.

CT should be done in cases of persistent or recurrent uveitis despite a previously negative work-up.<sup>(5)</sup> CT of our patient revealed a soft tissue mass indenting the posterior globe, which is consistent with an orbital inflammatory mass, as opposed to lymphoma which characteristically

appears as a mass that moulds to the shape of the globe. In conclusion, orbital inflammatory disease in adults can present uncommonly as anterior uveitis and should be considered in unusual presentations involving the posterior segment. Management of these patients should involve both systemic and topical anti-inflammatory or immunosuppressive agents.

## REFERENCES

1. Yan J, Wu Z, Li Y. A clinical analysis of idiopathic orbital inflammatory pseudotumour. *Yan Ke Xue Bao* 2000; 16:208-13.
2. Matesanz JL, García Alonso A, Gracia Chapullé A, Llana Ruiz J. [Anterior uveitis as the form of presentation of orbital pseudotumor in a child]. *Rev Clin Esp* 1997; 197:69-70. Spanish.
3. Bloom JN, Graviss ER, Byrne BJ. Orbital pseudotumor in the differential diagnosis of pediatric uveitis. *J Pediatr Ophthalmol Strabismus* 1992; 29:59-63.
4. Mottow LS, Jakobiec FA. Idiopathic inflammatory orbital pseudotumor in childhood. I. Clinical characteristics. *Arch Ophthalmol* 1978; 96:1410-7.
5. Hertle RW, Granet DB, Goyal AK, Schaffer DB. Orbital pseudotumor in the differential diagnosis of pediatric uveitis. *J Pediatr Ophthalmol Strabismus* 1993; 30:61.