

# Down syndrome in monochorionic twins

Sin I L, Tan T Y T

## ABSTRACT

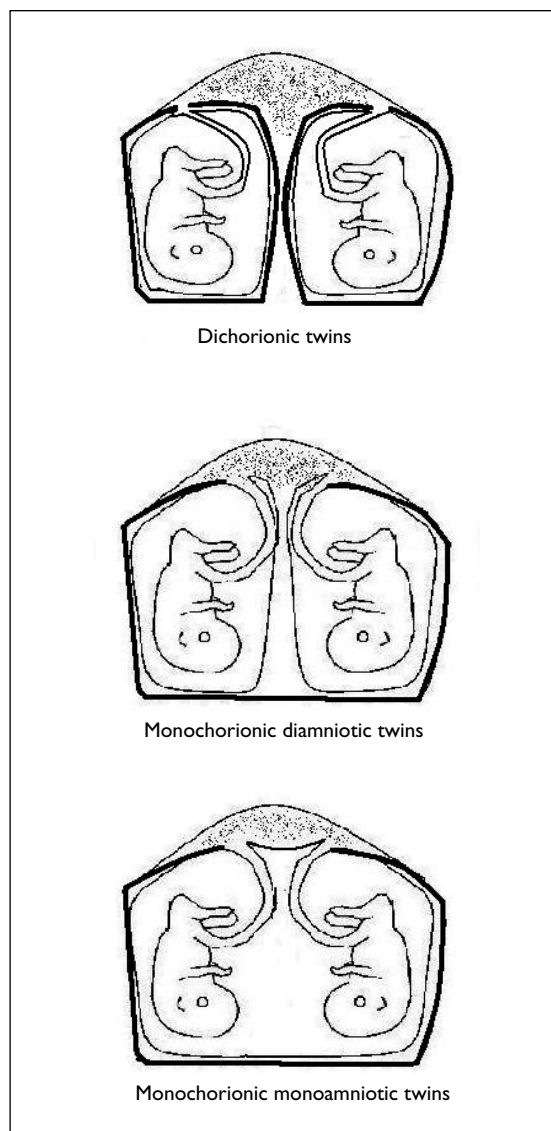
**Down syndrome in monochorionic twins has rarely been reported. We report such a case diagnosed prenatally. Maternal serum screening was performed at 15 weeks for a twin pregnancy which indicated a risk of greater than 1:50 for Down syndrome. The review of early ultrasonography confirmed monochorionic twins. Amniocentesis at 17 weeks' gestation was performed on one of the twin sacs, which confirmed Down syndrome. A screening scan at 19 weeks' gestation showed isolated absent nasal bones in both twins. Termination of pregnancy was performed subsequently.**

**Keywords:** amniocentesis, Down syndrome, nasal bone, maternal serum screening, monochorionic twins, twins

*Singapore Med J 2009;50(7):e264-e267*

## INTRODUCTION

In a twin pregnancy, it is antenatally more important to know the chorionicity (i.e. placentation) than the zygosity (i.e. whether identical as in arising from a single fertilised egg or non-identical as in arising from two separate fertilised eggs), as the chorionicity is a better predictor of an adverse pregnancy outcome.<sup>(1)</sup> Monochorionic (MC) twin pregnancies are characterised by a single placenta with vascular anastomoses between the two cord insertions of both foetuses, while dichorionic (DC) twin pregnancies are characterised by either separate placentas or a common placenta without any vascular anastomoses between the two cord insertions. MC twins have higher rates of miscarriage (6.5% vs. 1%),<sup>(1)</sup> stillbirth (3.6% vs. 1.1%),<sup>(2)</sup> perinatal mortality (2.8% vs. 1.6%)<sup>(3)</sup> and discordant growth (46% vs. 26%).<sup>(4)</sup> MC twins are also specifically associated with a 15%–20% risk of chronic twin-to-twin transfusion syndrome. If one MC twin dies, acute transfusion of blood from the surviving twin into the hypotensive dying twin via anastomoses could lead to death, cerebral ischaemia (resulting in extreme neurological disabilities with periventricular leucomalacia, porencephaly, microcephaly, cerebral palsy as well as brain death)<sup>(5)</sup> and renal ischaemia (resulting in acute tubular necrosis) in the remaining twin.<sup>(6)</sup>



**Fig. 1** Schematic diagram shows the chorionicity and amniocity of twin pregnancies.

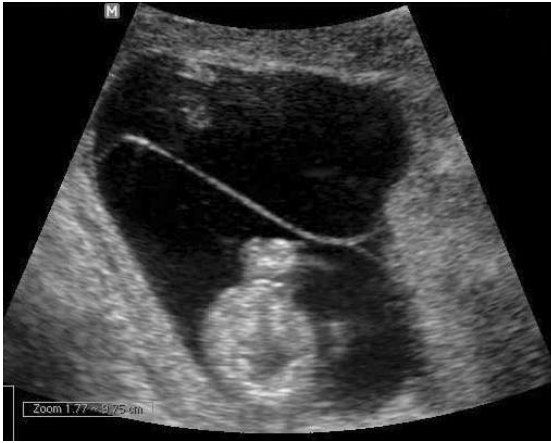MC twins occur at a constant incidence of 1–3 in 1,000 pregnancies, and account for 20% of all twin pregnancies.<sup>(3)</sup> All MC twins are monozygotic (MZ) except for a few published exceptions.<sup>(7)</sup> MZ twins arise from fertilisation of one oocyte by a single spermatozoan, which undergoes subsequent division to give rise to two foetuses. MZ twins resulting from later division at 4–12 days after fertilisation share the same placenta, and hence are MC (Fig 1). DC twins, which account for 80% of twins, have placentas without any vascular anastomoses, and the majority are dizygotic,

Raffles Women's Centre,  
Raffles Hospital,  
585 North Bridge Road,  
#12-00,  
Singapore 188770

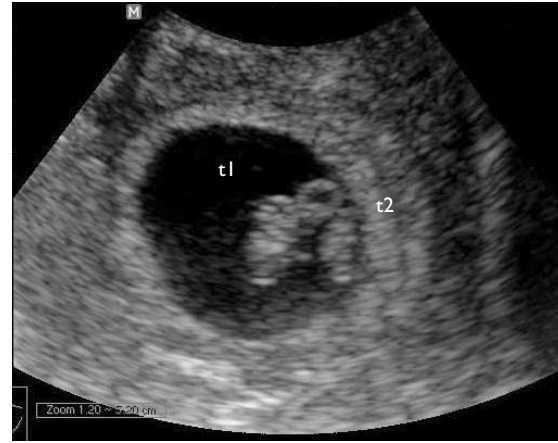
Sin IL  
Research Fellow

Tan TYT, MBBS,  
MMed, MRCOG  
Consultant and  
Maternal Foetal  
Medicine Specialist

**Correspondence to:**  
Dr Tony Tan  
Tel: (65) 6311 1230  
Fax: (65) 6311 1170  
Email: tan\_tony@  
rafflesmedical.com



**Fig. 2** US image at 12 weeks shows no apparent twin peak sign, suggesting monochorionicity.



**Fig. 3** US image at seven weeks shows both foetuses (t1 and t2) in the same picture with no thick intertwin septum between them, supporting a diagnosis of definite monochorionic twins.

though about 10% are MZ twins resulting from an earlier division at 0–4 days. Ultrasonographic diagnosis of chorionicity is extremely accurate when performed in early pregnancy up to the first trimester, and should be documented in every twin pregnancy.<sup>(7,8)</sup> This relies on the absence of a thick intertwin septum between the two twins in early pregnancy or the absence of a twin peak sign in the later part of the first trimester.

The various methods of Down syndrome (DS) screening available for singletons (i.e. maternal age, first trimester screening (FTS) with nuchal translucency [NT] and serum screening, and second trimester maternal serum screening [MSS]) can also be used in twin pregnancies, although with lower detection rates. We describe a case report of a pair of MC twins with DS that were detected by second trimester MSS with triple markers.

#### CASE REPORT

A 32-year-old woman, with a previous birth of a normal child and a current twin pregnancy diagnosed at seven weeks' gestation, was referred for counselling and amniocentesis at 17 weeks' gestation, after a second trimester MSS carried out at 15 weeks showed a high risk for DS. Multiples of medians (MoMs) for alpha-fetoprotein (AFP), human chorionic gonadotropin (hCG) and unconjugated oestriol (uE3) were determined to be 0.50, 1.48 and 0.39, respectively, corrected for maternal weight, ethnic origin and twin pregnancy. While the age-related risk was only 1:534, the calculated DS risk was greater than 1:50.

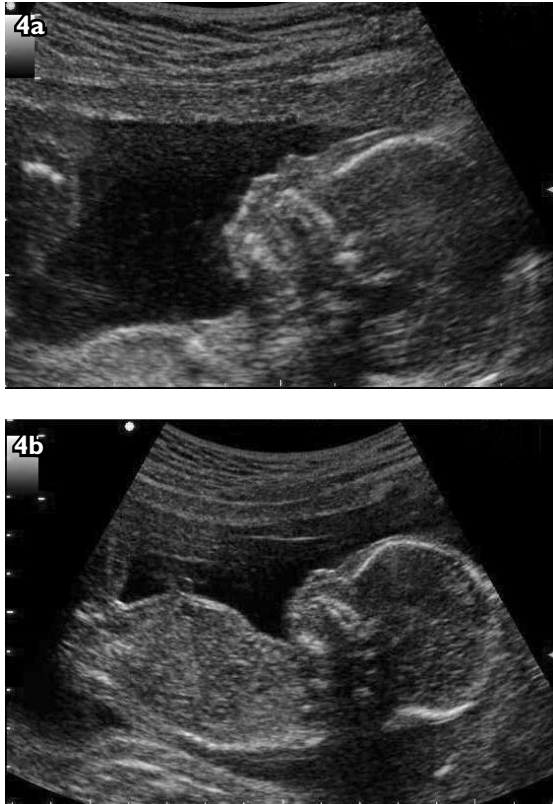We carried out ultrasonography (US) to determine the chorionicity. There was a single placenta with a thin intertwin membrane, and an absence of a twin-peak sign, and both foetuses were concordant for gender (female).

There was no obvious gross structural abnormality. The impression was a probable, but not definite, MC twin pregnancy. As diagnosis of chorionicity was critical in determining whether one or both twin amniotic sacs needed to be sampled, we requested for earlier US images to review before amniocentesis. A static image taken at 12 weeks (Fig. 2) showed no apparent twin peak sign, and an earlier US image taken at seven weeks showed two foetal poles and no thick septum between the two (Fig. 3). This was adequate for a diagnosis of a definite MC twin pregnancy.

Extensive counselling for the parents was carried out, and ultrasound-guided transamniotic amniocentesis was carried out on one amniotic sac through a single uterine puncture with a 21G needle. Meanwhile, the referring obstetrician had referred the patient to a separate US unit of another hospital at 19 weeks for a routine second trimester scan, which was reported as normal for both biometry and structural screens. Results of the chromosomal culture from amniocentesis showed an abnormal foetal karyotype of 47,XX,+21. The patient was recalled and referred to us for termination of pregnancy. We repeated the screening scan and detected absent nasal bones (NB) (a common and strong soft marker for DS) for both foetuses, further corroborating the diagnosis of DS in both twins (Figs. 4a & b). Medically-induced termination of pregnancy was subsequently carried out without complications. The placenta was examined after delivery. There were vascular anastomoses seen between the two cord insertions, confirming the diagnosis of a monochorionic twin pregnancy (Fig. 5).

#### DISCUSSION

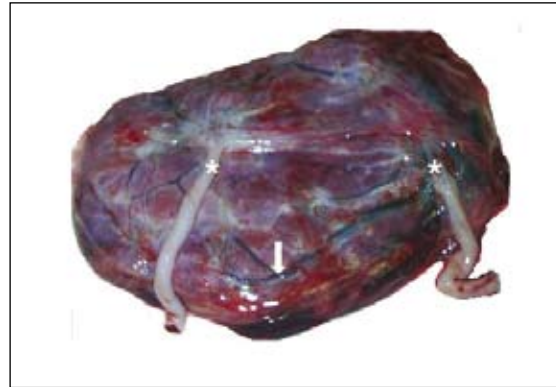Reports available on the incidence of DS in twin pregnancies are limited. The best estimated incidence



**Fig. 4** US images of (a) twin A, and (b) twin B, each with an absent nasal bone identified at 19 weeks' gestation.

of DS in twins in general comes from cohort studies carried out during routine FTS at 11–14 weeks. For example, one of the few cohort studies conducted by Vandecruys et al determined the incidence of MC twins with DS to be 0.8%.<sup>(9)</sup> Some authors feel that the DS incidence in MC twin pregnancies should be comparable to that in singleton pregnancies as MC twins similarly arise from a single fertilised egg.<sup>(7)</sup> In contrast, for DC twin pregnancies, given that each twin has the same DS risk as a singleton, the theoretical risk of at least one foetus having a chromosome defect is about twice that in singleton pregnancies. Moreover, given that both the risks of chromosomal abnormality and dizygotic twinning increase with maternal age, it is likely that the risk of chromosomal defects in DC pregnancies is more than twice that in singleton pregnancies.

In the first trimester, chorionicity can be easily and accurately determined. The presence of a twin peak sign or separate placentas accurately diagnoses DC. However, as the pregnancy progresses on to the second trimester (as in our case), separate placental masses of a DC twin pregnancy may fuse together, giving the appearance of a single placental mass. Also, the intertwin septum thins as gestational age advances, thus reducing the reliability of chorionicity determination through the determination of the septal thickness. Moreover, any absence of twin



**Fig. 5** At post-delivery examination of the placenta, photograph shows the placenta with vascular anastomoses (white arrow) between the two cord insertions (\*), confirming a monochorionic twin pregnancy.

peak sign in the second trimester is usually unreliable in chorionicity determination as it may simply disappear due to the regression of the chorion frondosum. While we determined that both foetuses in our case were concordant for gender, 45% of same-gender twins are dichorionic, and hence this finding was not useful in determining chorionicity. Furthermore, we had detected a single placenta with a thin intertwin membrane and concordant gender at an advanced gestation of 17 weeks in this case. Therefore, we could only diagnose a probable but not definite MC twin pregnancy.

Yet, such determination was important in our case as more accurate counselling prior to prenatal invasive procedure could be given. In MC twins, one can be confident that both foetuses are either normal or similarly affected. However, if the twins were DC and hence possibly discordant for karyotypes, sampling of fluid from both sacs would be needed. In the event of DS in only one twin, selective foeticide of the abnormal twin with its attendant risks may be an option. Identification of this case as a definite MC twin pregnancy allowed us to carry out a single-sac amniocentesis confidently, which may be associated with a lower risk of miscarriage than a double-sac amniocentesis. In this case, early scans were available for review, which confirmed definite monochorionicity. If determination of monochorionicity could not be definite, a double-sac amniocentesis (with either a single or double uterine puncture) would then have been performed. Hence, chorionicity should be routinely determined as early on in the pregnancy as possible to aid in any subsequent diagnostic tests and management, where knowledge of chorionicity is pertinent. It is recommended that images of both foetuses be taken in the early first trimester US (Fig. 3) as subsequent management by other specialists may require an accurate diagnosis of the chorionicity.

MSS risk in twin pregnancies is reported as a single “averaged” risk or a “pseudorisk” estimate. However, such “pseudorisk” estimates could be seen as an oversimplification of reality, for one is unable to determine how much each twin contributes to overall serum levels, especially in twins with discordant karyotypes. For example, a particular twin with DS could contribute a greater than normal amount of  $\beta$ hCG. The presence of the second twin could then mask this effect by diluting the excess values of  $\beta$ hCG arising from the first twin. Even MZ twins would not simply contribute double of what we would expect singletons to contribute.<sup>(10)</sup> Hence, with the current availability of foetal-specific NT measurement, a second trimester MSS is not the screening test of choice, especially in twin pregnancies, unless the patient presents in the second trimester after 14 weeks. Various studies conducted recently have indicated that both NT and maternal serum biochemistry can be combined to give detection rates roughly on par with those for singleton pregnancies.<sup>(11)</sup>

In multiple cohort and retrospective studies done on populations of varying sizes and risks, chorionic villus sampling (CVS) was found to be at least as safe a procedure as amniocentesis. There is no randomised controlled trial (RCT) that compares the safety of both CVS and amniocentesis. First trimester CVS allows for earlier karyotyping. In the event of an abnormality, it allows earlier decision making on termination of the pregnancy or selective foeticide, possibly reducing the psychological trauma of the parents. Selective foeticide of an abnormal twin in a multiple pregnancy is associated with decreased risks of miscarriage of about 5% vs. 15%, if performed before and after 16 weeks, respectively.<sup>(12)</sup> The major disadvantage of CVS in twin pregnancy is a possibility of sampling placental tissue of the same twin twice. Hence, it should only be performed by highly experienced practitioners.

It is recommended that FTS be offered to all twin pregnancies as it allows a proper diagnosis of the chorionicity, a better detection rate of DS than the second trimester MSS with triple markers, earlier performance of invasive diagnostic procedures like CVS or amniocentesis, and hence the possible option of subsequent selective foeticide of one abnormal twin to be performed as early as possible to reduce the risk of miscarriage to the other twin. An absent/severely hypoplastic NB has recently been found to be the strongest of all current soft markers of DS used in the second trimester US. An absent/severely hypoplastic

NB in the second trimester increases the risk of DS by a likelihood ratio of 51 times, far exceeding the likelihood ratios of the other soft markers.<sup>(13,14)</sup>

In conclusion, if the second trimester MSS had not been done in this case, the largely “normal” 20-week routine screening US performed by a level 2 US unit would not have allowed the detection of DS in this pair of twins. Current national guidelines in the USA, UK and Singapore do not recommend using the 20-week US to screen for DS. Instead, a first trimester combined test should be offered to all mothers, regardless of age, at between 11 and 13 weeks of gestation, for DS screening. Mothers who miss this testing should be offered second trimester MSS.

## REFERENCES

- Acosta-Rojas R, Becker J, Munoz-Abellana B, et al. Twin chorionicity and the risk of adverse perinatal outcome. *Int J Gynaecol Obstet* 2007; 96:98-102.
- Lee YM, Wylie BJ, Simpson LL, et al. Twin chorionicity and the risk of stillbirth. *Obstet Gynecol* 2008; 111:301-8.
- Sebire NJ, Snijders RJ, Hughes K, Sepulveda W, Nicolaides KH. The hidden mortality of monochorionic twin pregnancies. *Br J Obstet Gynaecol* 1997; 104:1203-7.
- Chauhan SP, Shields D, Parker D, et al. Detecting fetal growth restriction or discordant growth in twin gestations stratified by placental chorionicity. *J Reprod Med* 2004; 49:279-84.
- Malone FD, D'Alton ME. Management of multiple gestations complicated by a single anomalous fetus. *Curr Opin Obstet Gynecol* 1997; 9:213-6.
- Pharoah PO. Twins and cerebral palsy. *Acta Paediatr Suppl* 2001; 90:6-10.
- Bajoria R, Kingdom J. The case for routine determination of chorionicity and zygosity in multiple pregnancy. *Prenat Diagn* 1997; 17:1207-25.
- Dommergues M. Prenatal diagnosis for multiple pregnancies. *Curr Opin Obstet Gynecol* 2002; 14:169-75.
- Vandercruys H, Faiola S, Auer M, Sebire N, Nicolaides KH. Screening for trisomy 21 in monochorionic twins by measurement of fetal nuchal translucency thickness. *Ultrasound Obstet Gynecol* 2005; 25:551-3.
- O'Brien JE, Dvorin E, Yaron Y, et al. Differential increases in AFP, hCG, and uE3 in twin pregnancies: impact on attempts to quantify Down syndrome screening calculations. *Am J Med Genet* 1997; 73:109-12.
- Spencer K. Screening for trisomy 21 in twin pregnancies in the first trimester using free beta-hCG and PAPP-A, combined with fetal nuchal translucency thickness. *Prenat Diagn* 2000; 20:91-5.
- Evans MI, Goldberg JD, Dommergues M, et al. Efficacy of second-trimester selective termination for fetal abnormalities: international collaborative experience among the world's largest centers. *Am J Obstet Gynecol* 1994; 171:90-4.
- Cicero S, Rembouskos G, Vandercruys H, Hogg M, Nicolaides KH. Likelihood ratio for trisomy 21 in fetuses with absent nasal bone at the 11-14-week scan. *Ultrasound Obstet Gynecol* 2004; 23:218-23.
- Cicero S, Sonek JD, McKenna DS, et al. Nasal bone hypoplasia in trisomy 21 at 15-22 weeks' gestation. *Ultrasound Obstet Gynecol* 2003; 21:15-8.