

# IgA nephropathy associated with pleuropulmonary tuberculosis

Singh P, Khaira A, Sharma A, Dinda A K, Tiwari S C

## ABSTRACT

A 34-year-old man presented with polymerase chain reaction-positive pleuropulmonary tuberculosis with asymptomatic subnephrotic proteinuria and microscopic haematuria. He was diagnosed to have IgA nephropathy on renal biopsy. The patient was started on a four-drug anti-tuberculous therapy. Healing of the pleuropulmonary lesions along with disappearance of proteinuria and haematuria were seen both at one month and six months post-treatment, with no relapse of renal symptoms at one-year follow-up.

**Keywords:** anti-tuberculous treatment, IgA nephropathy, kidney disease, *Mycobacterium tuberculosis*, pleuropulmonary tuberculosis, primary glomerulopathies, tuberculosis

*Singapore Med J 2009;50(7):e268-e269*

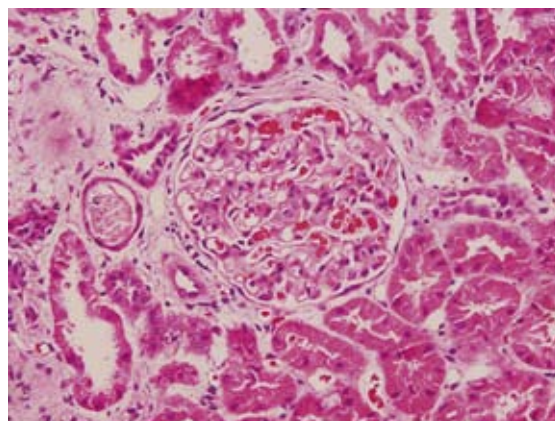
## INTRODUCTION

First described by Berger,<sup>(1)</sup> IgA nephropathy (IgAN) is one of the commonest primary glomerulopathies worldwide. It is characterised by painless episodic haematuria and proteinuria, with minimal renal impairment. While the cause of the disease still remains uncertain, it has been associated with numerous systemic diseases.<sup>(2)</sup> We present a case of IgAN associated with pleuropulmonary tuberculosis, which showed a dramatic response to anti-tuberculous treatment (ATT).

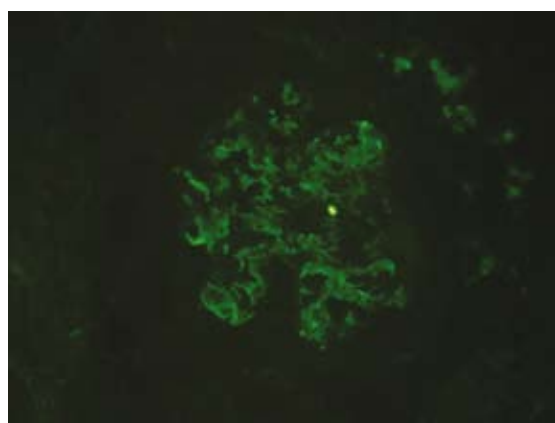
## CASE REPORT

A 34-year-old male was admitted with complaints of intermittent fever along with significant weight loss in the past four months. There were no complaints of haemoptysis, haematuria, oliguria or dependent oedema. There was no past history of tuberculosis. On examination, the patient had normal vitals. He had pallor without any clubbing, oedema or palpable lymphadenopathy. Respiratory examination revealed a stony dull note, decreased breath sounds and crepitations over the right infrascapular region. The remaining systemic examination was normal.

Chest radiograph confirmed a right-sided pleural



**Fig. 1** Photomicrograph of the renal biopsy shows a glomerulus with mesangial proliferation (Hematoxylin & eosin,  $\times 200$ ).



**Fig. 2** Direct immunofluorescence image shows predominantly mesangial deposition of immunoglobulin A (IgA).

effusion with right middle zone consolidation. Mantoux test was strongly positive with  $> 15$  mm transverse width of induration, measured after 48 hours. Induced sputum did not reveal any acid-fast bacilli on Ziehl-Neelsen staining. Cultures of induced sputum and pleural fluid were sterile. The pleural fluid was exudative with lymphocytic predominance. Polymerase chain reaction (PCR) of the pleural fluid was positive for *Mycobacterium tuberculosis*. Laboratory investigations showed a haemoglobin level of 10 gm/dL, total leucocytic count of 6,000/dL, with a normal differential count and a raised erythrocyte sedimentation rate of 36 mm/first hour. His blood urea nitrogen and serum creatinine were normal. Serum levels of calcium and phosphate were also normal.

Department of Nephrology, All India Institute of Medical Sciences, New Delhi 110029, India

Singh P, MBBS  
Junior Resident

Khaira A, MBBS, MD  
Specialist Registrar

Tiwari SC, MBBS,  
MD, DM  
Professor and Head

Department of Pathology

Sharma A, MBBS, MD  
Senior Research Associate

Dinda AK, MBBS,  
MD, PhD  
Additional Professor

**Correspondence to:**  
Dr Ambar Khaira,  
Tel: (91) 98 6815 1465  
Fax: (91) 11 2659 4799  
Email: ambarkhaira@gmail.com

He had a low serum albumin level of 3 g/dL, with normal liver function tests. Dipstick urine examination showed 2+ proteinuria. On urine microscopy, 20–25 red blood cells per high-power field were seen. 24-hour urine examination revealed subnephrotic proteinuria at 2.04 mg/dL. Early morning urine examinations, done on three occasions, were negative for acid-fast bacilli and PCR for tubercle bacilli. Kidneys and bladder were normal on ultrasonography. Serological tests were negative for hepatitis B and C virus, and human immunodeficiency virus. The patient tested negative for anti-nuclear antibody, anti-double stranded DNA antibody, anti-neutrophil cytoplasmic antibody and latex agglutination for rheumatoid factor. Immunoglobulins (Ig) G and A were raised (3,250 and 1,600 mg/dL, respectively) and IgM was normal by serum immunoelectrophoresis and quantitative immunodiffusion. Serum-C3 and C4 were within the normal range.

A percutaneous kidney biopsy was done with Bart's 16-gauge biopsy gun under ultrasonography guidance. Light microscopy showed eight glomeruli with mild mesangial cell proliferation (Fig. 1). Immunofluorescence showed mesangial deposits of IgA (+++), IgM (+), and was negative for IgG, suggesting a diagnosis of IgAN (Fig. 2). The patient received a four-drug ATT comprising isoniazid, rifampicin, pyrazinamide and ethambutol for two months, and isoniazid and rifampicin for another four months. After one month of treatment, the pulmonary consolidation and pleural effusion had disappeared. There was no detectable proteinuria or haematuria at one-month, six-month and one-year follow-up. He continues to have normal renal functions to date.

## DISCUSSION

We report a case of IgAN associated with pleuropulmonary tuberculosis, which presented as subnephrotic proteinuria and haematuria. Literature review revealed that such an association is rarely reported.<sup>(3-7)</sup> Tuberculosis as a cause of IgAN may present as a nephrotic syndrome,<sup>(4,7)</sup> microscopic haematuria,<sup>(6)</sup> or both.<sup>(5)</sup> Our case presented with microscopic haematuria and subnephrotic proteinuria. Previously-reported cases had responded to anti-tuberculous treatment with disappearance of the nephrotic syndrome<sup>(4,7)</sup> and

microscopic haematuria,<sup>(6)</sup> without the use of steroids. De Siati et al did not report any renal symptom even two years after ATT cessation.<sup>(6)</sup> In our case, we followed up the patient for one year, and his renal function tests and urine examinations have remained normal. This suggests that an aetiological relationship of IgAN with tuberculosis exists.

While the immune response to mycobacterial infection is primarily cell mediated, recent data suggests the existence of a humoral limb.<sup>(6,8)</sup> IgA antibodies, specifically against A-60 mycobacterial antigen, have been demonstrated in the sera of patients with active tuberculosis, as have immune complexes of IgA antibodies and mycobacterial antigens.<sup>(8)</sup> This provides a setting for the pathogenesis of IgAN. It has been hypothesised that the deposition of these immune complexes in the kidney, activation of the alternative complement<sup>(9)</sup> and the lectin pathway<sup>(10)</sup> with a resultant local injury lead to IgAN. We conclude that tuberculosis is a rare cause of IgAN, and that haematuria and proteinuria in the setting of tuberculosis need to be investigated for the possibility of IgAN. The institution of ATT leads to complete resolution of the renal lesion in these cases.

## REFERENCES

- Berger J. IgA glomerular deposits in renal disease. *Transplant Proc* 1969; 1:939-44.
- Galla JH. IgA nephropathy. *Kidney Int* 1995; 47:377-87.
- Mercadal L, Hulot JS, Isnard-Bagnis C, et al. Favorable outcome of IgA nephropathy on antituberculous treatment. *Minerva Urol Nefrol* 2006; 58:355-7.
- Keven K, Ulger FA, Oztas E, et al. A case of pulmonary tuberculosis associated with IgA nephropathy. *Int J Tuberc Lung Dis* 2004; 8:1274-5.
- Cohen AJ, Rosenstein ED. IgA nephropathy associated with disseminated tuberculosis. *Arch Intern Med* 1985; 145:554-6.
- De Siati L, Paroli M, Ferri C, et al. Immunoglobulin A nephropathy complicating pulmonary tuberculosis. *Ann Diagn Pathol* 1999; 3:300-3.
- Matsuzawa N, Nakabayashi K, Nagasawa T, Nakamoto Y. Nephrotic IgA nephropathy associated with disseminated tuberculosis. *Clin Nephrol* 2002; 57:63-8.
- Alifano M, Sofia M, Mormile M, et al. IgA immune response against the mycobacterial antigen A60 in patients with active pulmonary tuberculosis. *Respiration* 1996; 63:292-7.
- Floege J, Feehally J. IgA nephropathy: recent developments. *J Am Soc Nephrol* 2000; 11: 2395-403.
- Roos A, Rastaldi MP, Calvaresi N, et al. Glomerular activation of the lectin pathway of complement in IgA nephropathy is associated with more severe renal disease. *J Am Soc Nephrol* 2006; 17:1724-34.