

# Malignant perivascular epithelioid cell tumour of the round ligament mimics leiomyoma on computed tomography

Pattamapasong N, Khunamornpong S, Phongnarisorn C, Pojchamarnwiputh S

## ABSTRACT

We report a case of a 45-year-old woman who had a palpable mass in the left lower quadrant of the abdomen. Computed tomography (CT) showed a circumscribed mass in the left round ligament of the uterus. The mass had heterogeneous density and enhancement accompanied by mottled calcification, which was initially identified as a leiomyoma. A histopathological examination revealed a malignant perivascular epithelioid cell tumour (PEComa), which is a rare soft tissue tumour. This case demonstrates that the appearance of malignant PEComa on the CT can mimic leiomyoma, which is the most common tumour of the round ligament. To the best of our knowledge, this is the first report of a CT appearance of this round ligament tumour. The radiological features and differential diagnosis are discussed.

**Keywords:** leiomyoma, PEComa, perivascular epithelioid cell neoplasms, round ligament tumour, uterus lesion

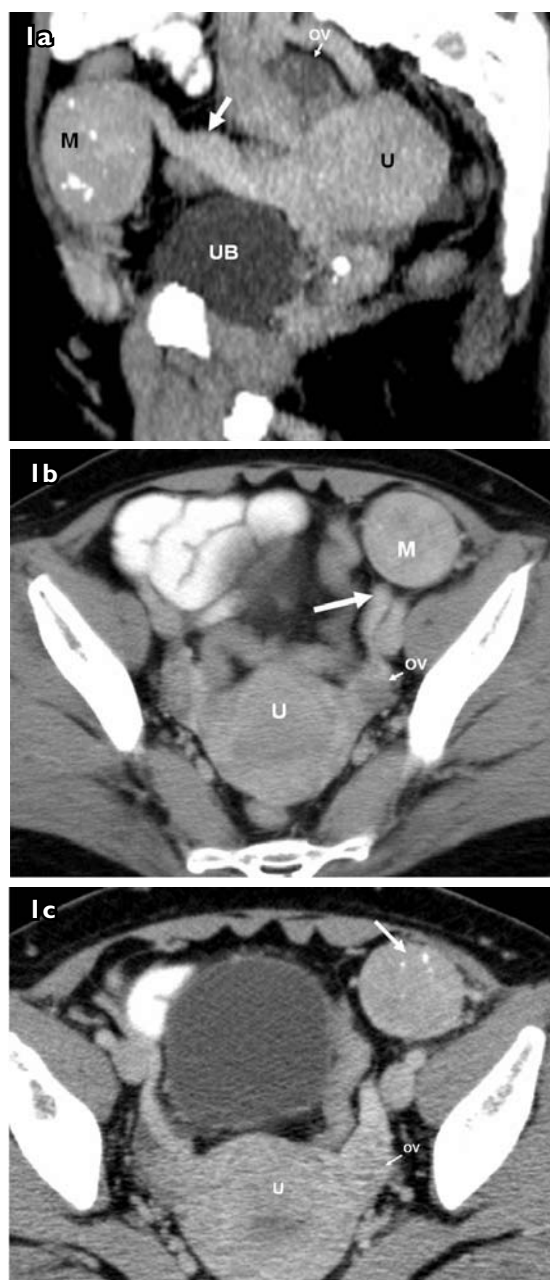
*Singapore Med J 2009;50(7):e239-e242*

## INTRODUCTION

Perivascular epithelioid cell tumour (PEComa) is a rare soft tissue tumour that has been reported in the soft tissue of the abdomen and pelvis. The appearance of this tumour on computed tomography (CT) images and operative findings can mimic leiomyoma, which is the most common tumour of the round ligament.<sup>(1)</sup> Unlike leiomyoma, PEComa has a malignant histological subgroup which may influence the surgical technique and long-term patient care. In this article, a case of malignant PEComa in the round ligament is reported. We describe the clinical presentation as well as the CT, operative and surgical findings of this rare tumour. To the best of our knowledge, this is the first report of a CT appearance of PEComa of the round ligament.

## CASE REPORT

A 45-year-old woman presented with a painless mass in



**Fig. 1** (a) Sagittal oblique reconstructed CT image shows the mass (M) attached to the round ligament (arrow). Axial CT images of the pelvis show (b) the mass (M) attached to the left round ligament (arrow), and (c) the foci of mottled calcification within the mass (open arrow).

U: uterus; UB: urinary bladder; OV: ovary

Department of  
Radiology,  
Faculty of Medicine,  
Chiang Mai University  
Hospital,  
Chiang Mai 50200,  
Thailand

Pattamapasong N,  
MD  
Instructor

Pojchamarnwiputh S,  
MD  
Assistant Professor

Department of  
Pathology

Khunamornpong S,  
MD  
Associate Professor

Department of  
Obstetrics and  
Gynaecology

Phongnarisorn C,  
MD  
Assistant Professor

**Correspondence to:**  
Dr Nuttaya  
Pattamapasong  
Tel: (66) 53 945 450  
Fax (66) 53 946 136  
Email: nuttaya@gmail.com

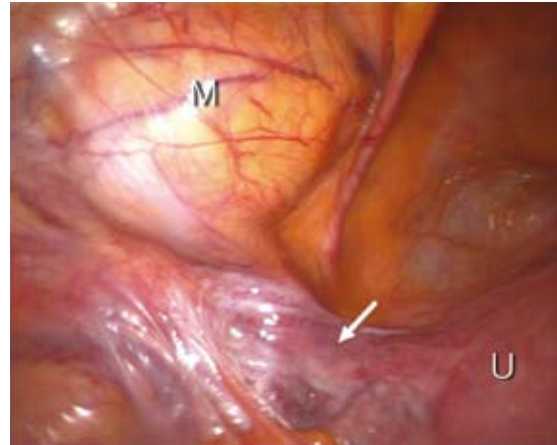
the left lower quadrant of the abdomen. She had noticed a slow-growing mass for the last five years. She had a

normal menstrual cycle. On pelvic examination, the mass was found to be located superior to the left adnexa. The initial diagnosis was a tumour originating from the small bowel or colon; therefore, the patient was evaluated by CT. The CT images showed a circumscribed mass in the left round ligament of the uterus, accompanied by a thickening of the entire ligament (Figs. 1a & b). Multiple foci of mottled calcification were seen within the mass (Fig. 1c). The density of the mass was heterogeneous, but no fat density was detected. The other organs in the abdomen were normal. Her laboratory results, including complete blood count, liver function test, serum urea, serum creatinine and urine analysis, were normal. The chest radiograph was also normal. She underwent laparoscopic resection of the mass due to the initial diagnosis of leiomyoma. Intraoperatively, there was an 8 cm × 7 cm × 8 cm extraperitoneal mass attached to the intrapelvic portion of the left round ligament (Fig. 2). The tumour was cut into fragments and excised from the attached round ligament towards the left internal inguinal ring.

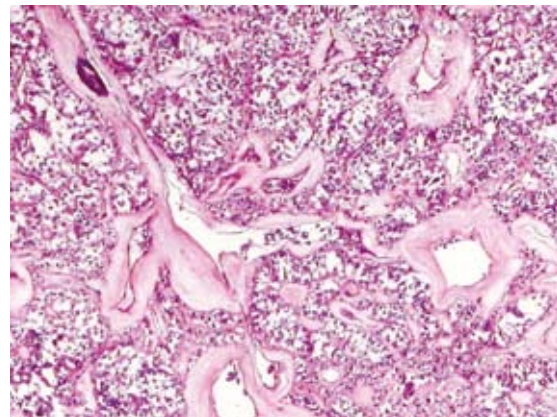
Histologically, the specimen was composed of polygonal cells containing clear or eosinophilic cytoplasm. The neoplastic cells were arranged in small nests, trabeculae or sheet-like patterns with numerous intervening vascular spaces (Fig. 3). The foci of calcification in the hyalinised blood vessel walls were present in some portions of the tumour. The nuclear size was variable, with markedly enlarged nuclei being seen in several areas (Fig. 4). Mitotic figures were rare, and no necrotic region was observed. The tumour border was infiltrative, and a few intralymphatic tumour cells were seen. Immunohistochemical staining was positive for human melanoma black-45 (HMB-45) but negative for cytokeratin, epithelial membrane antigen, smooth muscle actin, desmin, S-100 protein and CD117. The histological diagnosis was a malignant PEComa, based on the recently-published criteria by Folpe et al.<sup>(2)</sup> Because the tumour was malignant and the surgical margin obtained from the first resection could not be reliably evaluated due to the fact that the tumour was removed in fragments, a second laparoscopic operation was performed to excise the residual left round ligament and the surrounding soft tissue. No neoplastic cells were obtained in the tissue of the second resection. After 20 months of follow-up, the patient was healthy and without any symptoms of recurrent tumour.

## DISCUSSION

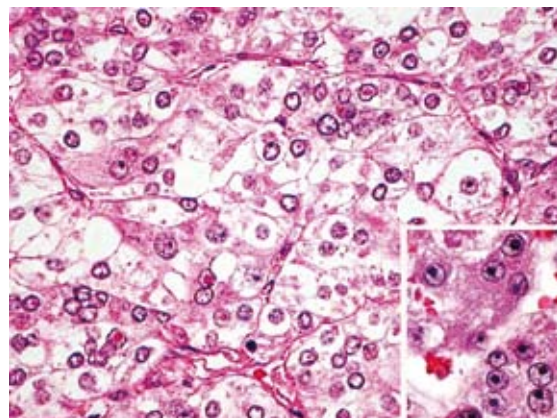
The round ligament is the gubernaculum during foetal life. The structure is responsible for the descent of the



**Fig. 2** Laparoscopic photograph shows the circumscribed mass (M) attached to the round ligament (arrow). U: uterus



**Fig. 3** Photomicrograph shows the clear cell tumour with prominent vasculature. Many vessels with thick and hyalinised walls are observed. Focal calcification is occasionally seen in the vessel wall (top left) (Haematoxylin & eosin, × 40).



**Fig. 4** Photomicrograph shows nests of polygonal clear or eosinophilic cells with intervening delicate capillaries. Inset: Marked nuclear atypia is observed (Haematoxylin & eosin, × 400).

ovary from the posterior abdominal wall to the pelvis. The ligament attaches to the uterus, near the attachment of the uterine tube and passes through the inguinal

canal to insert at the labia majora.<sup>(3)</sup> Primary tumours of the round ligament are relatively rare. The common tumours are leiomyoma, endometriosis and mesothelial cyst.<sup>(1)</sup> Other rare tumours such as myolipoma, lipoma, dermoid cyst, haemangioma and nodular fasciitis have been reported.<sup>(1,4)</sup> The presenting symptoms related to round ligament lesions depend on which part of the ligament is involved. The lesions in the abdominopelvic portion seldom cause symptoms other than palpable masses. Meanwhile, the disease in the extra-abdominal portion may cause a palpable groin lump or tenderness mimicking the clinical presentation of inguinal hernia or lymphadenopathy.<sup>(5,6)</sup> The round ligament expresses oestrogen and progesterone receptors; therefore, the growth of several round ligament tumours is related to the hormonal status;<sup>(7)</sup> for instance, leiomyoma, which mostly occurs in premenopausal women, has been reported in postmenopausal women who have received hormonal replacement therapy.<sup>(8)</sup>

PEComas, which is the tumour in this case, are defined by the World Health Organization as “mesenchymal tumours composed of histologically and immunohistochemically distinctive perivascular epithelioid cells”.<sup>(9)</sup> Common tumours of the PEComa family are angiomyolipoma (AML), clear cell sugar tumour of the lung (CCST) and lymphangioliomyomatosis (LAM). Other rare miscellaneous clear cell tumours in this family have been described under many names such as “clear cell myomelanocytic tumour”, “abdominopelvic sarcoma” and “primary extrapulmonary sugar tumour”.<sup>(2)</sup> This miscellaneous type of PEComa has been reported in abdominal and pelvic soft tissue including the mesentery, perirenal soft tissue, and the broad ligament; pelvic organs such as the vagina, cervix and uterus; and soft tissue of the scalp, thigh, forearm, neck and shoulder.<sup>(2,9,10)</sup> Most patients are middle-aged. The female-to-male ratio is almost 7:1. The criteria to diagnose the malignant subtype of PEComa are unclear due to the rarity of this tumour. Based on the recently proposed criteria,<sup>(2)</sup> infiltrative growth, lymphatic invasion and high grade nuclear atypia were the features that favoured a malignant diagnosis in our patient. To the best of our knowledge, the staging system of this tumour has not yet been established. The metastasis sites including the liver, lung and bone have been reported.<sup>(2)</sup>

A limited number of articles in the English literature have reported imaging features of the round ligament tumours. Among these, leiomyoma is the most common tumour presenting as a circumscribed heterogeneous

density mass on CT images.<sup>(11,12)</sup> Leiomyoma may contain calcification which presents in several patterns, including mottled, whorled, streaked and curvilinear.<sup>(11)</sup> Multiple and bilateral tumours can occur.<sup>(1)</sup> Another mass which is common in the round ligament is endometrioma. However, because of its cystic nature and repetitive bleeding, CT images of endometrioma present high density debris in the dependent part of the cystic mass and can be clearly distinguished from other masses. Because round ligament tumours are uncommon, radiologists may misinterpret these tumours as pedunculated uterine leiomyomas or ovarian tumours. The cord-like structure running from the uterus to the labia majora is the hallmark of the round ligament.

The CT finding of the tumour in this patient was a well-defined heterogeneous mass containing calcification which is indistinguishable from leiomyoma. Although calcification is believed to be the most specific sign for leiomyoma when it occurs in uterine masses,<sup>(11)</sup> as in this case, calcification does not indicate leiomyoma or benign tumours. The pattern of calcification in leiomyoma varies and cannot be used to distinguish leiomyoma from other tumours. Another finding in our case was the thickening of the round ligament, which histologically showed normal fibroconnective tissue. The reason for the thickening of the uninvolved part cannot be clearly explained; however, we believe that the compression of the ligament for several years may cause obstruction of the lymphatic system, resulting in the thickened ligament. The thickening of the round ligament may indicate that the tumour is a round ligament mass, not a pedunculated uterine mass. In conclusion, when a mass is in the round ligament, the well-defined circumscribed appearance accompanied by calcification does not always imply a benign tumour. As in this case, PEComa, which has malignant potential, should be a differential diagnosis.

## REFERENCES

1. Breen JL, Neubecker RD. Tumors of the round ligament. A review of the literature and a report of 25 cases. *Obstet Gynecol* 1962; 19:771-80.
2. Folpe AL, Mentzel T, Lehr HA, et al. Perivascular epithelioid cell neoplasms of soft tissue and gynecologic origin: a clinicopathologic study of 26 cases and review of the literature. *Am J Surg Pathol* 2005; 29:1558-75.
3. Moore KL, Persaud TVN. The urogenital system. In: Moore KL, Persaud TVN, eds. *The Developing Human: Clinically Oriented Embryology*. 7th ed. Philadelphia: WB Saunders, 2003: 228-328.
4. Breen JL, Lukeman JM, Neubecker RD. Nodular fasciitis of the round ligament. Report of a case. *Obstet Gynecol* 1962; 19:397-400.
5. Hagiwara Y, Hatori M, Moriya T, et al. Inguinal endometriosis

- attaching to the round ligament. *Australas Radiol* 2007; 51:91-4.
6. Warshauer DM, Mandel SR. Leiomyoma of the extraperitoneal round ligament: CT demonstration. *Clin Imaging* 1999; 23:375-6.
  7. Smith P, Heimer G, Norgren A, Ulmsten U. The round ligament: a target organ for steroid hormones. *Gynecol Endocrinol* 1993; 7:97-100.
  8. Lösch A, Haider-Angeler MG, Kainz C, Breitenacker G, Lahodny J. Leiomyoma of the round ligament in a postmenopausal woman. *Maturitas* 1999; 31:133-5.
  9. Folpe AL. Neoplasms with perivascular epithelioid cell differentiation (PEComas). In: Fletcher CDM, Unni KK, Mertens F, eds. *World Health Organization Classification of Tumours Pathology and Genetics of Tumours of Soft Tissue and Bone*. Lyon: IARC Press, 2002: 221-2.
  10. Gunia S, Awwadeh L, May M, Roedel S, Kaufmann O. Perivascular epithelioid cell tumor (PEComa) with perirenal manifestation. *Int J Urol* 2005; 12:489-92.
  11. Casillas J, Joseph RC, Guerra JJ Jr. CT appearance of uterine leiomyomas. *Radiographics* 1990; 10:999-1007.
  12. Michel P, Viola D. [Abdomino-pelvic leiomyoma of the round ligament: contribution of computed tomography and magnetic resonance imaging]. *J Gynecol Obstet Biol Reprod (Paris)* 2003; 32:571-4. French.