

Robotic-assisted surgery for low rectal dissection: from better views to better outcome

Ng K H, Lim Y K, Ho K S, Ooi B S, Eu K W

ABSTRACT

Introduction: The use of robotics in colorectal surgery is relatively new. The first few cases of colonic surgery using da Vinci Surgical System were reported in 2002. Since then, several centres had reported on their experience, with favourable outcomes. Our department started to embark on robotics in colorectal surgery in December 2007. The aim of our paper was to share our early experience with robotics in colorectal surgery and provide an update on the current status of robotics.

Methods: Preparations included formal training with the da Vinci Surgical System, certification of the surgeons, and obtaining Hospital Ethics committee approval. We used a hybrid technique of laparoscopic and robotic assistance in the resection of mid- to low-rectal cancer (total mesorectal excision). Laparoscopic approach was used to isolate the inferior mesenteric artery and for mobilisation of the left colon. The da Vinci robot was used in the dissection of the rectum down to the pelvic floor. We reviewed the outcomes of our early experience with emphasis on feasibility and safety.

Results: Over a period of three months, we performed eight cases of robotic-assisted colorectal surgery for cancer. The median age of the patients was 55 (range 42–80) years. The median operating time was 192.5 (range 145–250) minutes. There were no intraoperative or postoperative complications related to the use of robotics. The median length of hospital stay was five (range 4–30) days.

Conclusion: Robotic-assisted laparoscopic colorectal surgery is a safe and feasible procedure.

Keywords: da Vinci robotics, laparoscopic

surgery, rectal cancer, robotic surgery, total mesorectal excision

Singapore Med J 2009;50(8):763-767

INTRODUCTION

The first robotic surgery was a case of cholecystectomy performed by Cadere in 1997.⁽¹⁾ Since then, robotic assistance has found applications in various fields of surgery, especially in urological, cardiothoracic and gynaecological procedures.⁽²⁾ However, the use of robotics in colorectal surgery is relatively new. The first few cases of colonic surgery using da Vinci® Surgical System (Intuitive Surgical, Sunnyvale, CA, USA) were reported in 2002.^(3,4) Since then, several centres had reported favourable outcomes on their experience.⁽⁵⁻¹³⁾ A recent randomised controlled trial had shown that the robotic-assisted approach was safe and comparable to the laparoscopic approach for rectal cancer resection.⁽¹⁴⁾ The Department of Colorectal Surgery, Singapore General Hospital, started to embark on robotics in colorectal surgery in December 2007. The aim of our paper was to share our early experience with robotics in colorectal surgery and provide an update on the current status of robotics.

METHODS

Preparations for the robotic programme for colorectal surgery started in December 2007. Four surgeons from the Department of Colorectal Surgery, with extensive experience in laparoscopic colorectal surgery, underwent a two-day, off-site training programme as console surgeon, conducted by Intuitive Surgical® (Sunnyvale, CA, USA). The training programme consisted of didactic and practical skill hands-on training sessions, covering the use of the da Vinci® Surgical System and EndoWrist® (Intuitive Surgical, Sunnyvale, CA, USA) instruments. All four surgeons were certified in the use of robotics at the end of the programme. Hands-on live-surgery workshops were conducted on pigs to practise the use of the robotic systems. Approval from the Institutional Review Board was obtained before the first case of robotic colorectal surgery.

All the patients underwent colonoscopy, endorectal

Department of
Colorectal Surgery,
Singapore General
Hospital,
Outram Road,
Singapore 169608

Ng KH, MBBS,
FRCS, FAMS
Consultant

Lim YK, MBBS,
FRCS, FAMS
Associate Consultant

Ho KS, MBBS, FRCS
Senior Consultant

Ooi BS, MBBS,
FRCS, FAMS
Senior Consultant

Eu KW, MBBS,
FRCS, FAMS
Senior Consultant
and Head

Correspondence to:
Prof Eu Kong Weng
Tel: (65) 6321 4677
Fax: (65) 6226 2009
Email: eu.kong.
weng@sgh.com.sg

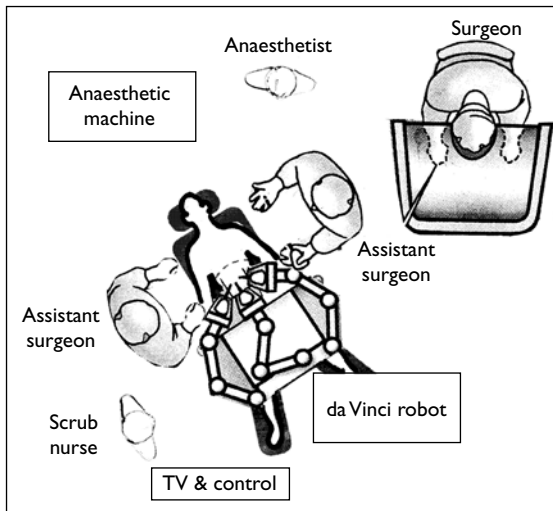


Fig. 1 Layout of the operating theatre for robotic-assisted laparoscopic colorectal surgery.

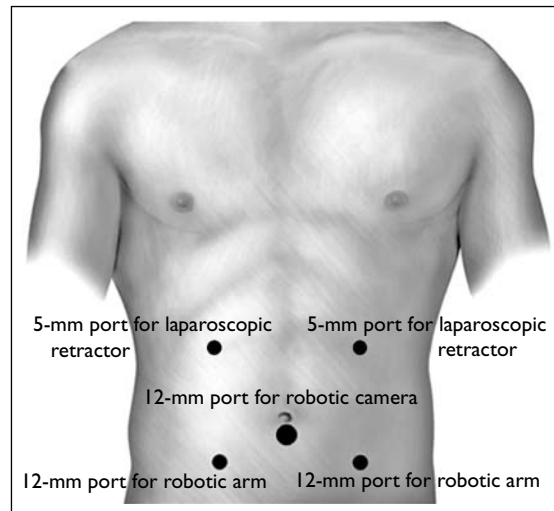


Fig. 2 Diagram shows port placement for robotic-assisted laparoscopic low rectal dissection.

ultrasonography and staging computed tomography of the abdomen and pelvis before surgery. Patients with previous multiple abdominal surgeries, morbid obesity and poor cardiac function were excluded from the study. The patients were fully informed about the robotic technique, and written consents were undertaken for all the patients. In addition to the standard consent form for colorectal surgery, patients were informed of this novel technique, its advantages and possible complications. These explanations to the patients were meticulously documented in the case record and witnessed by another surgeon. Bowel preparation with 2 L of polypethylene glycol solution was given to each patient the day before surgery.

We used a hybrid technique of laparoscopic and robotic assistance in the resection of mid- to low-rectal cancer (total mesorectal excision [TME]). The laparoscopic approach was used to isolate the inferior mesenteric artery and for mobilisation of the left colon. The da Vinci[®] robot was used in the dissection of the rectum down to the pelvic floor. The layout of the operating theatre for robotic-assisted colorectal surgery is illustrated in Fig. 1. After the induction of general anaesthesia, the patient was placed in a Trendelenburg, modified lithotomy position. The placement of ports is shown in Fig. 2. A subumbilical incision was made for the open insertion of the 12-mm camera port. The other four working ports were inserted under direct visualisation, with the aid of a laparoscopic camera through the subumbilical port. Laparoscopy was performed, and a decision was made to proceed with the hybrid laparoscopic and robotic technique if there were no prohibitive conditions like dense adhesions, significant bowel distension, etc. At this point, the nursing staff would be instructed to apply sterile drapes to the da

Vinci[®] robot. In the meantime, the laparoscopic part of the procedure would commence. We performed a medial to lateral approach in the dissection of the left colon and splenic flexure. The inferior mesenteric vein was isolated and transected with a vascular stapler near the duodenojejunal flexure. The inferior mesenteric artery was isolated and transected with another vascular stapler at its origin. Splenic flexure mobilisation was performed and dissection carried out down to the rectosigmoid junction. A cotton tape was applied to the rectosigmoid junction as a sling for subsequent retraction in the robotic phase. This retraction on the sling was performed by an assistant surgeon standing on the left side of the patient, through the left upper quadrant 5-mm port.

At this stage, the laparoscopic camera and instruments were removed. The da Vinci[®] robot was moved and docked in between the patient's legs. The robotic camera and arms were placed in positions as shown in Fig. 1. Robotic-assisted retraction of tissue was performed with the robotic Cadere forceps through the left lower 12-mm port. Dissection was performed with the robotic cautery hook through the right lower 12-mm port. Additional retraction was provided by the assistant surgeon through the right upper 5-mm port. TME was performed for all cases of mid- and low-rectal cancers, down to the level of levator ani muscles. The pelvic autonomic nerve plexus was carefully preserved during the robotic pelvic dissection. Transaction of the rectum at the level of levator ani was performed with laparoscopic intestinal stapler, EndoGIA[™] bowel stapler (Covidien, Norwalk, CT, USA). The specimen was extracted through an extension of the left lower 12-mm port site, with the wound measuring up to 5 cm, depending on the size of the specimen. A DST EEA[™] 28-mm stapler anvil (Covidien, Norwalk, CT,

Table I. Clinical profiles of the patients who underwent robotic-assisted colorectal surgery.

Patient no.	Age (years)	Gender	Tumour from anal verge (cm)	Surgery	Operative time (mins)	TNM staging	Lymph node involved
1	62	F	15	High AR	185	T3 N0	0/19
2	54	M	15	High AR	145	T1 N0	0/10
3	56	F	7	ULAR	250	T1 N1	1/11
4	53	M	10	ULAR	165	T2 N0	0/12
5	80	M	4	ULAR	190	T2 N0	0/2
6	80	M	4	ULAR	195	T3 N1	2/23
7	42	M	5	ULAR	200	T3 N0	0/26
8	48	F	7	ULAR	220	Carcinoid tumour	

AR: anterior resection; ULAR: ultra-low anterior resection.

USA) was inserted into the proximal colon and secured with purse-string suture. The wound was closed after the colon was returned into the abdominal cavity. With the re-establishment of the pneumoperitoneum, an end-to-end anastomosis was performed with DST EEA™ stapler (Covidien, Norwalk, CT, USA). The anastomosis was tested with air insufflation. A drain was placed near the anastomosis in the pelvis through the right lower 12-mm port. A temporary defunctioning stoma was routinely created for all low colorectal anastomosis and through the extension of the right upper 5-mm port site. Postoperatively, the patients were started on clear feeds and soft diet on the first and third postoperative days, respectively. The pelvis drain was removed on the fourth postoperative day, and the patients were discharged with a follow-up appointment at the specialist outpatient clinic two weeks later.

RESULTS

A total of eight cases of robotic-assisted colorectal resection were performed between March 22, 2008 and July 12, 2008. The clinical profiles and surgical outcomes of these eight patients are summarised in Table I. The first two cases in our series were relatively small tumours in the rectosigmoid region, with high anterior resections performed. The subsequent six cases were mid- to low-rectal cancer with ultra-low anterior resections (TMEs) done. These six cases had creation of a temporary defunctioning stoma. The median age of the patients was 55 (range 42–80) years. There were five male and three female patients involved in this series.

The median operating time was 192.5 (range 145–250) minutes. There were no intraoperative or postoperative complications related to the use of robotics. Intraoperative blood loss was minimal for all patients and, no patient required blood transfusion in the perioperative period. The median length of hospital stay was five (range 4–30) days. One patient had a pre-existing moderate chronic obstructive lung disease and had a prolonged hospital stay

due to pneumonia. This was the only case of morbidity in our initial experience. All other patients were discharged within 4–5 days after surgery. Urinary catheters were successfully removed on the second or third postoperative day, and no patient developed retention of urine thereafter. There was no 30-day hospital mortality. With a median follow-up of six weeks, no patient had significant morbidity when reviewed at the outpatient clinic.

Histology of the first seven cases was adenocarcinoma of colorectal origin. The last case was a rectal carcinoid tumour measuring 2 cm in size. The final histopathological staging of the tumour is shown in Table I. The median lymph node harvested in the resected specimen was 15 (range 2–26). Circumferential resection margins were clear for all the patients. Seven patients had clear distal resection margins of at least 2 cm. Six patients had early colorectal cancer (Stages I and II). Only one patient had Stage III rectal cancer.

DISCUSSION

The use of laparoscopy in colorectal surgery offers patients many short-term benefits like lesser postoperative pain, faster recovery and better cosmesis.⁽¹⁵⁾ More recently, the laparoscopic approach for colorectal cancer surgery has also been validated by the mid-term results of several randomised controlled trials.⁽¹⁶⁾ However, there are several technical limitations in laparoscopic colorectal cancer surgery that limit its widespread use.⁽¹⁷⁾ Firstly, unlike procedures such as laparoscopic cholecystectomy, the operative field in colorectal surgery is not a fixed one. The field of dissection in colorectal surgery is wider and the laparoscope has to move frequently from one area in the abdomen to another throughout the whole procedure. Thus, the assisting surgeon operating the laparoscope has to be familiar with the procedure and communicate with the primary surgeon constantly. Secondly, the primary surgeon has to depend heavily on the retraction provided by the first assistant for an optimal operating condition. This can be quite challenging in a narrow operative space

Table II. Studies on the use of robotics in colorectal surgery.

Author	Year	Country	No. of cases
Delaney et al ⁽⁵⁾	2003	Ohio, USA	6
Giulianotti et al ⁽⁶⁾	2003	Grosseto, Italy	16
D'Annibale et al ⁽⁷⁾	2004	Padova, Italy	53
Anvari et al ⁽⁸⁾	2004	Ontario, Canada	10
Woeste et al ⁽⁹⁾	2005	Frankfurt, Germany	4
Rawlings et al ⁽¹⁰⁾	2007	Illinois, USA	30
Hellan et al ⁽¹¹⁾	2007	California, USA	39
Spinoglio et al ⁽¹²⁾	2008	Alessandria, Italy	50
Baik et al ⁽¹³⁾	2008	Seoul, Korea	9

like the deep pelvis. Thirdly, laparoscopic instruments have a very limited degree of movement and are suboptimal in providing retraction and dissection in the deep pelvis.

The use of the robotic system has overcome these shortcomings of the laparoscopic approach, by enhancing visualisation, precision, control and dexterity.⁽¹⁸⁾ With the robotic system, the surgeon is in direct control of both the operative view and retraction, thus eliminating the dependence on close coordination with assistant surgeons. Robotic instruments have up to 7° of fine wrist movement for dissection and retraction, providing precision and ease of surgery in confined spaces. This is especially important during rectal cancer resection in the deep pelvis. Three-dimensional visualisation provided by the robotic system allows a greater appreciation of depth during surgery. Together with the higher magnification of the robotic camera system, identification of small anatomical structures can be achieved. This is especially important in the resection of low rectal cancer in which identification and preservation of the pelvic nerves can be achieved with ease with the robotic system. This may in turn reduce the incidence of sexual, urinary and anorectal dysfunction after proctectomy. Last but not least, there is added comfort and ergonomics as the first surgeon sits on the comfortable surgeon console and does not have to scrub up.

The results of studies done for robotic-assisted laparoscopic colorectal surgery over the past six years are shown in Table II. Delaney et al did a matched comparison between robotic-assisted and traditional laparoscopic surgery, and found that the main difference was that robotic surgery on average took 57 minutes longer and cost US\$350 more than traditional laparoscopic surgery.⁽⁵⁾ The largest robotic-assisted laparoscopic colorectal surgery series to date was reported by D'Annibale et al.⁽⁷⁾ This study showed that there was no difference in operating time, blood loss, number of lymph nodes resected, or postoperative recovery between the laparoscopic and robotic-assisted approaches. However, they found that the

dexterity and flexibility of the da Vinci® Surgical System to be very useful in certain stages, such as splenic flexure mobilisation, dissection of the inferior mesenteric artery with identification of the nervous plexus, and dissection in the narrow pelvis.⁽⁷⁾ Likewise, Anvari et al also had similar results which did not show a statistical difference between robotic-assisted and laparoscopic surgeries, other than a longer operating time due to the time needed to set up the robotic arms.⁽⁸⁾ The question of oncological clearance, especially in robotic-assisted low anterior resection with TME for low rectal cancer, has been discussed in two recent studies.^(11,13) Both studies concluded that robotic-assisted resection for low rectal cancer can be performed safely and effectively using the da Vinci® Surgical System, with acceptable short-term perioperative outcomes and equivalent oncological clearance. These results were supported by a randomised controlled trial conducted by one of the two groups.⁽¹⁴⁾ The outcomes for our first eight patients were comparable to those in the literature in terms of operating time, absence of perioperative complications, blood loss, postoperative recovery and oncological clearance. Therefore, our early experience indicated that robotic-assisted surgery for rectal cancer is feasible and safe.

REFERENCES

- Himpens J, Leman G, Cadiere GB. Telesurgical laparoscopic cholecystectomy. *Surg Endosc* 1998; 12:1091.
- Lanfranco AR, Castellanos AE, Desai JP, Meyers WC. Robotic surgery: a current perspective. *Ann Surg* 2004; 239:14-21.
- Weber PA, Merola S, Wasielewski A, Ballantyne GH. Telerobotic-assisted laparoscopic right and sigmoid colectomies for benign disease. *Dis Colon Rectum* 2002; 45:1689-94.
- Hashizume M, Shimada M, Tomikawa M, et al. Early experiences of endoscopic procedures in general surgery assisted by a computer-enhanced surgical system. *Surg Endosc* 2002; 16:1187-91.
- Delaney CP, Lynch AC, Senagore AJ, Fazio VW. Comparison of robotically performed and traditional laparoscopic colorectal surgery. *Dis Colon Rectum* 2003; 46:1633-9.
- Giulianotti PC, Coratti A, Angelini M, et al. Robotics in general surgery: personal experience in a large community hospital. *Arch Surg* 2003; 138:777-84.
- D'Annibale A, Morpurgo E, Fisco V, et al. Robotic and laparoscopic surgery for treatment of colorectal diseases. *Dis Colon Rectum* 2004; 47:2162-8.
- Anvari M, Birch DW, Bamehriz F, Gryfe R, Chapman T. Robotic-assisted laparoscopic colorectal surgery. *Surg Laparosc Endosc Percutan Tech* 2004; 14:311-5.
- Woeste G, Bechstein WO, Wullstein C. Does telerobotic assistance improve laparoscopic colorectal surgery? *Int J Colorectal Dis* 2005; 20:253-7.
- Rawlings AL, Woodland JH, Vegunta RK, Crawford DL. Robotic versus laparoscopic colectomy. *Surg Endosc* 2007; 21:1701-8.
- Hellan MA, Anderson C, Ellenhorn JD, Paz B, Pigazzi A. Short-term outcomes after robotic-assisted total mesorectal excision for rectal cancer. *Ann Surg Oncol* 2007; 14:3168-73.
- Spinoglio G, Summa M, Priora F, Quarati R, Testa S. Robotic

- colorectal surgery: first 50 cases experience. *Dis Colon Rectum* 2008; 51:1627-32.
13. Baik SH, Lee WJ, Rha KH, et al. Robotic total mesorectal excision for rectal cancer using four robotic arms. *Surg Endosc* 2008; 22:792-7.
14. Baik SH, Ko YT, Kang CM, et al. Robotic tumor-specific mesorectal excision of rectal cancer: short-term outcome of a pilot randomized trial. *Surg Endosc* 2008; 22:1601-8.
15. Tjandra JJ, Chan MK. Systematic review on the short-term outcome of laparoscopic resection for colon and rectosigmoid cancer. *Colorectal Dis* 2006; 8:375-88.
16. Bonjer HJ, Hop WC, Nelson H, et al. Laparoscopically assisted vs open colectomy for colon cancer: a meta-analysis. *Arch Surg* 2007; 142:298-303.
17. Hance J, Rockall T, Darzi A. Robotics in colorectal surgery. *Dig Surg* 2004; 21:339-43.
18. Kariv Y, Delaney CP. Robotics in colorectal surgery. *Minerva Chir* 2005; 60:401-16.



Looking to hit that sales target?

Advertise with the **Singapore Medical Journal.**

The voice of academic medicine in Singapore and Southeast Asia since 1960

To advertise, please contact: **Li Li Loy**, Advertising Executive
Mobile: **9634 9506** Tel: **6223 1264 ext 23** Email: lili@sma.org.sg