

Reversible intraventricular conduction defect in aconitine poisoning

Yim K M, Tse M L, Lau F L

ABSTRACT

Chinese medicine plays an important role in providing medical care for people in countries with large Chinese communities, including Hong Kong. The aconite herb is one of the commonly-prescribed ingredients for various clinical problems. However, due to its narrow therapeutic index, toxicities are not uncommonly encountered, including life-threatening cardiac arrhythmias like ventricular arrhythmias. We report a 57-year-old woman with reversible intraventricular conduction defect attributed to the use of processed *Fuzi*.

Keywords: aconitine poisoning, intraventricular conduction defect, reversible intraventricular conduction defect, processed *Fuzi*, right bundle branch block

Singapore Med J 2009;50(8):e302-e305

INTRODUCTION

In Hong Kong, it has been reported that 18.4% of medical consultations were provided by the Chinese medicine practitioners in 2002.⁽¹⁾ Our local study revealed the prevalence of Chinese medicine-associated adverse drug reaction was 7.6%, and most of them were mild.⁽²⁾ However, it is not uncommon for us to encounter life-threatening events like seizures, coma or arrhythmias with the use of Chinese medicine. We report a case of reversible intraventricular conduction defect attributed to the use of processed *Fuzi*.

CASE REPORT

A 57-year-old woman, with a known history of uncomplicated hypertension and on regular oral nifedipine, presented with generalised weakness and discomfort one hour after consumption of a herbal broth which contained Radix Astragali 9 g (*Beiqi* or 北芪三錢), processed Radix Aconiti Lateralis Praeparata 9 g (*Fuzi* or 熟附子三錢), Ramulus Cinnamomi 9 g (*Guizhi* or 桂枝三錢), Cortex Moutan Radicis 9 g (*Danpi* or 丹皮三錢), Rhizoma Alismatis 9 g (*Zexie* or 澤瀉三錢), Radix Dioscoreae 9 g (*Huaishan* or 淮山三錢), Poria 15 g (*Fuling* or 茯苓五錢), Radix Codonopsis 9 g (*Dangshen*

or 黨參三錢), Epimedium Brevicornum Maxim 6 g (*Xianlingpi* or 仙靈脾二錢), Semen Plantaginis 9 g (*Cheqianzi* or 車前子三錢), and Caulis Akebiae 9 g (*Mutong* or 木通三錢). The formula of the herbal broth was obtained from a newspaper article a few years ago and had claimed to be used for “increasing one’s power” or in Chinese, 補氣. The patient obtained the herbs from one of the herbal shops herself. It was the first time that she took this herbal broth.

She presented to one of the accident and emergency departments in Hong Kong three and a half hours after taking the herbal broth, complaining of generalised weakness, numbness, dizziness and discomfort. She had hypotension with a blood pressure of 84/47 mmHg and a pulse rate of 53/minute. She was fully alert, and there was no focal neurological or cerebellar sign except subjective numbness affecting her four limbs. Other examinations were all unremarkable. She was given a bolus of 250 ml normal saline. Bedside electrolytes revealed normal sodium and high normal potassium of 5.2 mmol/L. Both renal and liver function tests were unremarkable. Electrocardiography was performed and revealed a sinus rhythm with a right bundle branch block (Fig. 1). There was no old electrocardiogram (ECG) available for comparison. Blood was taken for urgent digoxin level, which later turned out to be negative, and she was put on cardiac monitoring. She was taking only nifedipine 20 mg slow-release preparation for her hypertension. She took the herbal broth one hour before the onset of her symptoms.

She remained hypotensive despite receiving the bolus of normal saline. Her pulse was getting slower, around 40–45/minute. A bolus of 0.6 mg atropine was given and her pulse rate increased to 87/minute, with blood pressure improving to 147/80 mmHg. She was symptom-free with a stable blood pressure six hours after her consumption of the herbal broth. Electrocardiography taken 13 hours after ingestion revealed a complete resolution of the right bundle branch block (Fig. 2). She was discharged at 15 hours post-ingestion. 15 g of *Fuzi* was identified in the unused raw herbal medication. Urine toxicology screening using the gas chromatography-mass spectrometry method, revealed mesaconitine, hypoaconitine, aconitine and deoxyaconitine.

Hong Kong Poison Information Centre, Room 2A, Block K, United Christian Hospital, 130 Hip Wo Street, Kwun Tong, Hong Kong

Yim KM, MRCSE, FHKAM, FHCCEM Resident Specialist

Tse ML, FRCSE, FHKAM, FHKCEM Consultant

Lau FL, FRCPE, FHKAM Director and Chief of Service, Department of Accident and Emergency

Correspondence to: Dr Yim Kin-Ming Tel: (852) 3513 5263 Fax: (852) 3513 5649 Email: anfernee_yim@hotmail.com

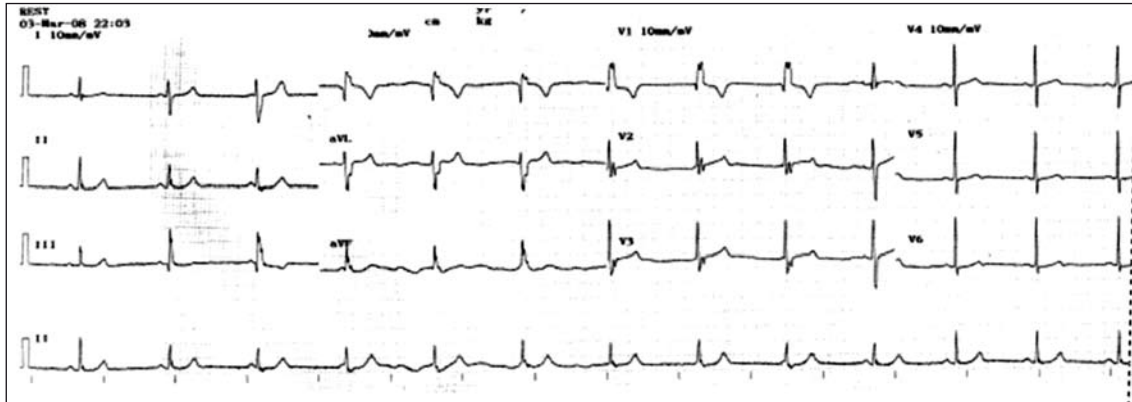


Fig. 1 ECG of the patient taken at initial presentation, 3.5 hours after the consumption of a herbal broth, shows a sinus rhythm with a right bundle branch block.

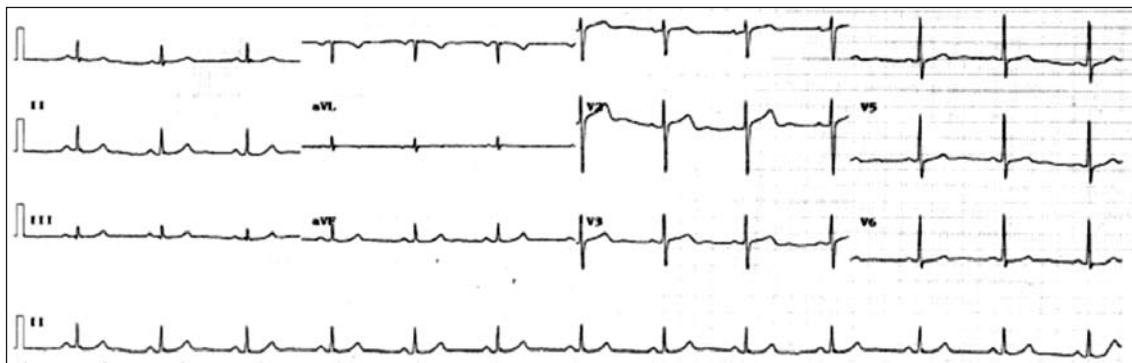


Fig. 2 ECG of the patient taken 13 hours after the consumption of the herbal broth shows a complete resolution of the right bundle branch block.

DISCUSSION

Hong Kong is an international city with an integration of Chinese and Western culture. This intercultural environment also extends to the health-seeking behaviour of our local people. In 2002, Chinese medicine practitioners provided 18.4% of medical care in Hong Kong.⁽¹⁾ It is not uncommon for healthcare providers to treat patients presenting with various degrees of adverse drug effects secondary to their consumption of herbal medications. However, managing patients with herbal poisoning is even more challenging, partly because of inadequate knowledge about the safety, pharmacology, practice and efficacy of Chinese medicine. Deng et al reported that up to 47% of potentially toxic effects of the use of traditional Chinese medicine were either unknown or could not be found in the literature.⁽³⁾

The use of aconite herbs has been known since ancient times. It is believed to have the ability to expel wind and eliminate dampness, warm the meridians to disperse cold, and reduce swelling to relieve pain.⁽⁴⁾ Clinically, it is used as an anti-inflammatory analgesic for various conditions, especially arthralgia, rheumatism and sciatica, and as cardiostimulant agents.⁽⁵⁾ In Hong Kong,

according to the Chinese Medicine Ordinance, Chinese herbal medicines (CHM) are classified as Schedule I and II medications. Schedule I herbs are those toxic herbs which are forbidden, while the remaining herbs are Schedule II herbal medications. Altogether, there are 31 Schedule I herbs in Hong Kong. Aconite herbs are the most common culprit of severe herbal poisoning in Hong Kong.^(5,6) Aconites are the dried rootstocks of plants of the *Aconitum* spp. *Chuan Wu* (*Radix Aconiti*), *Cao Wu* (*Radix Aconiti Kusnezoffii*) and *Fuzi* (*Radix Aconiti Lateralis Praeparata*) are the most commonly-used aconite herbs. Crude *Chuan Wu* and *Cao Wu* are Schedule I herbs, while their processed products, processed *Chuan Wu* and processed *Cao Wu* are Schedule II herbal medications. Both *Chuan Wu* and *Cao Wu* belong to the parent or axial root, while *Fuzi* comes from its daughter or lateral root.⁽⁷⁾

Aconitum alkaloids are the active ingredients in aconite herbs. They are C19-diterpenoid alkaloids with aconitine, mesaconitine, hypaconitine and yunaconitine being commonly identified.^(8,9) These alkaloids are lipid-soluble and can therefore access and bind to the binding site 2 in the plasma membrane of voltage-gated sodium

channels, resulting in keeping the channel open for a longer period of time and effectively causing persistent activation of the channels.⁽¹⁰⁾ The persistent activation of the channels is responsible for its neurotoxicities and cardiotoxicities clinically. The amount and composition of different alkaloids vary, depending on the species, place of origin, time of harvest and method of processing.⁽¹¹⁾ Crude or raw aconite tubers are very toxic, and therefore, must be processed, for example, by soaking or boiling in water before use, in order to lessen the toxicity by hydrolysis of the aconitine alkaloids into less toxic derivatives, such as benzyaconines and aconines.⁽⁸⁾ The recommended dose for processed *Chuan Wu* and processed *Cao Wu* is 1.5–3 g and that for *Fuzi* is 3–15 g.⁽⁴⁾

Patients with aconitine poisoning typically experience symptoms within an hour and can be as short as ten minutes⁽¹²⁾ after ingesting the herbs. They usually present with paraesthesia, numbness affecting the mouth and limbs, weakness, nausea, vomiting and bradycardia. Ventricular dysrhythmias and refractory cardiovascular collapse account for life-threatening toxicities in severe aconitine poisoning.⁽¹³⁻¹⁵⁾ Enhancement of the transmembrane inward sodium current during the plateau phase of the action potentially prolongs repolarisation in cardiac myocytes, and results in after-depolarisations with triggered automaticity, which underlies the ventricular dysrhythmias.⁽¹⁶⁾

It has been reported that frequent ventricular ectopics, polymorphic ventricular ectopics, ventricular tachycardia, sinus tachycardia and sinus bradycardia constitute the most commonly-encountered ECGs in aconitine poisoning.⁽¹⁷⁾ Ventricular arrhythmia was reported as the most common ECG finding in acute aconitine poisoning⁽¹⁸⁾ in another series. However, intraventricular blockage resulting in bundle branch block has rarely been reported. Lee reported a case of aconitine-induced left bundle branch block in 1994.⁽¹⁹⁾ Ventricular fibrillation accounts for most mortalities in aconitine poisoning.⁽¹³⁾ People who have recovered from the toxicity are expected to be symptom-free and do not experience any long-term consequences.^(13,18)

In our patient, several possible explanations could account for her poisoning. She may be given a large dose of *Fuzi* by the herbal shop, although the amount of *Fuzi* in another unused herbal medication was only 15 g. It is a common practice for the herbalists who prepare the herbs in the medicinal herbal shops not to measure the amount of drugs being dispensed, but to estimate the amount purely based on one's personal experience. It is also because of this peculiar sort of practice and lack

of quality control that misidentification and substitution of herbs are not uncommon in the practice of CHM, and may account for some of the preventable CHM poisonings. Contamination with another herb has also been reported in Hong Kong as the one of the causes for Chinese medicine poisoning.^(6,20) With more education and awareness of safer practices of Chinese medicine in Hong Kong, some of the herbal shops have begun to prescribe herbs using commercially-available powdered form of preparations.

In conclusion, the use of CHM is quite common among the indigenous Chinese, including in Hong Kong. We are expected to deal with acute toxicities secondary to the consumption of CHM. Aconite herb poisoning constitutes one of the most commonly reported and severe herbal poisoning, because of its neurotoxicities and cardiotoxicities, with ventricular dysrhythmias accounting for most of the cardiovascular deaths. Various electrocardiographical abnormalities have been identified in aconite herbs poisoning; however, bundle branch block has rarely been reported previously. We report a case of reversible right bundle branch block in acute aconite herb poisoning. Physicians should be well-equipped with the knowledge and treatment of acute herbal poisoning as it is a real challenge when such cases are encountered.

REFERENCES

1. Thematic household survey report no. 8. Hong Kong: Census and Statistics Department, the Government of the Hong Kong Special Administrative Region; 2002.
2. Tse ML, Lau FL. Traditional Chinese medicine use among emergency patients in Hong Kong. *Hong Kong J Emerg Med* 2007; 14:151-3.
3. Deng JF, Lin TJ, Kao WF, Chen SS. The difficulty in handling poisonings associated with Chinese traditional medicine: a poison control center experience for 1991-1993. *Vet Hum Toxicol* 1997; 39:106-14.
4. Kuang LJ & Zhang K, eds. Pharmacopoeia of the People's Republic of China. Beijing: People's Medical Publishing, 2005.
5. Chan TY. Aconitine poisoning: a global perspective. *Vet Hum Toxicol* 1994; 36:326-8.
6. Chan TY, Chan JC, Tomlinson B, Critchley JA. Chinese herbal medicines revisited: a Hong Kong perspective. *Lancet* 1993; 342:1532-4.
7. Zhao ZZ, Li YS. Easily Confused Chinese Medicines in Hong Kong. 1st ed. Hong Kong: Chinese Medicine Merchants Association Ltd, 2007.
8. Chang HM, But PPH. Pharmacology and Applications of Chinese Material Medica. Vols. 1, 2. Singapore: World Scientific Publishing, 1987.
9. Poon WT, Lai CK, Ching CK, et al. Aconite poisoning in camouflage. *Hong Kong Med J* 2006; 12:456-9.
10. Denac H, Mevissen M, Scholtysik G. Structure, function and pharmacology of voltage-gated sodium channels. *Naunyn Schmiedebergs Arch Pharmacol* 2000; 362:453-79.
11. Bisset NG. Arrow poisonings in China. Part II. Aconitum – botany, chemistry and pharmacology. *J Ethnopharmacol* 1981; 4:247-336.
12. Lin CC, Chan TY, Deng JF. Clinical features and management

- of herb-induced aconitine poisoning. *Ann Emerg Med* 2004; 43:574-9.
13. Tai YT, But PP, Young K, Lau CP. Cardiotoxicity after accidental herb-induced aconite poisoning. *Lancet* 1992; 340:1254-6.
 14. Chan TY, Tomlinson B, Tse LK, et al. Aconitine poisoning due to Chinese herbal medicines: a review. *Vet Hum Toxicol* 1994; 36:452-5.
 15. So YT, Fung HT, Chung KL, Hung CY, Kam CW. A case of Chuanwu and Fuzi poisoning. *Hong Kong J Emerg Med* 2000; 7:230-3.
 16. Peper K, Trautwein W. The effect of aconitine on the membrane current in cardiac muscle. *Pflugers Arch Gesamte Physiol Menschen Tiere* 1967; 296:328-36.
 17. Nip KW, Law LS. Electrocardiogram analysis of 46 cases of aconitine poisoning. *J Pract Med Tech* 2004; 11:1029.
 18. Li LW, Qiu QM, Wu B. Characteristic and significance of ECG in the patients with acute aconitine poisoning. *Chin J Crit Care Med* 2007; 27:124-6.
 19. Lee WK. A case report of left bundle branch block in aconitine poisoning. *Guangxi J Tradit Chin Med* 1994; 17:32.
 20. Consumer Council, Hong Kong SAR. Product recalls and safety alerts. Contaminated Chinese herb *Rhizoma Atratyloidis*. In: Consumer Council [online]. Available at: www.consumer.org.hk/website/ws_en/consumer_alerts/recalls_and_alerts/2004070101.html. Accessed July 01, 2004.