

Successful management in neglected cases of adult anorectal malformation

Chakravartty S, Maity K, Ghosh D, Choudhury C R, Das S

ABSTRACT

Posterior sagittal anorectoplasty (PSARP) is the procedure of choice in cases of anorectal malformation in children. Adult patients can present with anorectal malformation in developing countries. As there is very little data regarding the success of PSARP in cases of adult anorectal malformations, the aim of this study was to perform and assess the effectiveness of PSARP in adults. Two adults (one male, one female) aged 16 and 17 years, respectively, underwent a diverting colostomy followed by a PSARP. The female underwent a posterior vaginal anorectoplasty due to a rectovaginal fistula and is leading a normal life. The male patient had a rectourethral fistula which required meticulous dissection and is now doing well with a Kelly's score of five. Our experience here suggests that a PSARP provided satisfactory results in adults who present late with an anorectal malformation.

Keywords: adult anorectal malformation treatment, adult posterior sagittal anorectoplasty, anorectal malformation, posterior sagittal anorectoplasty

Singapore Med J 2009;50(8):e280-e282

INTRODUCTION

Anorectal malformations (ARM) are commonly detected at birth and are treated according to their type. In a developing country like India, where poverty and the lack of knowledge go hand-in-hand, some patients may present late to a referral centre with an anorectal malformation, particularly in female patients who, besides an abnormal anal opening, may remain asymptomatic. While the landmark work of Pena et al have proven posterior sagittal anorectoplasty (PSARP) to be the treatment of choice in paediatric patients, there are no long series of adult cases to show that PSARP is equally effective in them. We present two adults, a female and a male patient, who presented with ARM. We performed a PSARP after a diverting colostomy and followed up on the patients to assess the outcome.

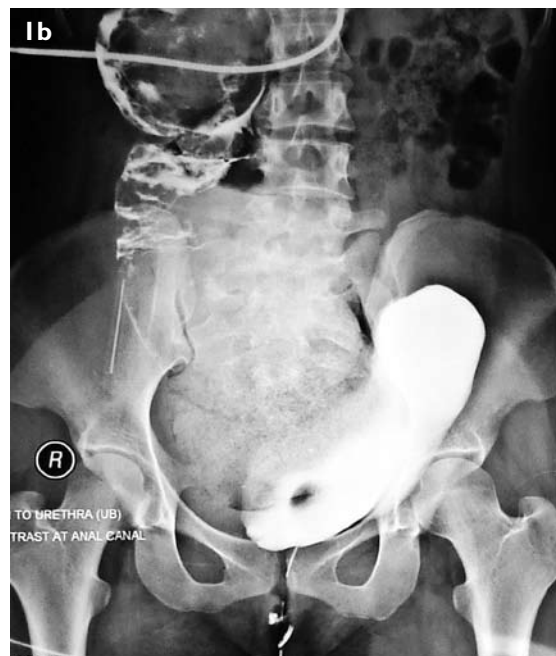
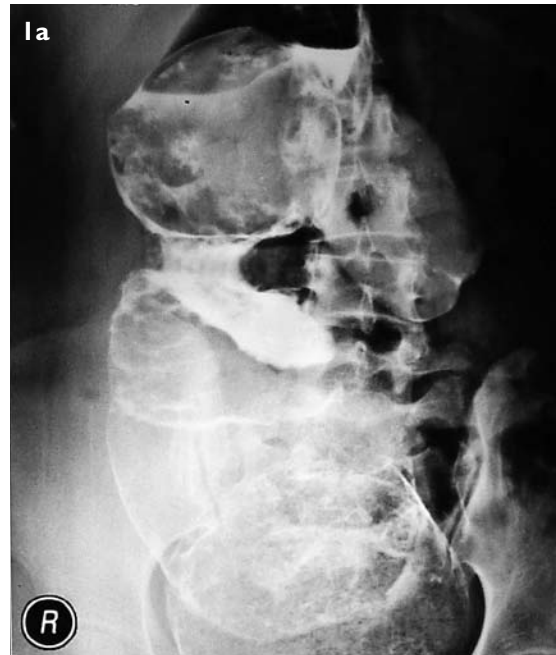
Fig. 1 (a) Case 1. Distal cologram in the female patient shows a hugely distended colon (pouch colon) with dye escaping from the vagina, confirming a low rectovaginal fistula. (b) Case 2. Distal cologram in the male patient shows contrast in the rectum and entering the urethra, confirming a rectourethral fistula.

CASE REPORTS

Case 1

A 16-year-old girl presented to the emergency department

Department of
Surgery,
Medical College
Kolkata,
88 College Street,
Kolkata 700073,
India

Chakravartty S, MBBS
MS, MRCS
Postgraduate Trainee

Maity K, MBBS, MS,
MRCS
Assistant Professor

Choudhury CR, MS,
FRCSE
Associate Professor

Department of
Paediatric Surgery

Ghosh D, MS, MCH,
DNB
Assistant Professor

Das S, MS, MCH
Professor and Head

Correspondence to:
Dr Saurav Chakravartty
Flat 2A & 2B,
201 Sarat Bose Road,
Kolkata 700029,
India
Tel: (91) 98 3000 5319
Fax: (91) 33 2465 5911
Email: saurav_tty@
yahoo.com

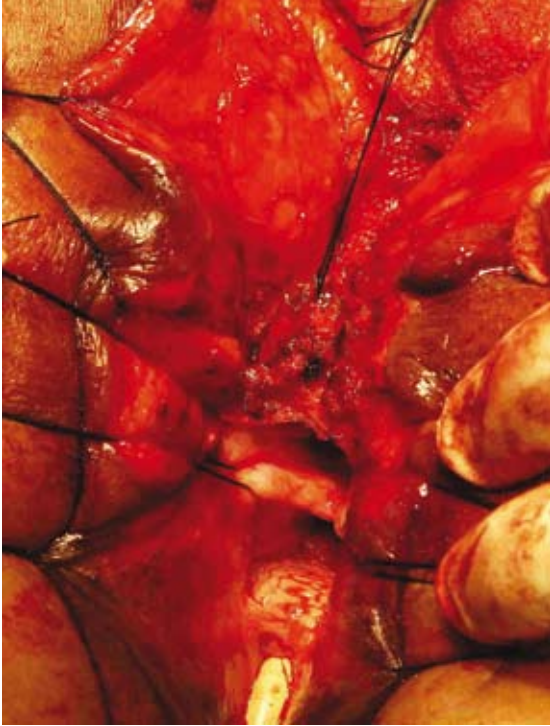

Fig. 2 Case 1. Intraoperative photograph shows the separation of the vagina and rectum.

with abdominal pain, distension and vomiting. On taking a detailed history, it was found that she had been suffering from an anorectal malformation since birth, and passing stools per vagina. She underwent a transverse colostomy as only a diversion could ameliorate her symptoms. However, her distal loop was loaded with hard, scybalous stool which was softened with regular use of liquid paraffin. Meanwhile, she underwent a complete work-up to define the extent of her anorectal malformation. A distal cologram was done which showed a low rectovaginal fistula with two openings (Fig. 1a). She had a fully developed sacrum, a normal gluteal cleft, and no other congenital abnormality.

She underwent a posterior sagittal anorectovaginoplasty two months later (Fig. 2). Her postoperative period was uneventful. Her anal sphincter demonstrated a weak partial squeeze. Three months later, after a distal cologram showed a patent distal pathway without any fistula, she underwent a colostomy closure. Postoperatively, she regularly used anal dilators. Presently, she has a weak anal tone but can differentiate between faeces and flatus and has had no episodes of soiling (accidents). Her Kelly's score of continence showed an overall score of five. At the time of the report, she was 17 years of age and living a normal life.

Case 2

A 17-year-old boy presented with a passage of stool with

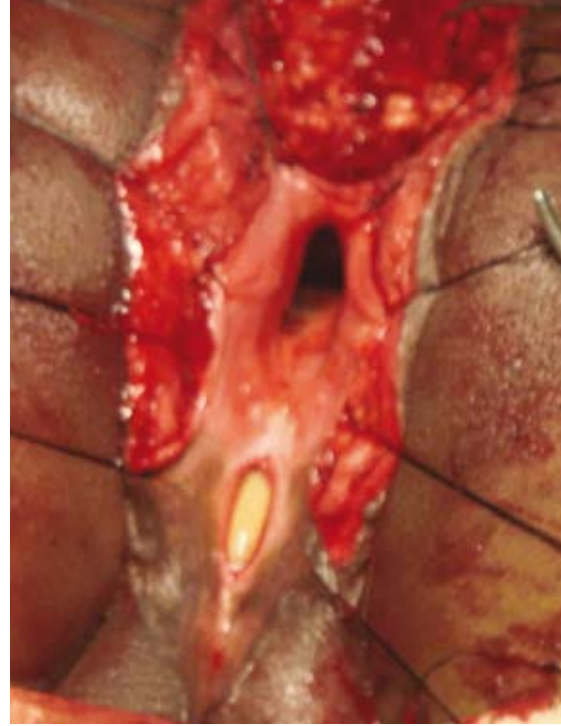


Fig. 3 Case 2. Intraoperative photograph shows the separation of the urethral fistula.

urine. He had an anorectal malformation at birth which was tampered with on the second day. He then developed a rectourethral fistula which presented after 17 years. On examination, he was found to have a scarred anal opening near the anal pit, through which both urine and liquid stool passed. An ascending urethrogram confirmed a connection between the anal dimple and the urethra (Fig. 1b). Apart from this, he also had agenesis of his sacrum, with only two segments being seen. Nevertheless, he underwent a transverse loop colostomy, followed by a posterior sagittal anorectoplasty six weeks later. The rectum was separated from the urethra and, the urethra was repaired meticulously. An urethroplasty was performed over a catheter (Fig. 3). The postoperative period was uneventful. He then used dilators and soon had an effective anal tone. The colostomy was subsequently closed. The patient was continent to both stool and flatus. He had no urinary problems and his Kelly's score of continence was five. He is now leading a normal life and his wounds have adequately healed at five months postoperatively (Fig. 4).

DISCUSSION

Pena et al in 1982 described the procedure of posterior sagittal anorectoplasty, which changed the concept of management of anorectal malformations.⁽¹⁾ Earlier treatment options included abdominoperineal, sacroabdominoperineal or sacroperineal pull-through procedures, and their results were inferior to PSARP. In

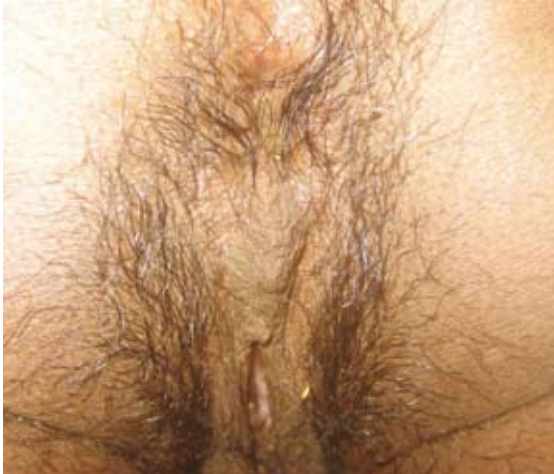

Fig. 4 Case 2. Photograph shows the successful postoperative outcome at the five-month follow-up.

recent years, the PSARP procedure has been the principal surgical method applied to patients with ARM.⁽²⁾ However, the possibility of this procedure in adults is yet to be convincingly evaluated. In adults, the development of the perianal muscles are complete, and there are no studies that compare the technical difficulties during the procedure between children and adults. There is an isolated case report of a primary repair of a rectovaginal fistula in an adult.⁽³⁾ A case series of secondary repair for persistent incontinence in adult patients with anorectal malformation was reported to be successful in a select group of patients.⁽⁴⁾ Another series suggested that PSARP could be successful in adults with rectal or anal carcinoma, to avoid a permanent colostomy.⁽⁵⁾ The prognosis was good in patients with a fully-developed sacrum, normal gluteal cleft with a normal bulk of gluteal muscle and an intact anal wink. Another important factor was the height of the defect.⁽⁶⁾ While magnetic resonance imaging can clearly demonstrate the anal sphincter complex, routine preoperative scans are not recommended unless a specific spinal defect is expected.⁽⁷⁾

We adhered to the steps of a classical Pena's procedure. The patients were operated on in a prone position. Traction sutures were applied around the anus. A midline posterior incision from the lower sacrum to the anus was made. Rectal mobilisation was done very carefully with close attention to the muscles of

continence, especially in the female, where the rectum was adherent to the vagina. Muscle stimulation was used for precise identification of the striated muscle complex. Minimum diathermy was used to limit the thermal damage. There are many scoring systems which assess continence after PSARP. We used the Kelly's score of continence, which takes into account the level of continence (no soiling: 2, occasional accidents like faeces or flatus escape: 1, no control: 0); staining (always clean: 2, occasional staining: 1, always stained: 0); and sphincter function (strong effective squeeze: 2, weak squeeze: 1, no contraction: 0). In fact, Kelly's score correlates very well with anal manometry.⁽⁸⁾ Therefore, this suggests that both our patients had good physiological function, and a postoperative endoanal ultrasonography was not required. While sacral agenesis is normally a poor prognostic factor for continence, our male patient was found to be satisfactorily continent postoperatively despite having only two sacral segments. Overall, our experience showed that posterior sagittal anorectoplasty provided satisfactory results in adults who present late with anorectal malformations.

REFERENCES

1. Peña A, Devries PA. Posterior sagittal anorectoplasty: important technical considerations and new applications. *J Pediatr Surg* 1982; 17:796-811.
2. Rintala RJ, Lindahl HG. Posterior sagittal anorectoplasty is superior to sacroperineal-sacroabdominoperineal pull-through: a long-term follow-up study in boys with high anorectal anomalies. *J Pediatr Surg* 1999; 34:334-7.
3. Simmang CL, Paquette E, Tapper D, Holland R. Posterior sagittal anorectoplasty: primary repair of a rectovaginal fistula in an adult: report of a case. *Dis Colon Rectum* 1997; 40:1119-23.
4. Simmang CL, Huber PJ Jr, Guzzetta P, Crockett J, Martinez R. Posterior sagittal anorectoplasty in adults: Secondary repair for persistent incontinence in patients with anorectal malformations. *Dis Colon Rectum* 1999; 42:1022-7.
5. Hamdy H, Abdul Wahab AM, Fakhroo A, Mohammed A. Posterior sagittal anorectoplasty in adults. *Br J Surg* 1994; 81:601-2.
6. Pena A. Anorectal malformations: new aspects relevant to adult colorectal surgeons. *Semin Colon Rectal Surg* 1994; 5:78-88.
7. Aslam A, Grier DJ, Duncan AW, Spicer RD. The role of magnetic resonance imaging in the preoperative assessment of anorectal anomalies. *Pediatr Surg Int* 1998; 14:71-3.
8. Bhat NA, Grover VP, Bhatnagar V. Manometric evaluation of postoperative patients with anorectal anomalies. *Indian J Gastroenterol* 2004; 23:206-8.