

# Acute naphthalene poisoning following the non-accidental ingestion of mothballs

Lim H C, Poulouse V, Tan H H

## ABSTRACT

**Ingestional naphthalene mothball poisoning leading to prolonged haemolysis and methaemoglobinaemia can present with diagnostic and therapeutic challenges. A 19-year-old woman ingested 12 mothballs, and presented two days later with haemolysis and methaemoglobinaemia. She was treated with red blood cell transfusions, intravenous methylene blue, N-acetylcysteine and ascorbic acid. Continuous venovenous haemofiltration was conducted for 45 hours. Haemolysis with anaemia and methaemoglobinaemia persisted even after five days post-ingestion. Clinical and biochemical parameters improved. We describe a case of ingestional naphthalene poisoning with a good outcome after treatment.**

**Keywords:** haemolysis, methaemoglobinaemia, mothball ingestion, naphthalene, poisoning

*Singapore Med J 2009;50(8):e298-e301*

## INTRODUCTION

Naphthalene mothballs, as a choice agent for deliberate ingestion in suicide, is uncommon in Singapore. Other more common agents that have led to patients requiring intensive care include organophosphates and carbamates, benzodiazepines, tricyclic antidepressants, and phenothiazine.<sup>(1)</sup> The fatal dose for naphthalene in humans is unknown, but as little as one mothball can result in toxicity in children. Deaths have been reported following ingestion of naphthalene balls.<sup>(2,3)</sup> Haemolytic anaemia and methaemoglobinaemia from poisoning can pose a diagnostic and therapeutic challenge to clinicians because it is not commonly encountered. We present a case of prolonged naphthalene-induced haemolysis and methaemoglobinaemia from a non-accidental ingestion of 12 naphthalene mothballs, and reviewed the mechanism of its toxicity, diagnostic dilemma and management recommendations.

## CASE REPORT

A 19-year-old female foreign student presented 40 hours after intentional oral ingestion of 12 mothballs. This was

due to school stress. She did not have any past medical history. She complained of giddiness and dark-coloured urine a few hours after the ingestion, but only sought medical help because of persistent symptoms. On the day of presentation, she vomited once and had mild suprapubic pain. Clinically, she was afebrile, her pulse rate was 109/minute, respiratory rate 16/minute, blood pressure 102/71 mmHg, oxygen saturation (SpO<sub>2</sub>) 82% on 100% oxygen via facemask. She was pale, jaundiced and appeared to have cyanosis. Heart sounds were dual with a grade 2/6 ejection systolic murmur heard at the heart apex. The lungs were clear with good air entry bilaterally. The abdomen was mildly tender in the suprapubic region, but soft and not guarded. No organomegaly was noted. Neurological examination was normal.

Urinary catheterisation collected dark-brown urine, which tested positive for blood on dipstick. The urine microscopy did not reveal significant red blood cells (RBC) content or casts, suggesting haemoglobinuria. Electrocardiogram showed normal sinus rhythm, with no ischaemic changes. At that time, the provisional diagnosis was haemolysis, haemoglobinuria and possibly methaemoglobinaemia secondary to naphthalene toxicity. She did not bring any remaining mothball for examination. Supportive management with oxygen and intravenous (IV) fluid was provided. Gastric washout and activated charcoal administration were not performed in view of delayed presentation. Alkalinisation of urine was initiated in the emergency department in an effort to prevent renal tubular damage, and she was admitted to the intensive care unit (ICU) for further management. Alkalinisation of urine was continued there.

Her initial full blood count revealed haemoglobin (Hb) 9.7 g/dL with haematocrit 27.4%, reticulocyte count 0.8%, total white cell count  $26.6 \times 10^3/\mu\text{L}$ , and neutrophil 84.1%. Intravascular haemolysis was confirmed by serum jaundice with total bilirubin measuring 84.0  $\mu\text{mol/L}$  and a highly-raised indirect bilirubin level, associated with low serum haptoglobin 0.09 g/L. Her platelet count and coagulation profile were normal. Renal function and the serum creatinine kinase were also normal. Liver enzyme aspartate transaminase was raised at 98 U/L, but alkaline phosphatase and alanine transaminase were normal. Arterial blood gas (ABG) analysis did not reveal

**Department of  
Emergency Medicine,  
Changi General  
Hospital,  
2 Simei Street 3,  
Singapore 529889**

Lim HC, MBBS,  
MRCSE, FAMS  
Consultant

Tan HH, MBBS,  
FRCSE, FAMS  
Consultant

**Division of  
Respiratory Medicine**

Poulouse V, MBBS,  
FCCP  
Consultant and  
Director, Medical  
Intensive Care Unit

**Correspondence to:**  
Dr Tan Hock Heng  
Tel: (65) 6850 1687  
Fax: (65) 6260 3756  
Email: hock\_heng\_tan  
@cgh.com.sg

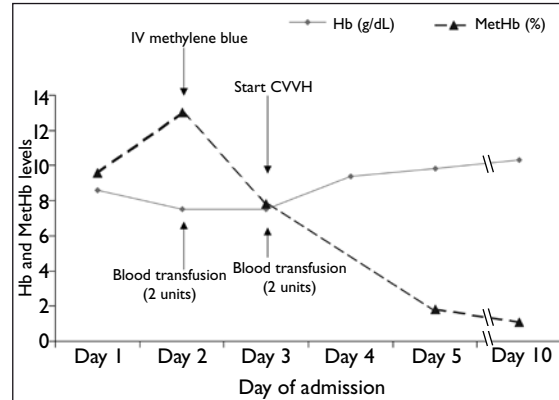
any acidosis; pH 7.423, pCO<sub>2</sub> 34.4 mmHg, pO<sub>2</sub> 380.0 mmHg, base excess -1.7 mmol/L, HCO<sub>3</sub> 21.9, O<sub>2</sub> Sat 100.0%. Serum lactic acid was normal.

Her first methaemoglobin (MetHb) level was 9.6% (Hb 8.6 g/dL). This increased to 13% on the second day of admission, with Hb dropping to 7.5 g/dL. IV methylene blue 60 mg (1.5 mg/kg) was prescribed on Day two of admission and she was transfused two units of RBC concentrate (total 730 ml). Oral ascorbic acid 300 mg and N-acetylcysteine (NAC) 1.2 g daily was started. On Day 3 of admission, the Hb remained at 7.5 g/dL, and there was only some improvement of MetHb to 7.8%. Ongoing haemolysis was suspected based on the failure of Hb to improve as well as the continued collection of dark-brown urine. Another two units of blood (total 780 ml) were transfused and continuous renal replacement therapy (CRRT) in the form of continuous venovenous haemofiltration (CVVH) was started. This continued for almost 45 hours till Day 5. Blood samples on Days 1 and 3 of admission were qualitatively positive for naphthalene; however, the urine sample on Day 1 was negative for naphthalene. On Day 4, her laboratory parameters improved. Hb stabilised at 9.4 g/dL without further blood transfusion; total bilirubin had dropped from 77.6 to 38.5 µmol/L, with AST in the downward trend as well. Her renal function remained normal and alkaline diuresis was stopped. The urine was noted to be clear, and there was decreased cyanosis. The pulse oximeter began to register consistently > 95% by late afternoon that day.

At this time, blood glucose-6-phosphate dehydrogenase (G6PD) activity was confirmed present, and her Hb electrophoresis was suggestive of Hb-E alpha thalassaemia. By Day 5 of admission, her Hb level had stabilised at 9.8 g/dL with normalisation of leucocyte count and serum total bilirubin level. Renal function was preserved and MetHb was reduced to 1.8%. CVVH was discontinued and she was sent to general ward after five days in the ICU. Radioimaging tests for her abdominal pain were normal and her urine pregnancy test was negative. The pain resolved spontaneously. She stayed a total of ten days in the hospital. On discharge, her Hb was 10.3 g/dL and MetHb 1.1%, with no renal or neurological sequelae. Subsequently, she was lost to outpatient follow-up. Table I and Fig. 1 illustrate the progression of her biochemical parameters and the important interventions performed while she was admitted.

## DISCUSSION

Mothballs retailed for household use in Singapore may contain naphthalene or paradichlorobenzene,<sup>(4)</sup> of which the latter poses less harm if ingested. Camphor



**Fig. 1** Graph shows the haemoglobin (Hb) and methaemoglobin (MetHb) levels vs. day of admission. The use of methylene blue and blood transfusions resulted in the improvement in clinical and biochemical parameters. Continuous venovenous haemofiltration (CVVH) was introduced on Day 3 of admission.

mothballs are not freely available in Singapore. Bedside differentiation is important to the clinician because identifying a mothball containing paradichlorobenzene can often lead to outpatient management, saving both money and undue worry.<sup>(5)</sup> One method is to test the ability of the mothball to float in water and concentrated salt solution. A naphthalene mothball floats in saturated salt solution but sinks in water. If it sinks in both liquids, it is a paradichlorobenzene mothball. Camphor, in contrast, floats on water.<sup>(6)</sup> Radiography may also be helpful as paradichlorobenzene is radiopaque whereas naphthalene is not.<sup>(7)</sup>

Naphthalene is a bicyclic aromatic hydrocarbon with a molecular weight of 128 (C<sub>10</sub>H<sub>8</sub>). It is poorly soluble in water, and one mothball (depending on size) can contain between 0.5–5 g of naphthalene. The clinical consequences of naphthalene ingestion may include headache, vomiting, diarrhoea, abdominal pain, fever and altered mental status.<sup>(5)</sup> Oxidative stress from the hepatic metabolites of naphthalene causes haemolysis and methaemoglobinaemia. The presence of one should prompt the exclusion of the other. Laboratory studies have also demonstrated that naphthalene induces toxic manifestations by enhanced production of free oxygen radicals, resulting in lipid peroxidation and deoxyribonucleic acid damage.<sup>(8)</sup> Ascorbic acid was given to our patient to counteract this effect; it has also been used in one previously-described case<sup>(9)</sup> though its efficacy is questioned as it is a weak reducing agent.

Haemolysis occurs through either Hb (Heinz bodies formation) or cell membrane effects, particularly in patients with a low tolerance to oxidative stress (G6PD deficiency). Renal failure as a complication of naphthalene-induced haemolysis and haemoglobinuria

**Table I. Progression of biochemical parameters while the patient was admitted.**

Day of admission:	Day 1	Day 2	Day 3	Day 4	Day 5	Day 10
Haemoglobin (g/dL)	8.6	7.5	7.5	9.4	9.8	10.3
Methaemoglobin (%)	9.6	13	7.8	NA	1.8	1.1
Qualitative serum naphthalene	Positive	ND	Positive	ND	ND	ND
Urine colour	Brown	Brown	Brown	Clearing	Clear	NA

NA: not available; ND: not done

has been reported.<sup>(10)</sup> Haemolysis and haemoglobinuria are treated with IV hydration ensuring brisk urine output, urinary alkalinisation and packed RBC transfusion. Urinary alkalinisation and IV hydration with diuresis are aimed at minimising the deposition of Hb in kidney tubules. However, regular monitoring and correction of blood and urine pH as well as blood electrolytes need to be maintained.

Methaemoglobinaemia is caused by the oxidation of ferrous ( $\text{Fe}^{2+}$ ) to ferric ( $\text{Fe}^{3+}$ ) Hb. It renders the Hb incapable of carrying oxygen and shifts the oxyhaemoglobin curve to the left. Cyanosis is clinically detectable at >10% methHb in a patient with a Hb 15 g/dL (> 1.5 g/dL of methHb). However, the presence of anaemia could mask this clinical sign at the same methHb fraction. Pulse oximetry may become unreliable in the setting of methaemoglobinaemia, registering a false high in patients with severe methaemoglobinaemia and a false low in patients with mild methaemoglobinaemia.<sup>(11)</sup> Routine ABG of these patients measures serum  $\text{PO}_2$  (which is normal) and calculates a falsely normal oxygen saturation. A co-oximeter type of blood gas analyser is needed to directly measure the oxygen saturation and methHb levels. Clinical suspicion of methHb should be raised when there is cyanosis that does not respond to high-flow oxygen with no obvious cardiorespiratory causes, like right-to-left shunting.

Standard treatment includes the use of methylene blue and exchange transfusion. Methylene blue increases the rate of conversion of methHb to Hb by accepting an electron (in the presence of nicotinamide adenine dinucleotide phosphate [NADPH] and methHb reductase), to form leucomethylene blue, which can then donate this electron to reduce methHb.<sup>(12)</sup> It is important to note that methylene blue itself may induce haemolysis (through the development of Heinz bodies) and cause paradoxical methaemoglobinaemia, especially in G6PD deficient patients.<sup>(13)</sup> The use of NAC as a direct reducing agent in treating methaemoglobinaemia is still being investigated. It presents the potential benefit in G6PD deficiency because glutathione synthesis is not dependent on NADPH.<sup>(13)</sup> However, recent studies with NAC failed to

show enhanced reduction in human volunteers.<sup>(14,15)</sup> Other than the specific therapies described above, management of naphthalene toxicity is mainly supportive. If the patient presents early, decontamination procedures like the use of activated charcoal, gastric lavage and whole bowel irrigation should be considered.

Our patient demonstrated persistent haemolytic anaemia and methaemoglobinaemia up to five days post-ingestion. This is also shown in other cases of naphthalene ingestion where the haemolysis and methHb persisted more than a week.<sup>(10)</sup> No studies have quantified the rate and extent of naphthalene absorption in humans following ingestion. Extended urinary excretion has been observed following the ingestion, with metabolites still detectable in the urine 13 days post-ingestion.<sup>(16)</sup> The postmortem finding of one patient who swallowed 40 mothballs and died five days later revealed 25 remaining mothballs in the stomach.<sup>(3)</sup>

There is little in the literature on the use of extracorporeal elimination modalities to treat acute poisoning with naphthalene. One man with naphthalene poisoning had survived following haemodialysis.<sup>(17)</sup> Free naphthalene and its metabolites should cross the haemofilter readily, but naphthalene is poorly water-soluble, and its volume of distribution is not defined. The role of CRRT in the removal of excessive fluid overload, especially in haemodynamically-unstable patients, is well established. However, its role in poison elimination remains ill-defined.<sup>(18)</sup> Its use in lithium poisoning to reduce the rebound of lithium level post-haemodialysis has been reported.<sup>(19)</sup> This is mainly because CRRT can be used over 24 hours. The CRRT technique to enhance elimination was utilised in this case because of continued haemolysis despite full supportive care and blood transfusion. In the presence of delayed extended absorption of naphthalene from the gastrointestinal tract or sequestration of the poison in the body fats, it could provide ongoing removal of toxins, reducing the likelihood of rebound toxicity. The institution of CVVH coincided with clinical improvement in our patient. However, we could not confirm whether it made a real difference in the patient's recovery, and more studies

need to be done before it could be recommended as a modality of treatment for naphthalene poisoning.

In summary, naphthalene mothball ingestion can present with prolonged haemolytic anaemia and methaemoglobinaemia. Overdose by this poison is uncommon but can prove fatal, especially in patients who are G6PD deficient. The diagnostic challenge to clinicians attending to patients who present with pallor, jaundice and cyanosis that do not respond to oxygen therapy should include poisoning by oxidising agents like naphthalene. The early use of decontamination procedure as well as judicious use of antidotes (methylene blue) should be considered in the management of these patients, besides the standard supportive management, including blood transfusion and exchange transfusion. Enhanced elimination techniques like CRRT could be considered, but it still remains unproven, and hence cannot be routinely recommended.

## REFERENCES

1. Tay SY, Tai DY, Seow E, Wang YT. Patients admitted to an intensive care unit for poisoning. *Ann Acad Med Singapore* 1998; 27:347-52.
2. Gupta R, Singhal PC, Muthusethupathy MA, Malik AK, Chugh KS. Cerebral oedema and renal failure following naphthalene poisoning. *J Assoc Physicians India* 1979; 27:347-8.
3. Kurz JM. Naphthalene poisoning: critical care nursing techniques. *Dimens Crit Care Nurs* 1987; 6:264-70.
4. Lim HC. Mothballs: bringing safety issues out from the closet. *Singapore Med J* 2006; 47:1003.
5. Kuffner EK. Camphor and moth repellants. In: Goldfrank LR, Flomenbaum NE, Lewin NA, et al, eds. *Goldfrank's Toxicologic Emergencies*. 7th ed. New York: McGraw-Hill, 2002:1295-302.
6. Koyama K, Yamashita M, Ogura Y, et al. A simple test for mothball component differentiation using water and a saturated solution of table salt: its utilization for poison information service. *Vet Hum Toxicol* 1991; 33:425-7.
7. Woolf AD, Saperstein A, Zawin J, Cappock R, Sue YJ. Radiopacity of household deodorizers, air fresheners, and moth repellents. *J Toxicol Clin Toxicol* 1993; 31:415-28.
8. Bagchi M, Bagchi D, Balmoori J, Ye X, Stohs SJ. Naphthalene-induced oxidative stress and DNA damage in cultured macrophage J774A.1 cells. *Free Radic Biol Med* 1998; 25:137-43.
9. Trevisan A, Rossi di Schio M, Pieno M. Haemolytic anaemia after oral self-giving of naphthalene-containing oil. *J Appl Toxicol* 2001; 21:393-6.
10. Chugh KS, Singhal PC, Sharma BK, et al. Acute renal failure due to intravascular haemolysis in the North Indian patients. *Am J Med Sci* 1977; 274:139-46.
11. Mokhesi B, Leiken JB, Murray P, Corbridge TC. Adult toxicology in critical care: part I: general approach to the intoxicated patient. *Chest* 2003; 123:577-92.
12. Howland MA. Methylene blue. In: Goldfrank LR, Flomenbaum NE, Lewin NA, et al, eds. *Goldfrank's Toxicologic Emergencies*. 7th ed. New York: McGraw-Hill, 2002: 1450-1.
13. Wright RO, Lewander WJ, Woolf AD. Methemoglobinemia: etiology, pharmacology and clinical management. *Ann Emerg Med* 1999; 34:646-56.
14. Dotsch J, Demirakca S, Kratz M, et al. Comparison of methylene blue, riboflavin, and N-acetylcysteine for the reduction of nitric oxide-induced methemoglobinemia. *Crit Care Med* 2000; 28:958-61.
15. Tanen DA, LoVecchio F, Curry SC. Failure of intravenous N-acetylcysteine to reduce methemoglobin produced by sodium nitrite in human volunteers: A randomized controlled trial. *Ann Emerg Med* 2000; 35:369-73.
16. Mackell JV, Rieders F, Brieger H, Bauer EL. Acute hemolytic anemia due to ingestion of naphthalene mothballs. *Pediatrics* 1951; 7:722-8.
17. Agarwal SK, Tiwari SC, Dash SC. Spectrum of poisoning requiring haemodialysis in a tertiary care hospital in India. *Int J Artif Organs* 1993; 16:20-2.
18. Goodman JW, Goldfarb DS. The role of continuous renal replacement therapy in the treatment of poisoning. *Semin Dial* 2006; 19:402-7.
19. van Bommel EF, Kalmeijer MD, Ponsen HH. Treatment of life-threatening lithium toxicity with high-volume continuous venovenous hemofiltration. *Am J Nephrol* 2000; 20:408-11.