

Obturator hernia: diagnosis and treatment in the modern era

Mantoo S K, Mak K, Tan T J

ABSTRACT

Introduction: Obturator hernia is a rare variety of abdominal hernia that nonetheless is a significant cause of morbidity and mortality, especially in the elderly age group. This article aimed to review the diagnosis and management of obturator hernia by describing the anatomy, clinical presentation, predisposing factors, diagnostic modalities and management in the modern era.

Methods: We managed six cases of obturator hernia between 2003 and 2006. Five out of six cases were diagnosed by a preoperative computed tomography (CT) and the sixth case was diagnosed by ultrasonography. All except one were managed by an exploratory laparotomy and repair of the hernia, and one was treated with laparoscopic repair.

Results: Correct preoperative diagnosis was made in five out of five (100 percent) patients by clinical signs and CT of the abdomen and pelvis, and the sixth patient was operated on the basis of an ultrasonographical diagnosis and strong clinical suspicion.

Conclusion: We conclude that the rapid evaluation by CT of the abdomen and pelvis and surgical intervention are possible, thereby reducing the morbidity and mortality of patients with obturator hernia. An algorithm for the management of obturator hernia is proposed.

Keywords: abdominal hernia, obturator hernia, strangulated hernia

Singapore Med J 2009;50(9):866-870

INTRODUCTION

Obturator hernia is a rare variety of abdominal hernia that nonetheless is a significant cause of morbidity and mortality, especially in the elderly age group.⁽¹⁻³⁾ It occurs through the obturator foramen in the pelvis with no external lump. The incidence rates of obturator hernia vary

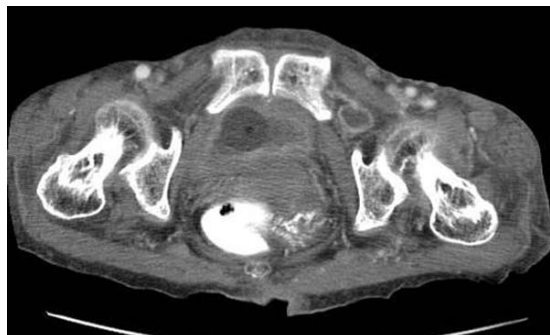


Fig. 1 Case 1. Axial CT image of the pelvis shows a left obturator hernia.

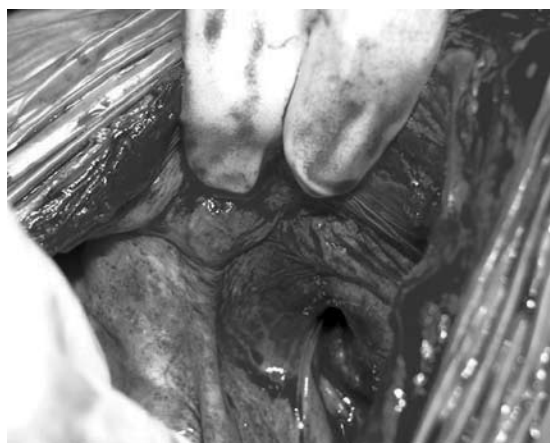


Fig. 2 Case 4. Intraoperative photograph shows the widened right obturator canal.

Table 1. Demographics of six patients with obturator hernia.

Patient characteristics	Mean (range)
Age (years)	88.8 (76–96)
Weight (kg)	33 (25–48)
Height (cm)	140 (134–144)
Body mass index (kg/m ²)	15.5 (13.5–19.5)
No. of deliveries	4.1 (1–7)

widely throughout the world. It accounts for 0.07%–1.0% of all hernias, and 0.2%–1.6% of all cases of mechanical obstruction of the small bowel. Asians have been shown to have the highest rates, while Western studies indicate a much lower incidence.⁽⁴⁾ Obturator hernia poses a diagnostic challenge as signs and symptoms are often nonspecific, making a preoperative diagnosis difficult.

Department of Surgery,
Alexandra Hospital,
378 Alexandra Road,
Singapore 159964

Mantoo SK, MS,
MMed, MRCS
Registrar

Mak K, MMed,
FRCS
Senior Consultant
and Head

Tan T J, MD
Consultant

Correspondence to:
Dr Surendra Kumar
Mantoo
Tel: (65) 9664 5411
Fax: (65) 6379 3540
Email: skmantoo@
yahoo.co.in

Table II. Clinical and surgical details of the six patients with obturator hernia.

Clinical characteristics	Case 1	Case 2	Case 3	Case 4	Case 5	Case 6
Age (years)/gender	96/F	89/F	76/F	90/F	93/F	78/F
Duration of symptoms (days)	4	6	3	4	3	2
Intestinal obstruction	Yes	Yes	Yes	Yes	Yes	No
Intermittent obstruction	Yes	No	Yes	No	No	Yes
Previous abdominal operation	No	No	No	No	No	No
Howship-Romberg sign	NA	NA	NA	Yes	Yes	No
Comorbidity	COPD, IHD	OA, DM, IHD	Nil	HT, DM	IHD	IHD
CT (abdomen & pelvis)	Yes	Yes	Yes	Yes	Yes	No
Preoperative diagnosis of obturator hernia	Yes	Yes	Yes	Yes	Yes	No
Side affected	Left	Right	Left	Right	Bilateral	Left
Stage of obturator hernia	III	II	III	III	I & II	II
Hernia content	SB	SB	SB	SB	SB	Nil
Operative approach	EL-lmi	EL-lmi	EL-lmi	EL-lmi	EL-lmi	Lap
Bowel resection	Yes	No	Yes	Yes	No	No
Repair type	Mesh	SC	Mesh	Mesh	SC	Mesh
Hospital stay (days)	36	24	6	10	44	8
Outcome	Survived	Survived	Survived	Survived	Survived	Survived
Follow-up (20 months)	Lost	Well	Well	Well	Lost	Well

NA: not applicable; COPD: chronic obstructive pulmonary disease; IHD: ischaemic heart disease; OA: osteoarthritis; DM: diabetes mellitus; HT: hypertension; EL-lmi: exploratory laparotomy – lower midline incision; Lap: laparoscopy; SB: small bowel; SC: suture closure

The mortality rate of obturator hernia is highest among all abdominal wall hernias (range 13%–40%). Six cases of obturator hernia were managed between 2003 and 2006 at this institution, and one of the cases was treated with laparoscopic repair. The three stages of obturator hernia formation were described by Gray et al.⁽⁵⁾ We have correlated these stages with the computed tomography (CT) findings, predicting the severity of the obstruction. A correct preoperative diagnosis was made in all the six cases. An algorithm for the management of obturator hernia is proposed.

METHODS

We managed six cases of obturator hernia from December 2003 to December 2006. These cases represented 0.06% of all hernias repaired in our institution during this period. Five of the six patients presented with signs and symptoms of intestinal obstruction to the emergency department. None had previous abdominal surgery. No external hernias on examination were noted. Howship-Romberg sign (HRS) was positive in two patients. CT of the abdomen and pelvis was done in five patients preoperatively. The sixth patient was operated electively with the preoperative diagnosis of femoral hernia made on ultrasonography; and on laparoscopy, an obturator hernia was confirmed and repaired with a mesh. We reviewed these cases and examined the clinical presentation, age, body weight, comorbidities, preoperative diagnosis, operative findings, complications and outcome in this retrospective review.

RESULTS

For Cases 1–5, the correct preoperative diagnosis was made in all five (100 percent) patients by clinical signs and CT of the abdomen and pelvis (Fig. 1). The patient characteristics are summarised in Table I. All five patients were operated via a lower vertical midline abdominal incision. The diagnosis of obturator hernia was confirmed in all cases (Fig. 2). The hernial sac in all the patients contained the small bowel. Three out of five operated patients required a small bowel resection. Case 5 was found to have a bilateral obturator hernia. The stage of hernia was verified and correlated with the CT findings. A simple closure of the obturator canal with prolene no. 1 was done in two patients (Stage II hernias) and a prolene mesh (15 cm × 12 cm) was used in three patients (Stage III hernias). The mesh was anchored with nonabsorbable sutures. The mean hospital stay was 24 (range 6–44) days. There was no mortality. Postoperative complications were pneumonia (n = 1), and wound infection (n = 2). No recurrence was noted in the three patients who were followed-up at 20 months. The clinical and surgical details of the patients are summarised in Table II.

Case 6 was a 78-year-old woman who was diagnosed electively by clinical examination and ultrasonography to have a left femoral hernia. A laparoscopic transabdominal preperitoneal was chosen to repair this with the view to check for any obstructed bowel. An obturator hernia was confirmed by exposing the widened obturator canal, and was repaired using a 15 cm × 11 cm prolene mesh

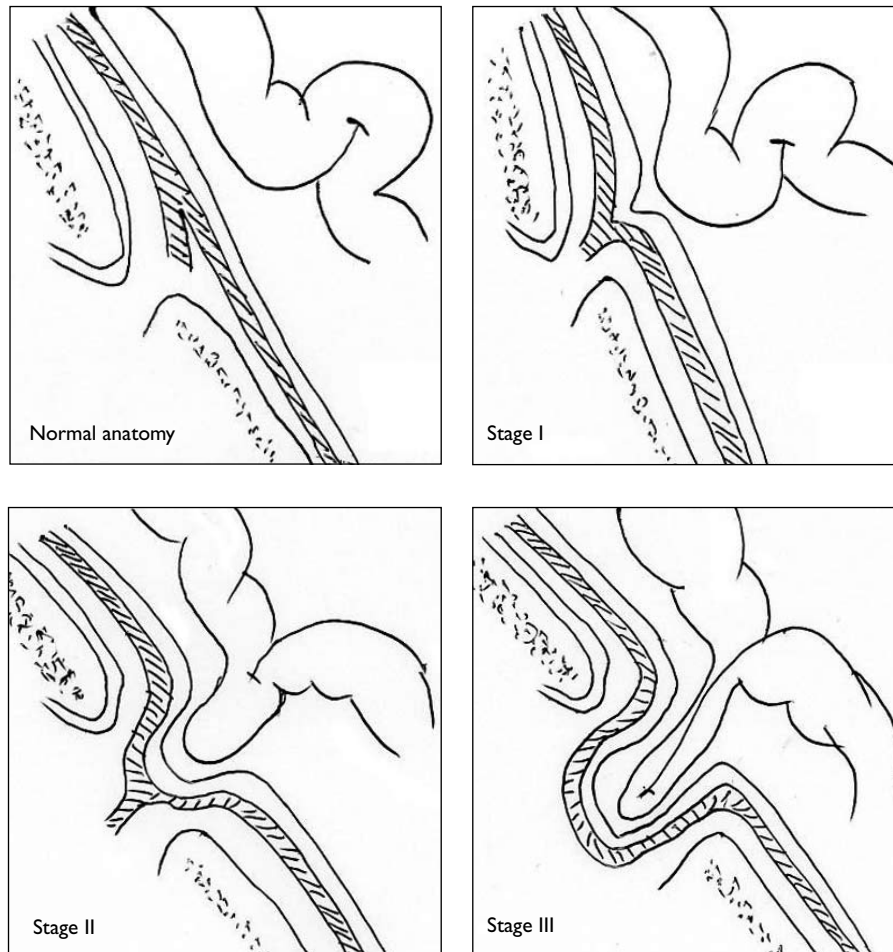


Fig. 3 Diagram shows the stages of obturator hernia.⁽⁵⁾

after reducing the viable small bowel. The patient had an uneventful recovery.

DISCUSSION

Arnaud de Ronsil in 1724 first described the obturator hernia, and Henry Obre first successfully repaired it in 1851.⁽⁶⁾ Obturator hernia occurs through the obturator canal, which is 2–3 cm long and 1 cm wide, and contains the obturator nerve and vessels. It is bounded superiorly and laterally by the pubic bone and inferiorly by the obturator membrane. Corpus adiposum is a cushion for the obturator nerve. Obturator hernia is nine times more common in females due to their wider pelvis, more triangular obturator canal opening and greater transverse diameter. It occurs most frequently in emaciated patients aged between 70 and 90 years, and hence its nickname, “little old lady’s hernia”.⁽⁷⁾ The loss of protective preperitoneal fat and lymphatic tissue (corpus adiposum) around the obturator vessels and nerves facilitates the formation of hernia.

The clinical presentation is vague with symptoms of bowel obstruction—dull, crampy abdominal pain,

nausea and vomiting—and it is present in more than 80% of patients. Obstruction is usually partial due to a high frequency (41%–100%) of Richter’s herniation of the small bowel into the obturator canal. Obstruction can be acute or intermittent, which is an important clue to diagnosis (Cases 1, 3 and 6). An external hernia is uncommon. Gray et al described three anatomical stages of the formation of obturator hernia. The first stage begins with the entrance of preperitoneal fat into the pelvic orifice of the obturator canal, forming a pilot fat plug. During the second stage, a peritoneal dimple forms and progresses to form a peritoneal sac. During the third stage, symptoms are produced by herniation of the viscera into this sac⁽⁵⁾ (Fig. 3).

Clinical signs are seldom thought of and hence seldom sought.⁽⁸⁾ Most of the signs are due to compression of the obturator nerve by the hernia sac and its contents. The common signs which can be elicited are obturator neuralgia which presents as either hyper- or hypoaesthesia from the inguinal crease to the anteromedial aspect of the thigh. The HRS is characterised by pain in the medial thigh, and less often in the hip.⁽⁸⁾ Flexion of the thigh usually

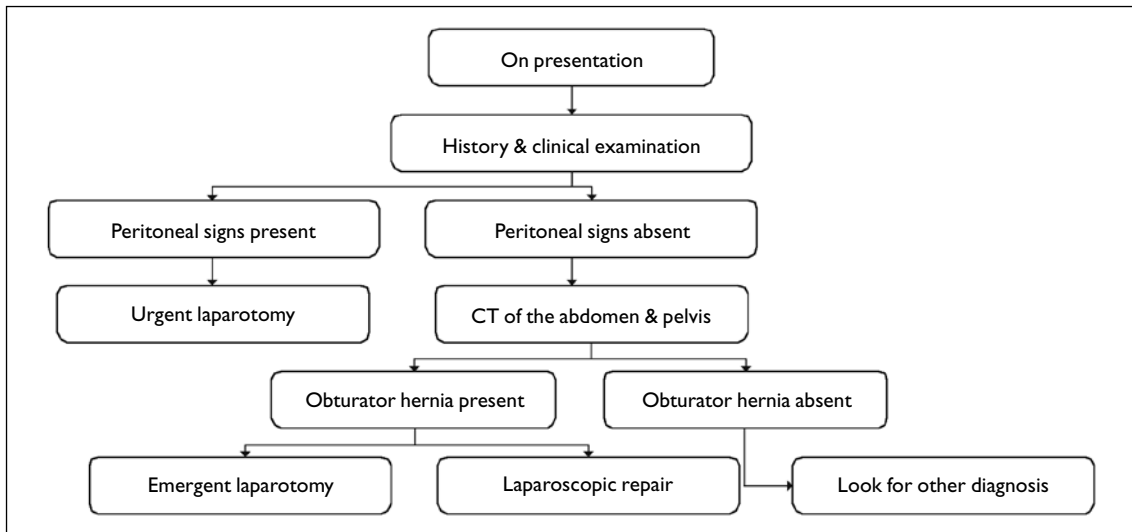


Fig. 4 A simple algorithm for the management of obturator hernia.

relieves this pain; extension, adduction or medial rotation exacerbates it. This sign is present in 15%–50% of cases (Cases 4 and 5), and based on it, a correct preoperative diagnosis can be made in only 20%–38% of cases. It is often overlooked or misinterpreted due to associated disorders of the hip like arthritis. The Hannington-Kiff sign refers to an absent adductor reflex in the thigh.⁽⁹⁾ It is more specific than HRS but less known. Perrectal and per vaginal examination can reveal a palpable mass and adds to the clinical suspicion of obturator hernia.

Several imaging modalities have been described to diagnose obturator hernia including plain radiographs of the abdomen, ultrasonography, and barium enema, but CT of the abdomen and pelvis is most relevant. Recent series have reported that definite and early diagnosis of the obturator hernia can be made in 100% of cases with CT of the abdomen and pelvis.^(10,11) It is minimally invasive, readily available and requires a short time. It is especially useful in the initial period when the patient has non-specific symptoms and vague clinical signs. However, when there are clinical signs of peritonitis, laparotomy should not be delayed. There is often a delay in the diagnosis and surgical intervention of the obturator hernia because of a hesitation to operate early due to the vague symptoms and history, delayed presentation, advanced age of patients, presence of comorbidities and debilitating conditions. In our series, the preoperative CT led to a definitive diagnosis in five patients leading to immediate operative intervention.

Despite its rarity, a variety of operative approaches have been described to repair the obturator hernia. These include the abdominal approach (Cases 1–5), retropublic approach, obturator approach, inguinal approach and

more recently, the laparoscopic approach (Case 6).⁽¹²⁾ The abdominal approach via a low midline incision is most commonly favoured, as the advantages of this approach include establishing a diagnosis, avoidance of obturator vessels, better exposure of the obturator ring, and facilitation of bowel resection, if necessary. Many authors prefer a simple closure of the hernial defect with one or more interrupted sutures as it leads to an acceptable recurrence rate of less than 10% (Cases 1 & 5). The defect can be closed by synthetic mesh (Cases 2–4 & 6), although a myriad of things have been used in the past, such as costal cartilage, innermost fibres of pectineus muscle, rolled-up tantalum gauze, osteoperiosteal flap from the pubic bone, free omentum and uterine fundus or round ligament.

The laparoscopic approach is an alternative to diagnose, reduce and repair an obturator hernia in selected cases. Both transabdominal and extraperitoneal approaches have been described.^(13,14) This approach is minimally invasive and provides some benefits for these high-risk patients like less postoperative pain, less ileus, fewer pulmonary complications and a shorter hospital stay. Whatever the approach, the emphasis should be on rapid evaluation, adequate resuscitation and early operative intervention to reduce the morbidity and mortality. Based on our experience during the management of our cases, we propose an algorithm for the management of obturator hernias (Fig. 4).

In conclusion, obturator hernia is a rare entity. This occurs through the obturator foramen and usually afflicts elderly, emaciated female patients. It is occult on external examination. Clinical signs are seldom thought of and hence seldom sought. A high clinical suspicion

is required and early diagnosis with a CT is possible. Early surgery and not prolonged preoperative evaluation is the key to prevent morbidity and mortality. Recently, the laparoscopic approach has been described as an alternative to diagnose, reduce and repair an obturator hernia in selected cases.

REFERENCES

1. Yip AW, AhChong AK, Lam KH. Obturator hernia: a continuing diagnostic challenge. *Surgery* 1993; 113:266-9.
2. Ziegler DW, Rhoads JE Jr. Obturator hernia needs a laparotomy, not a diagnosis. *Am J Surg* 1995; 170:67-8.
3. Green BT. Strangulated obturator hernia: still deadly. *South Med J* 2001; 94:81-3.
4. Lo CY, Lorentz TG, Lau PW. Obturator hernia presenting as small bowel obstruction. *Am J Surg* 1994; 167:396-8.
5. Gray SW, Skandalakis JE, Soria RE, Rowe JS Jr. Strangulated obturator hernia. *Surgery* 1974; 75:20-7.
6. Hsu CH, Wang CC, Jeng LB, Chen MF. Obturator hernia: a report of eight cases. *Am Surg* 1993; 59:709-11.
7. Bjork KJ, Mucha P Jr, Cahill DR. Obturator hernia. *Surg Gynecol Obstet* 1988; 167:217-22.
8. Chung CC, Mok CO, Kwong KH, et al. Obturator hernia revisited: a review of 12 cases in 7 years. *J R Coll Surg Edinb* 1997; 42:82-4.
9. Hannington-Kiff JG. Absent thigh adductor reflex in obturator hernia. *Lancet* 1980; 1:180.
10. Yokoyama Y, Yamaguchi A, Isogai M, Hori A, Kaneoka Y. Thirty-six cases of obturator hernia: does computed tomography contribute to postoperative outcome? *World J Surg* 1999; 23:214-6, discussion 217.
11. Dundamadappa SK, Tsou IY, Goh JS. Clinics in diagnostic imaging (107). *Singapore Med J* 2006; 47:88-94.
12. Lobo DN, Clarke DJ, Barlow AP. Obturator hernia: a new technique for repair. *J R Coll Surg Edinb* 1998; 43:33-4.
13. Moreno-Egea A, la Calle MC, Torralba-Martínez JA. Obturator hernia as a cause of chronic pain after inguinal hernioplasty: elective management using tomography and ambulatory total extraperitoneal laparoscopy. *Surg Laparosc Endosc Percutan Tech* 2006; 16:54-7.
14. Wu JM, Lin HF, Chen KH, Tseng LM, Huang SH. Laparoscopic preperitoneal mesh repair of incarcerated obturator hernia and contralateral direct inguinal hernia. *J Laparoendosc Adv Surg Tech A* 2006; 16:616-9.