

Management of postoperative chyloretroperitoneum in adults

Qi J, Gu Z Q, Chen F, Zhang L, Chen J H

ABSTRACT

Retroperitoneal chylous effusion after urological surgery is a rare and serious complication. Failure in treatment may result in cachexia, threatening the life of the patient. We present the treatment of two cases of postoperative chyloretroperitoneum with the use of somatostatin, octreotide and total parenteral nutrition. In Case 1, an 87-year-old man, a retroperitoneal lymphatic fistula occurred four days after the resection of the left kidney due to carcinoma, whereas in Case 2, a 56-year-old man, a continuous lymph fistula from the renal fossa occurred one month after resection of the right adrenal pheochromocytoma. Case 1 was treated with intravenous administration of somatostatin, and in Case 2, treatment consisted of subcutaneous administration of octreotide, in combination with total parenteral nutrition and other symptomatic therapies. In both cases, lymph exudation was terminated in about two weeks, and the patients recovered. Somatostatin therapy and total parenteral nutrition can effectively treat chyloretroperitoneum.

Keywords: chylous effusion, chyloretroperitoneum, octreotide, postoperative chyloretroperitoneum, somatostatin, total parenteral nutrition

Singapore Med J 2009;50(9):e338-e341

INTRODUCTION

Retroperitoneal chylous effusion caused by surgical damage to the cisterna chyli or the retroperitoneal lymphatic trunk is a rare complication of urosurgery. The complication is difficult to treat, and retardation in the treatment may lead to profound cachexia due to the rapid loss of fluid, plasma proteins, fats and lymphocytes. Because of the rarity, no guideline for treatment exists; hence, the reporting of individual experiences is useful for improving knowledge of the condition. This article reports the successful treatment with somatostatin, octreotide and total parenteral nutrition in two cases of chyloretroperitoneum after urosurgery. The principles of management were discussed, and the clinical features of

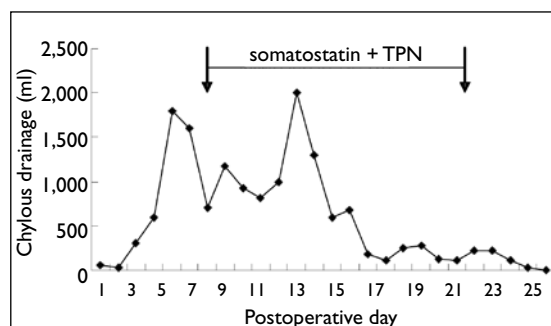


Fig. 1 Graph shows the efficacy of combined somatostatin and total parenteral nutrition (TPN).

chyloretroperitoneum as a complication of retroperitoneal surgery were reviewed.

CASE REPORTS

Case 1

An 87-year-old male patient had a 3 cm × 5 cm tumour in the left kidney, with clinical staging being cT1N0M0. Radical resection of the tumour and clearance of the para-aortic lymph nodes were performed. Postoperative pathology suggested clear cell carcinoma of the left kidney, and the lymph nodes were negative. At Day 3, the drainage from the left renal fossa increased to 300 ml, and at Day 4, to 600 ml, when the patient began eating small amounts of liquid food. The appearance of the drainage was milky. The chyle test was positive, and bacterial culture was negative. The patient was diagnosed to have retroperitoneal chylous effusions. A low-fat diet and sufficient drainage were prescribed. At Day 7 postoperation, the condition was complicated by massive haemorrhage of the stomach, and an emergency gastroendoscopic haemostasis was performed. Fasting, total parenteral nutrition and anti-acid treatment were prescribed, and intravenous (IV) administration of somatostatin at a dose of 6 mg/24 hours via an infusion pump was started. Due to the chylous effusion and bleeding, the patient developed hypoproteinaemia and oedema of the lower extremities. Liver function test showed total protein 53 g/L, albumin 26 g/L and albumin/globulin (A/G) ratio 0.96. IV administration of 20% human albumin, blood transfusion and plasma replacement were performed, and dihydrochlorothiazide was used. Under the treatment, the chylous effusion

Department of Urology, Xinhua Hospital, School of Medicine, Shanghai Jiaotong University, Shanghai 200092, China

Qi J, MD
Director and Senior Consultant

Gu ZQ, MD
Associate Professor and Consultant

Chen F, MD
Professor and Senior Consultant

Zhang L, MD
Associate Professor and Consultant

Chen JH, MD
Associate Professor and Senior Consultant

Correspondence to:
Dr Zheng-Qin Gu
Tel: (86) 21 6579 0000 ext 7805
Fax: (86) 21 6579 5173
Email: docguzq@gmail.com

Table I. Postoperative chyloretroperitoneum after surgery.

Study	Age (years)/ gender	Diagnosis	Primary surgery	Interval between chyloretroperitoneum (day)	Treatment of chyloretroperitoneum	Outcome
Shen et al ⁽⁶⁾	22/M	Poliomyelitis	Anterior spinal arthrodesis	3	Low fat diet 23 days, drainage	Complete recovery
Nagai et al ⁽⁷⁾	42/M	Spinal canal stenosis	Lumbar decompression and fusion	2	MCT 8 days, TPN 20 days, drainage	NED 11 years
	29/M	Thoracolumbar kyphosis	Thoracolumbar decompression and fusion	4	Low-fat diet 10 days, drainage	NED 2 years 2 months
Bachmann et al ⁽⁴⁾	59/F	Donor	L retroperitoneoscopic living donor nephrectomy	–	Short-, medium-chain fatty acids, full parenteral therapy, somatostatin, drainage	Complete recovery
Negoro et al ⁽⁵⁾	71/M	L renal pelvis carcinoma	Retroperitoneoscopic nephroureterectomy	13	TPN, octreotide, sclerotherapy, drainage	NED 5 months
	68/M	L low ureter carcinoma	Retroperitoneoscopic nephroureterectomy	2	Low fat diet, sclerotherapy, octreotide, drainage	NED 29 months
Su and Chen ⁽⁸⁾	49/M	Hepatocellular carcinoma with L3 spinal metastasis and radiculopathy	L3 tumour decompression	1	Tamponade leakage ½ day	Complete recovery
Upadhyaya et al ⁽⁹⁾	56/F	Scoliotic curvature	Anterior spinal deformity correction	9	TPN, drainage via peritoneal window	NED 2 years
Qi et al (present case)	87/M	L kidney carcinoma	Radical nephrectomy lymphadenectomy	4	TPN and somatostatin 2 weeks drainage	NED 19 months
	56/M	R adrenal pheochromocytoma	Resection of pheochromocytoma	–	TPN and octreotide 2 weeks drainage	NED 11 months

NED: no evidence of disease; MCT: medium chain triglyceride; TPN: total parenteral nutrition

became “clear” and not milky in the first few days, and the drainage decreased stepwise from 2,000 ml to 180 ml at Day 16 (Fig. 1). At Day 26, the patient was well and discharged from the hospital. Ultrasonography (US) did not show a recurrence of the lymphatic fistula during the 19-month follow-up.

Case 2

A 56-year-old male patient underwent tumour resection because of the rupture of a right adrenal tumour complicated by haemorrhagic shock. Postoperative pathology revealed a right adrenal pheochromocytoma. One month after the operation, the patient complained of pain in his upper back. A major retroperitoneal fluid accumulation was demonstrated ultrasonographically. Percutaneous puncture revealed chylous effusion. The drainage was serous, ≥ 200 ml/day. The patient was transferred to this hospital, where computed tomography showed effusion in the right adrenal area, right kidney and gallbladder fossa. Positive chyle test of the drainage from the renal fossa was confirmed. His liver function test was total protein 50 g/L, albumin 24 g/L and A/G ratio 0.92. The patient was treated with octreotide at a dose of 0.1 mg given subcutaneously three times a day, together with total parenteral nutrition for two weeks.

The amount of drainage decreased from 200 ml to 10 ml, and the patient was well after three weeks. Restoration of food intake did not elicit drainage from the right renal fossa. There was no recurrence during the 11-month follow-up period, and US indicated no lymphatic fistula.

DISCUSSION

Lymphatic fistula occurs when the lymph passage is obstructed or ruptured. In the retroperitoneal cavity lies the cisterna chyli and lymphatic trunk. The cisterna resides at the level of the renal pedicles and is involved with the primary area of resection of the retroperitoneal nodes, which are occasionally damaged, causing chylous effusions (chyloperitoneum and chyloretroperitoneum). Chyloperitoneum (chylous ascites) may occur during lymph node clearance in the resection of neoplasm of the testis,⁽¹⁾ in renal cancer⁽²⁾ and donor kidney resection.⁽³⁾ Chyloretroperitoneum as a complication of urosurgery is rarely reported; it may occur during retroperitoneoscopic donor nephrectomy and ureterectomy.^(4,5) Postoperative chyloretroperitoneum is also an uncommon complication following spinal surgery⁽⁶⁻⁹⁾ (Table I). However, as the rich lymphatic network may reroute the disrupted lymphatic flow, chylous effusion usually heals spontaneously and

seldom becomes clinically evident.

The treatment of severe postoperative chylous effusions is a clinical challenge because the complication may lead to a loss of protein and lymphocytes, resulting in serious malnutrition, hypoproteinaemia and immunodeficiency, threatening the life of the patient. Various management modalities may be successful for treating chylous ascites.⁽¹⁰⁾ Due to the rarity of chyloretroperitoneum, no guideline of treatment exists. In our experience, the chyloretroperitoneum resolved after conservative treatment, which included an effective drainage, diet control, diuretics, total parenteral nutrition, and administration of somatostatin or its analogues. We presented two cases of rapid resolution of chylous effusions after urosurgery, with two weeks of treatment using somatostatin and total parenteral nutrition.

Using somatostatin in chylous effusions is a novel application of this gut hormone, and has received attention only in the last few years, due to its effectiveness and few side-effects. Ulibarri et al first reported their experience with continuous IV high-dose somatostatin for the closure of postoperative lymphorrhagia in 1990.⁽¹¹⁾ The mechanism by which somatostatin stops chylous effusions is not fully understood. It was shown to decrease the intestinal absorption of fats, decrease triglyceride concentration in the thoracic duct and attenuate lymph flow in the major lymphatic channels.⁽¹²⁾ It may be related to the inhibitory effects of somatostatin on lymphatic duct movement, intestinal peristalsis, gastric, pancreatic and intestinal secretion, and intestinal absorption via the specific receptors.⁽¹¹⁾ Other studies reported that somatostatin also reduces portal pressure and visceral blood flow.⁽¹³⁾ Case 1 showed that somatostatin was effective, even in a critical situation when the patient had both chylous effusions and massive stomach bleeding, leading to severe hypoproteinaemia. In Case 2, which had a protracted course of postoperative chyloretroperitoneum, octreotide was used, and similar effects were observed. We recommend giving priority to octreotide as the administration of somatostatin requires continued IV instillation for several days, due to the rapid degradation of somatostatin in the plasma. Additionally, somatostatin interfered with blood glucose regulation.⁽¹²⁾ Satisfactory results were also achieved by others. Bachmann et al suggested an application of 0.1 mg somatostatin tds, which is recommended to prevent severe chyloretroperitoneum (high output fistula greater than 1,000 ml/24 hours).⁽⁴⁾ Others reported that octreotide therapy was effective to resolve chylous effusion after retroperitoneoscopic nephroureterectomy.⁽⁵⁾

Diet control includes using a low-fat or high-protein diet and total parenteral nutrition to reduce the formation of chyle from the intestine. Total parenteral nutrition ensures nutritional and caloric energy supply to the body and provides the necessary conditions for tissue repair and lymphatic healing. Total parenteral nutrition effectively decreases the production and flow of the lymph by allowing the bowel to rest. Fasting, together with total parenteral nutrition can decrease the lymph flow in thoracic duct dramatically from 220 ml/(kg·h) to 1 ml/(kg·h),⁽¹⁴⁾ thus they are very essential for the nonoperative management of chylous fistula. In both cases, the patients were fasted and put on total parenteral nutrition. After two weeks of therapy, management by total parenteral nutrition with somatostatin resulted in a resolution in both our cases. Parenteral lipids are phospholipids delivered directly into the blood stream, and as a result, do not pass through the lymph system as chyle. Therefore, lipids are not contraindicated in patients with chyle leaks. Total parenteral nutrition containing lipids may lead to treatment failure with octreotide.⁽¹⁵⁾ In our case, octreotide did work with total parenteral nutrition containing lipids, and rapidly decreased chylous effusions. Total parenteral nutrition would be effective to control the chylous complication when the volume of chylous discharge is high.⁽⁵⁾ Exactly when total parenteral nutrition is introduced depends on the volume of leak as well as the patient's nutritional status. It is a stepwise approach when enteral dietary manipulation fails and refractory chylous effusion occurs.

According to the English literature found in MEDLINE, there have only been eight cases of postoperative chyloretroperitoneum reported in adults.^(4,9) Five of these adults had spinal surgery,^(6,9) one case occurred during retroperitoneoscopic donor nephrectomy and the other two cases had retroperitoneoscopic ureterectomy.^(4,5) The interval between surgery and the clinical recognition of chyloretroperitoneum in these patients varied from one to 13 days. Among the adults with postoperative chyloretroperitoneum, four of eight patients (reviewed in Table I) improved with total parenteral nutrition; three of eight patients improved with a low-fat diet; one case combined somatostatin with total parenteral nutrition; and the other two cases were treated with sclerotherapy, octreotide, as well as total parenteral nutrition and a low-fat diet. Our patients' chyloretroperitoneum improved rapidly with drainage, two weeks of total parenteral nutrition, and somatostatin or octreotide.

In conclusion, somatostatin or octreotide in combination with total parenteral nutrition appear to be

an effective method of treating chyloretroperitoneum. Somatostatin therapy with total parenteral nutrition should be attempted in the course of the treatment of chylous effusions, before any invasive treatments are taken. The management of chyloretroperitoneum should be individualised and tailored according to the severity of the lymphatic effusions and its consequences. Further studies of multicentre clinical trials involving more patients are suggested, to compare the efficacy between this regimen and the others.

REFERENCES

1. Baniel J, Foster RS, Rowland RG, Bihrlle R, Donohue JP. Management of chylous ascites after retroperitoneal lymph node dissection for testicular cancer. *J Urol* 1993; 150:1422-4.
2. Leibovitch I, Mor Y, Golomb J, Ramon J. Chylous ascites after radical nephrectomy and inferior vena cava thrombectomy. Successful conservative management with somatostatin analogue. *Eur Urol* 2002; 41:220-2.
3. Shafizadeh SF, Daily PP, Baliga P, et al. Chylous ascites secondary to laparoscopic donor nephrectomy. *Urology* 2002; 60:345.
4. Bachmann A, Ruzsat R, Dickenmann M, et al. Chyloretroperitoneum with secondary chylothorax after retroperitoneoscopic donor nephrectomy. *Urology* 2005; 66:881.
5. Negoro H, Oka H, Kawakita M. Two cases of chyloretroperitoneum following retroperitoneoscopic nephroureterectomy. *Int J Urol* 2006; 13:487-9.
6. Shen YS, Cheung CY, Nilsen PT. Chylous leakage after arthrodesis using the anterior approach to the spine. Report of two cases. *J Bone Joint Surg Am* 1989; 71:1250-1.
7. Nagai H, Shimizu K, Shikata J, et al. Chylous leakage after circumferential thoracolumbar fusion for correction of kyphosis resulting from fracture. Report of three cases. *Spine* 1997; 22:2766-9.
8. Su IC, Chen CM. Spontaneous healing of retroperitoneal chylous leakage following anterior lumbar spinal surgery: a case report and literature review. *Eur Spine J* 2007; 16:332-7.
9. Upadhyaya CD, Park P, La Marca F. Chyloretroperitoneum following anterior spinal deformity correction. Case report. *J Neurosurg Spine* 2007; 7:562-5.
10. Leibovitch I, Mor Y, Golomb J, Ramon J. The diagnosis and management of postoperative chylous ascites. *J Urol* 2002; 167:449-57.
11. Ulibarri JI, Sanz Y, Fuentes C, et al. Reduction of lymphorrhagia from ruptured thoracic duct by somatostatin. *Lancet* 1990; 336:258.
12. Collard JM, Laterre PF, Boemer F, Reynaert M, Ponlot R. Conservative treatment of postsurgical lymphatic leaks with somatostatin-14. *Chest* 2000; 117:902-5.
13. Bhatia C, Pratap U, Slavik Z. Octreotide therapy: a new horizon in treatment of iatrogenic chyloperitoneum. *Arch Dis Child* 2001; 85:234-5.
14. Aalami OO, Allen DB, Organ CH Jr. Chylous ascites: A collective review. *Surgery* 2000; 128:761-78.
15. Mincher L, Evans J, Jenner MW, Varney VA. The successful treatment of chylous effusions in malignant disease with octreotide. *Clin Oncol (R Coll Radiol)* 2005; 17:118-21.