

CME Article

Breast calcifications: which are malignant?

Muttarak M, Kongmebhol P, Sukhamwang N

ABSTRACT

Most calcifications depicted on mammograms are benign. However, calcifications are important because they can be the first and earliest sign of malignancy. For detection and analysis of microcalcifications, high-quality images and magnification views are required. The American College of Radiology (ACR) Breast Imaging Reporting and Data System (BI-RADS) classifies calcifications on mammograms into three categories: typical benign, intermediate concern and higher probability of malignancy, according to types and distribution of calcifications. Benign calcifications are typically larger, coarser, round with smooth margins and have a scattered or diffuse distribution. Malignant calcifications are typically grouped or clustered, pleomorphic, fine and with linear branching. It is important for radiologists to detect, evaluate, classify and provide appropriate recommendations for calcifications perceived on mammograms to provide proper management.

Keywords: breast cancer, Breast imaging Reporting and Data System (BI-RADS), calcifications, mammography

Singapore Med J 2009;50(9):907-914

INTRODUCTION

Most calcifications depicted on mammograms are benign. However, 90% of nonpalpable ductal carcinoma *in situ* (DCIS), and 20% of minimal cancer (infiltrating carcinoma < 0.5 cm and all DCIS) were diagnosed on the basis of microcalcifications alone.⁽¹⁾ A high-quality image and magnification view are required for detection and analysis of microcalcifications. The American College of Radiology (ACR) Breast Imaging Reporting and Data System (BI-RADS) classifies calcifications on mammograms into three categories: typical benign, intermediate concern, and higher probability of malignancy, according to the types and distribution of calcifications.⁽²⁾ Benign calcifications are typically larger, coarser and round with smooth margins, while malignant calcifications are usually smaller and are often called microcalcifications. These microcalcifications are often harder to perceive and usually require a magnification view and magnifying glass to be seen clearly. Distribution of calcifications can


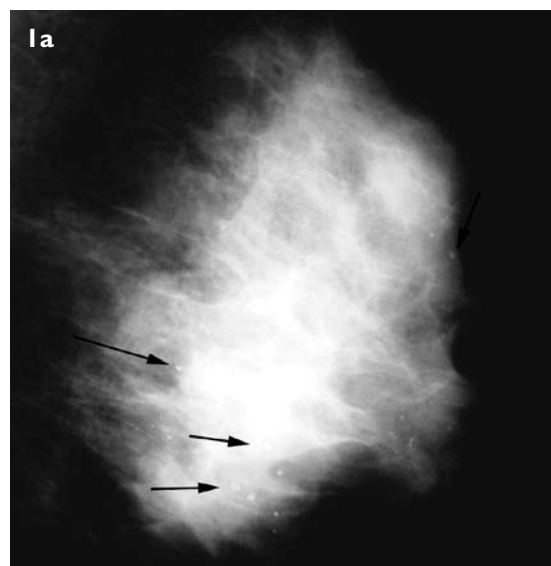


Fig. 1 Skin calcifications. (a) Left mediolateral oblique mammogram shows scattered, round, radiolucent-centred calcifications (arrows). (b) A tangential view shows multiple round calcifications in the skin.

be described as grouped or clustered, linear, segmental, regional, and diffuse or scattered. Benign calcifications tend to be regional, with a diffuse or scattered distribution and are often bilateral, even if asymmetric. Grouped or clustered, linear and segmental distributions are considered important as the likelihood of malignancy is increased. It is important for radiologists to detect, evaluate, classify and provide appropriate recommendations for calcifications perceived on mammograms, in order to provide proper management.

TYPICAL BENIGN CALCIFICATIONS

The first step in evaluating breast calcifications is to identify those that have a typical benign appearance, because they do not need further investigation or close follow-up. These typical benign calcifications include: skin

Department of
Radiology,
Chiang Mai
University,
110 Intavaroros
Road,
Chiang Mai 50200,
Thailand

Muttarak M, MD
Professor

Kongmebhol P, MD
Instructor

Department of
Pathology

Sukhamwang N, MD
Instructor

Correspondence to:
Prof Malai Muttarak
Tel: (66) 5394 5450
Fax: (66) 5394 6136
Email: mmuttara@
mail.med.cmu.ac.th

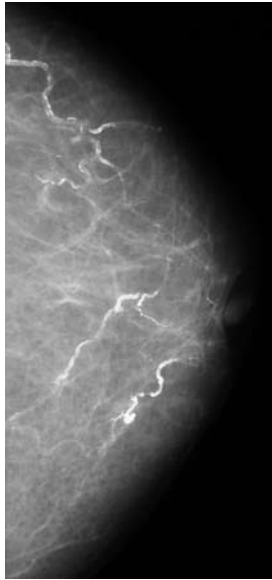


Fig. 2 Left craniocaudal mammogram shows typical parallel lines or railroad track calcifications along arterial walls.

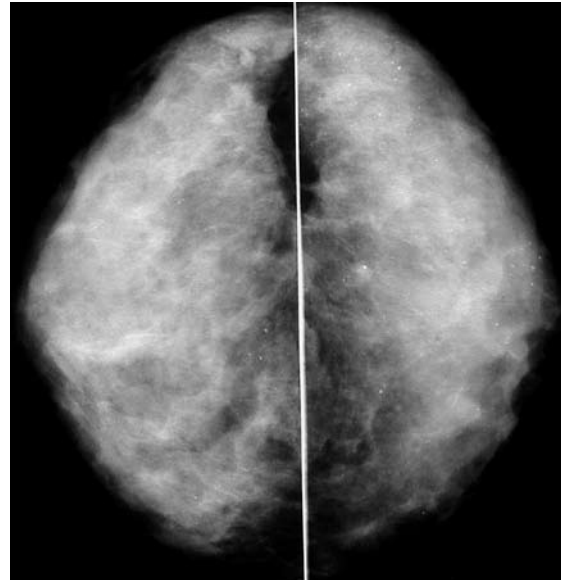


Fig. 5 Bilateral craniocaudal mammograms show scattered, round calcifications in both breasts.

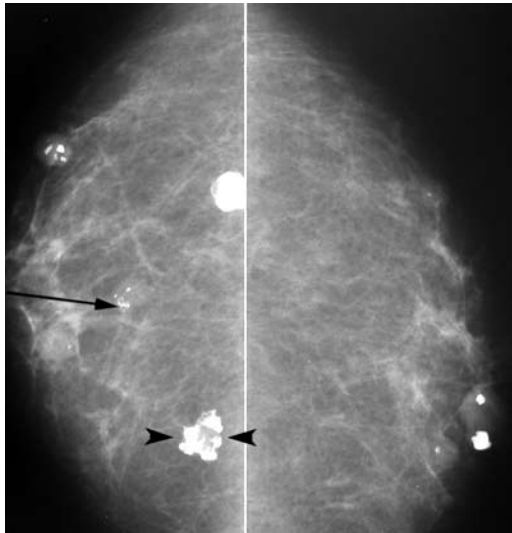


Fig. 3 Bilateral craniocaudal mammograms show calcified degenerating fibroadenoma in varying stages, including early peripheral calcifications (arrow) and late popcorn-like calcification (arrowheads) without the soft tissue component.

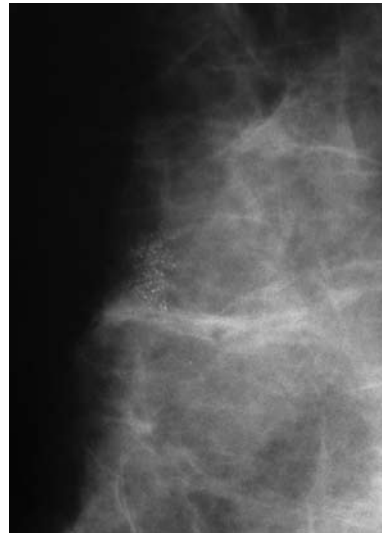


Fig. 6 Spot magnification view shows a group of punctate calcifications which proved to be a fibrocystic change.

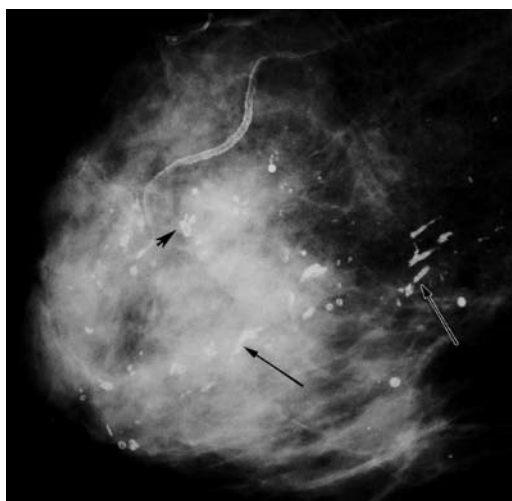

Fig. 4 Right mediolateral oblique mammogram shows secretory calcifications, both rod-like calcifications (arrows) and hollow cylinders (arrowhead). Vascular and rim calcifications are also seen.

or dermal, vascular, coarse or popcorn-like, large rod-like, round, lucent-centred, eggshell or rim, milk of calcium, suture, and dystrophic calcifications. Skin or dermal calcifications often occur in the sebaceous glands, in the inferior and medial aspect of the breasts. They usually appear as spherical or polygonal with a lucent centre, and can be clustered or diffuse with a regional distribution (Fig. 1a). Calcifications may be projected peripherally on one or more mammographic views, or they may appear to be within the breast parenchyma. A tangential view can be used to confirm calcifications within the dermis (Fig. 1b).

Vascular calcifications identified on mammograms are atherosclerotic, arterial calcifications. They are typically seen as two parallel lines or have a railroad track appearance (Fig. 2). These calcifications often occur in postmenopausal women with atherosclerotic

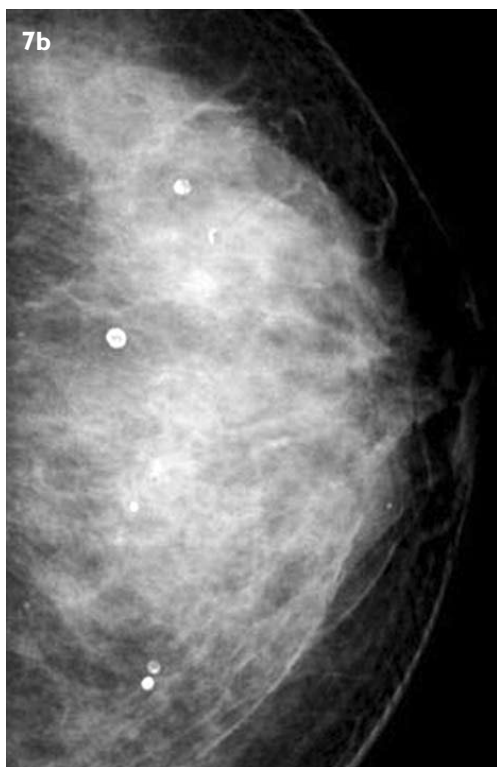
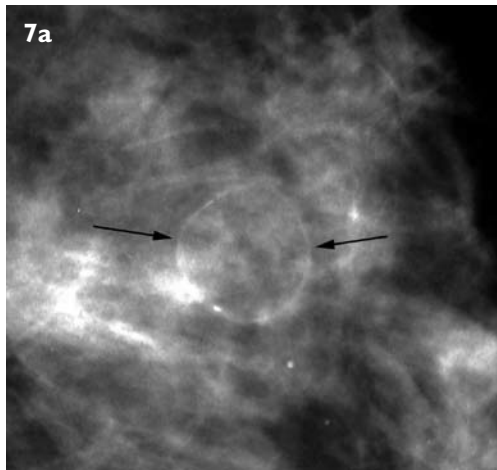


Fig. 7 (a) and (b) Mammograms of different patients show eggshell or rim calcifications of calcified lipid cysts.

heart disease and may be related to coronary heart disease.⁽³⁾ Early calcifications in one wall may simulate linear calcifications in DCIS. Spot magnification view can help identify the uncalcified vessel coming in and going out of the calcified area. Coarse or popcorn-like calcifications represent involuting fibroadenomas. After menopause, fibroadenomas undergo degeneration and calcify. Calcifications usually begin at the periphery of the mass, and become larger and denser. Finally, the soft tissue component is no longer seen, leaving only the characteristic coarse or popcorn-like calcifications (Fig. 3).

Large rod-like calcifications are due to secretory

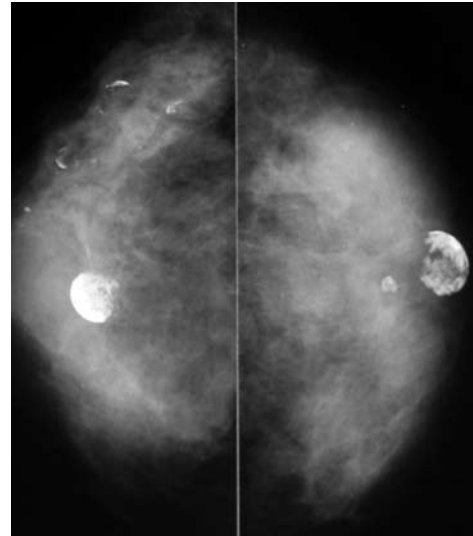


Fig. 8 Bilateral craniocaudal mammograms shows multiple lucent calcifications of fat necrosis.

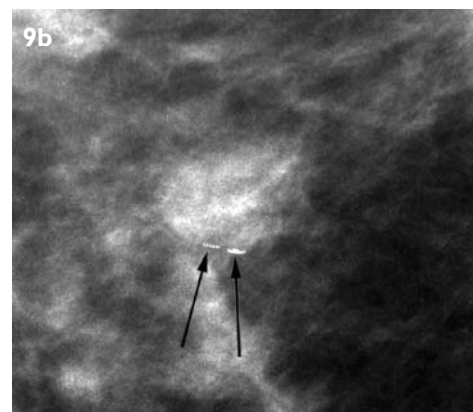
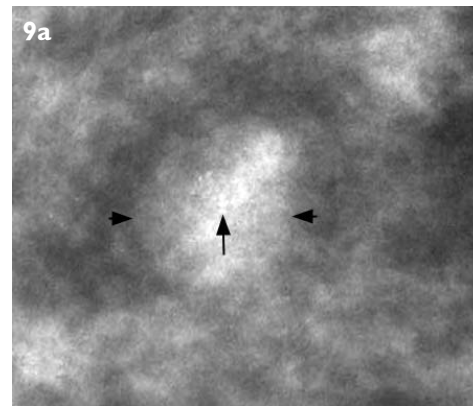


Fig. 9 Milk of calcium in a cyst. (a) Craniocaudal magnification view shows a circumscribed mass (arrowheads) with faint clustered calcifications (arrow). (b) Lateral magnification view shows layering of calcium at the bottom of the cyst (arrows).

disease, which is also known as duct ectasia or plasma cell mastitis. The disease often occurs in perimenopausal or postmenopausal women. The cause of the duct ectasia is uncertain, but may be due to obstruction from thickened secretions leading to ductal dilatation. Secretory material

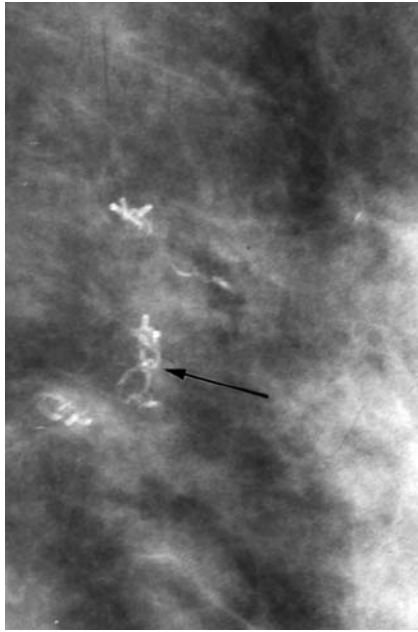


Fig. 10 Left mediolateral oblique mammogram shows the knots in the calcified suture material (arrow).

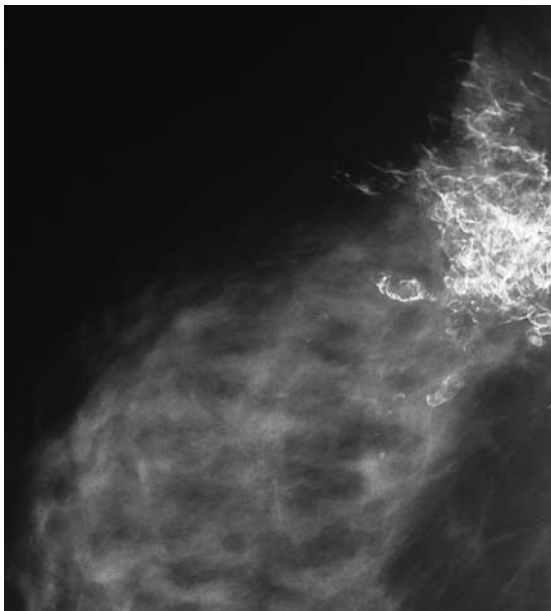


Fig. 11 Right mediolateral oblique mammogram of a patient, who had been treated with lumpectomy and radiation for breast carcinoma, shows large, irregular, bizarre calcifications.

may burst through the distended duct wall producing periductal inflammation. Intraductal calcifications appear as a smooth, marginated solid, with a large rod-like appearance or a thinner, needle-like-shaped appearance. Periductal calcifications appear as hollow cylinders. These calcifications are usually seen in the subareolar area, and branch out along the ductal system (Fig. 4). Round calcifications may vary in size from 2 to 4 mm. The term “punctate” can be used when calcifications are less than 0.5 mm in size. They are frequently formed in the acini of

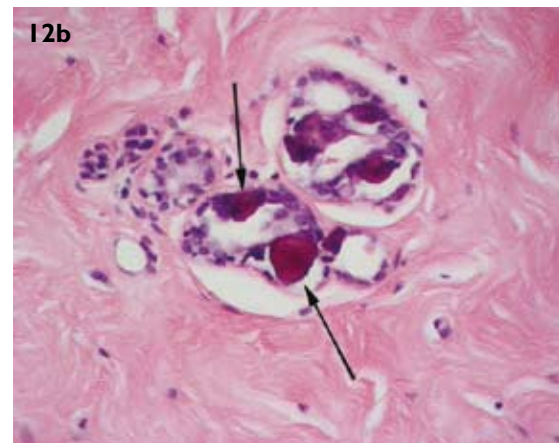
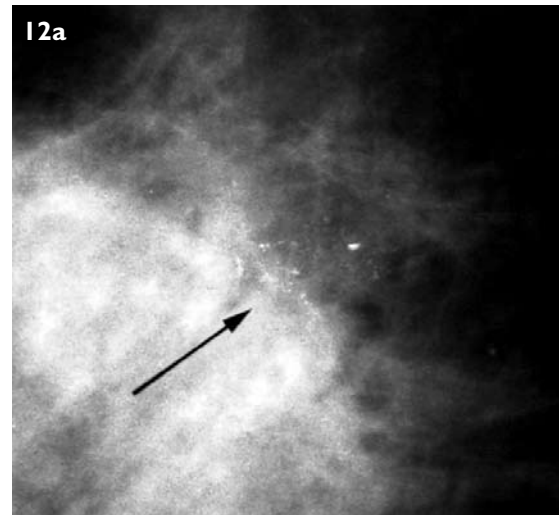

Fig. 12 (a) Magnification view shows a group of amorphous calcifications (arrow). (b) Photomicrograph shows fibrocystic change with calcifications in the lumen (arrows) (Haematoxylin & eosin, $\times 40$).

lobules due to adenosis. They can be considered benign when scattered or diffuse (Fig. 5). An isolated cluster of punctate calcifications may warrant close follow-up or even a biopsy (Fig. 6).

Lucent-centred and eggshell or rim calcifications are round calcifications with a radiolucent centre. Eggshell or rim calcifications (Fig. 7) are thinner than lucent-centred calcifications (Fig. 8). They represent calcifications in the wall of a cyst, lipid cyst or fat necrosis. Milk of calcium in cysts represent calcium that sediments in the dependent portion of the cysts. They are seen as poorly-defined smudges on the craniocaudal view, and linear or curvilinear on the lateral view (Fig. 9). Suture calcifications represent calcium deposited on suture materials. They have a characteristic linear or tubular appearance where the knots are frequently visible (Fig. 10). Dystrophic calcifications resulting from surgery or radiation are coarse and irregular and have a bizarre or plaque-like shape (Fig. 11). They often have lucent centres.

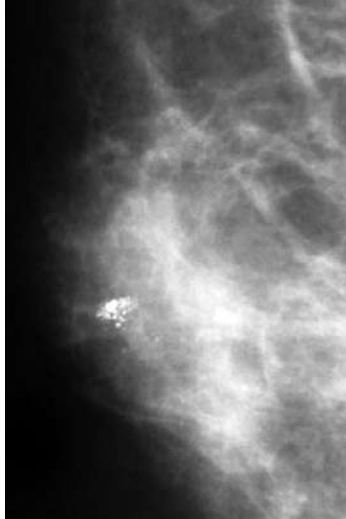


Fig. 13 Right mediolateral oblique mammogram shows a group of coarse, heterogeneous calcifications, which proved to be calcified degenerating fibroadenoma.

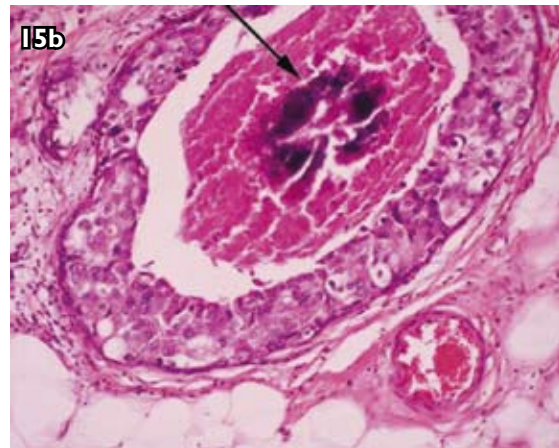
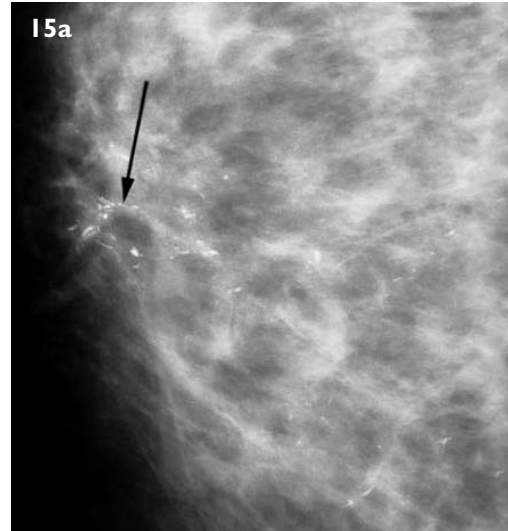


Fig. 15 (a) Magnification view shows fine, linear, branching calcifications of comedocarcinoma (arrow). (b) Photomicrograph shows a distended duct lined with high-nuclear-grade tumour cells and necrotic debris with calcification (arrow) in the lumen (Haematoxylin & eosin, $\times 200$).

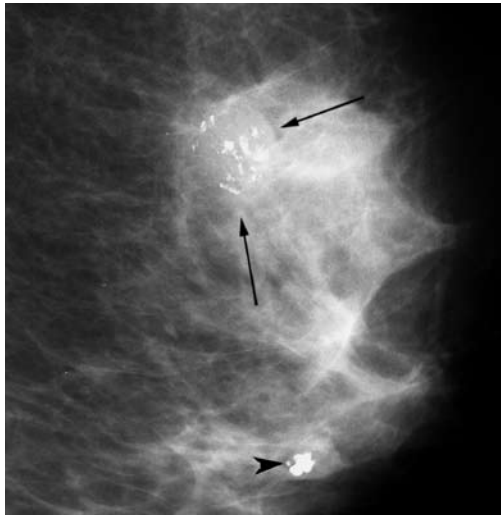

Fig. 14 Left mediolateral oblique mammogram shows an ill-defined mass (arrows) with coarse, heterogeneous calcifications, which proved to be invasive ductal carcinoma. Associated large calcifications of degenerating fibroadenoma (arrowhead) are also seen.

INTERMEDIATE-CONCERN CALCIFICATIONS

These calcifications are not typically benign nor higher probability of malignancy. They are amorphous or indistinct (Fig. 12), and coarsely heterogeneous (Figs. 13 & 14). Management of these calcifications may be periodic short-term mammographic follow-up or investigative via a biopsy. Diffuse, scattered, amorphous calcifications are usually benign, while clustered, regional, linearly or segmentally distributed, amorphous calcifications may warrant a biopsy. Coarsely heterogeneous calcifications are irregular, usually larger than 0.5 mm in size and tend to coalesce, but not to the size of irregular dystrophic calcifications. They may represent malignancy or areas of fibrosis, fibroadenomas, or trauma representing evolving dystrophic calcifications.

HIGHER PROBABILITY OF MALIGNANCY

Calcifications suggestive of malignancy are typically grouped/clustered, fine, linear, branching, pleomorphic (varying in size and shape), and numerous. These types of calcifications are only rarely associated with benign conditions, and biopsy is indicated. Malignant calcifications may occur alone or may be associated with a tumour mass or parenchymal distortion. These calcifications may occur from necrotic debris in the ducts in comedocarcinoma or from stagnation of secretion within the cystic spaces and cleft-like openings or within the interstices in noncomedocarcinoma.^(4,5) Comedocarcinoma is a high-nuclear-grade DCIS and noncomedocarcinoma is a low- to intermediate-nuclear-grade DCIS. Comedocarcinoma is characterised by proliferation of high-nuclear-grade tumour cells that undergo necrosis, forming necrotic debris in the duct lumen. Calcifications developing in the necrotic debris are typically fine, linear, branching, conforming to

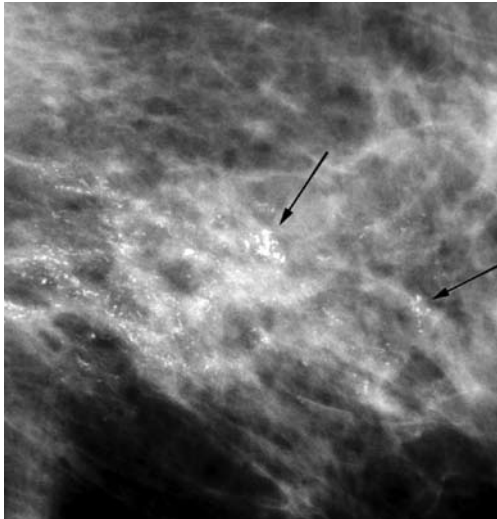


Fig. 16 Magnification view shows a segmental distribution of fine, linear, branching calcifications and two groups of pleomorphic calcifications (arrows). Diagnosis was invasive ductal carcinoma with extensive intraductal component.

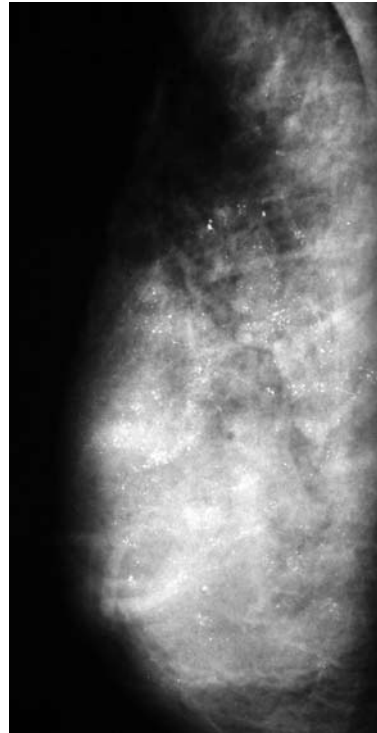


Fig. 18 Right mediolateral oblique mammogram shows a dense breast with diffuse punctate calcifications. Diagnosis was invasive ductal carcinoma with an extensive intraductal component.

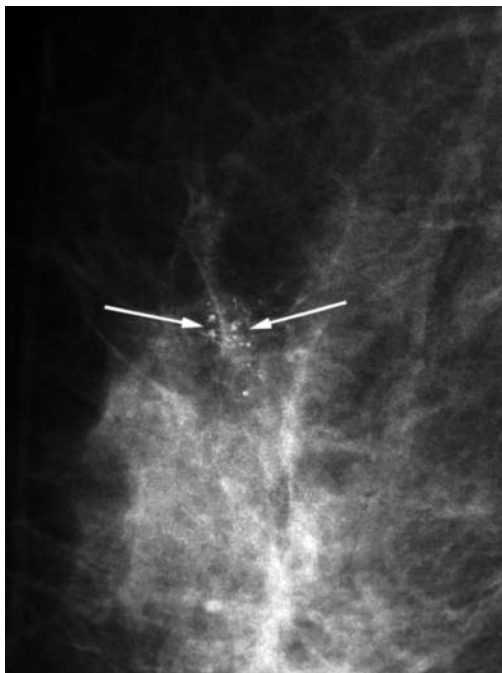

Fig. 17 Magnification view shows a cluster of mixed round and amorphous calcifications (arrows). Diagnosis was ductal carcinoma *in situ*, mixed comedo- and noncomedocarcinoma.

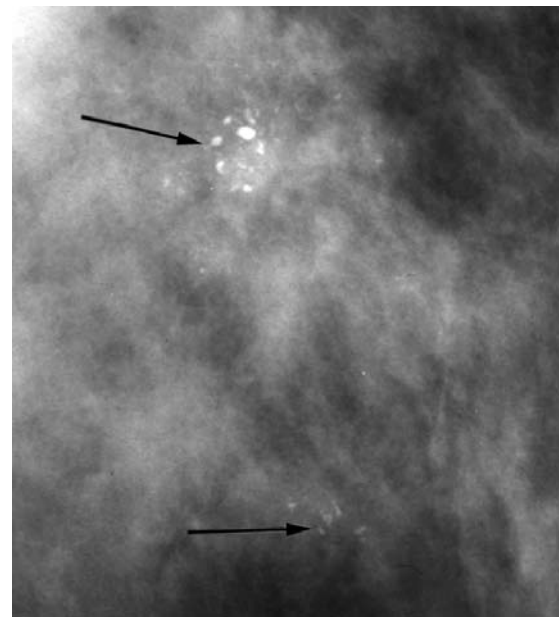


Fig. 19 Magnification view shows two groups of pleomorphic calcifications (arrows). Diagnosis was ductal carcinoma *in situ*, mixed comedo- and noncomedocarcinoma.

the linear shape and distribution of the ducts. They may also have segmental or regional distribution (Figs. 15 & 16). These types of calcifications are highly specific for malignancy. Mammography fairly accurately estimates the extent of the disease. Where the mammographers see calcifications is where the pathologists find DCIS. In noncomedocarcinoma, calcifications occurring from stagnation of secretion are punctate, round or amorphous with variable densities within a cluster and among clusters

(Figs. 17 & 18). A mixture of different types of calcifications results in a pleomorphic pattern (Figs. 19 & 20). These types of calcifications are less specific for malignancy. They can be found in fibroadenoma, papilloma or fibrocystic change. Mammography tends to underestimate the extent of the disease because the calcifications we see may be in areas of

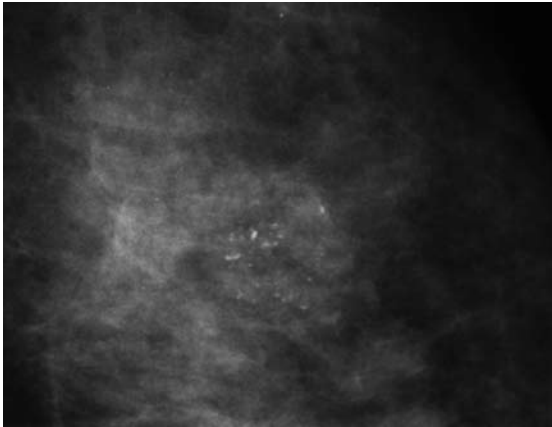


Fig. 20 Magnification view shows a cluster of pleomorphic calcifications. Diagnosis was fibrocystic change.

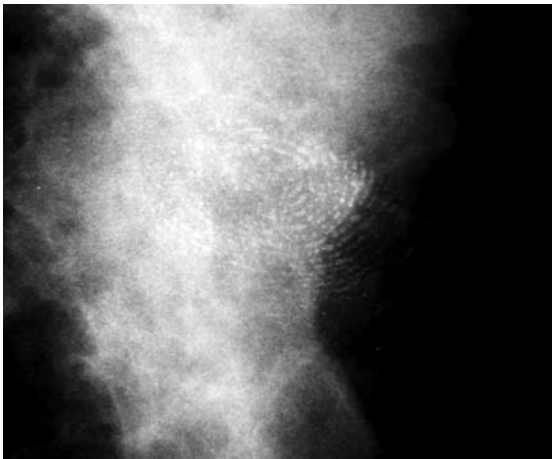

Fig. 21 Craniocaudal magnification view shows an artifact from fingerprint-simulating calcifications.

hyperplasia or atypical hyperplasia that are next to an area of noncomedo DCIS that had no associated calcifications.

PSEUDOCALCIFICATIONS

Many artifacts may simulate breast calcifications.⁽⁶⁾ Such artifacts include a scratch or “pick-off” of film emulsion, deodorant, talcum powder, tattoos, hair, fingerprints (Fig. 21), dust and dirt (Fig. 22). Meticulous attention to detail during handling, loading, processing of films and strict adherence to all steps in quality control can minimise the occurrence of artifacts.

CONCLUSION

Detection and evaluation of calcifications from mammography are crucial because they can be the sole manifestation of breast carcinoma. However, most mammographic calcifications are benign. Therefore, it is important for radiologists to provide more sensitive and specific interpretation. High-quality image and magnification views are essential for the detection and

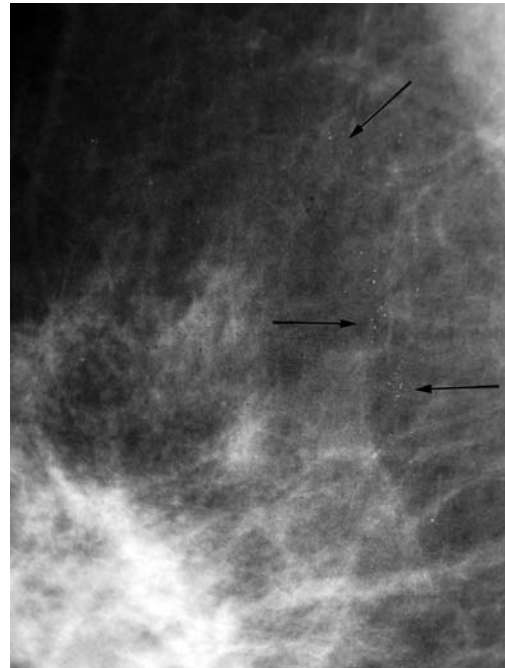


Fig. 22 Right mediolateral oblique mammogram shows multiple white spots simulating microcalcifications (arrows) from dust and dirt in the intensifying screen.

evaluation of breast calcifications. The ACR BI-RADS classifies calcifications on mammograms into three categories: typical benign, intermediate concern, and higher probability of malignancy, according to the types and distribution of calcifications. Typical benign calcifications need no further investigation, but the higher probability of malignant calcifications require a biopsy. Intermediate-concern calcifications are not typically benign or malignant, and require either a periodic short-term mammographic follow-up or a biopsy.

REFERENCES

1. Feig SA. Mammographic evaluation of calcifications. In: Kopans DB, Mendelson EB, eds. *Syllabus: A Categorical Course in Breast Imaging*. Oak Brook: Radiological Society of North America Publications, 1995: 93-105.
2. American College of Radiology: *Breast Imaging Reporting and Data System (BI-RADS)*. 4th ed. Reston: American College of Radiology, 2003.
3. Moshedy AC, Puthawala AH, Kurland RJ, O’Leary DH. Breast arterial calcification: association with coronary artery disease. Work in progress. *Radiology* 1995; 194:181-3.
4. Bassett LW. Mammographic analysis of calcifications. *Radiol Clin North Am* 1992; 30:93-105.
5. Cardenosa G. Breast calcifications. In: Feig SA, ed. *2005 Syllabus: Categorical Course in Diagnostic Radiology--Breast Imaging*. Oak Brook: Radiological Society of North America Publications, 2005: 31-41.
6. Chaloeykitti L, Muttarak M, Ng KH. Artifacts in mammography: ways to identify and overcome them. *Singapore Med J* 2006; 47:634-40.

SINGAPORE MEDICAL COUNCIL CATEGORY 3B CME PROGRAMME
Multiple Choice Questions (Code SMJ 200909B)

- | | True | False |
|--|--------------------------|--------------------------|
| Question 1. Typical benign calcifications include: | | |
| (a) Popcorn-like calcifications. | <input type="checkbox"/> | <input type="checkbox"/> |
| (b) Large rod-like calcifications. | <input type="checkbox"/> | <input type="checkbox"/> |
| (c) Clustered punctate calcifications. | <input type="checkbox"/> | <input type="checkbox"/> |
| (d) Dystrophic calcifications. | <input type="checkbox"/> | <input type="checkbox"/> |
| Question 2. Concerning benign calcifications: | | |
| (a) A tangential view is used to confirm milk of calcium calcifications. | <input type="checkbox"/> | <input type="checkbox"/> |
| (b) Early vascular calcifications may mimic calcifications seen in DCIS. | <input type="checkbox"/> | <input type="checkbox"/> |
| (c) Dystrophic calcifications represent secretory disease. | <input type="checkbox"/> | <input type="checkbox"/> |
| (d) Scattered round calcifications are found in adenosis. | <input type="checkbox"/> | <input type="checkbox"/> |
| Question 3. Concerning intermediate-concern calcifications: | | |
| (a) They can be amorphous in appearance. | <input type="checkbox"/> | <input type="checkbox"/> |
| (b) They can be coarsely heterogeneous. | <input type="checkbox"/> | <input type="checkbox"/> |
| (c) They can be linear branching. | <input type="checkbox"/> | <input type="checkbox"/> |
| (d) A biopsy is the treatment of choice. | <input type="checkbox"/> | <input type="checkbox"/> |
| Question 4. Concerning higher probability of malignant calcifications: | | |
| (a) They are typically seen as grouped or clustered calcifications that vary in size and shape. | <input type="checkbox"/> | <input type="checkbox"/> |
| (b) Calcifications found in comedocarcinoma are usually punctuate, round or amorphous with variable densities. | <input type="checkbox"/> | <input type="checkbox"/> |
| (c) Calcifications found in noncomedocarcinoma are typically fine, linear and branching. | <input type="checkbox"/> | <input type="checkbox"/> |
| (d) Pleomorphic calcifications can either be benign or malignant. | <input type="checkbox"/> | <input type="checkbox"/> |
| Question 5. Concerning management of calcifications found on mammography: | | |
| (a) Hollow cylinder calcifications need no further investigation. | <input type="checkbox"/> | <input type="checkbox"/> |
| (b) Eggshell calcifications need short interval follow-ups. | <input type="checkbox"/> | <input type="checkbox"/> |
| (c) Pleomorphic calcifications should be managed by biopsy. | <input type="checkbox"/> | <input type="checkbox"/> |
| (d) Fine, linear and branching calcifications require biopsy. | <input type="checkbox"/> | <input type="checkbox"/> |

Doctor's particulars:

Name in full: _____

MCR number: _____ Specialty: _____

Email address: _____

SUBMISSION INSTRUCTIONS:

(1) Log on at the SMJ website: <http://www.sma.org.sg/cme/smj> and select the appropriate set of questions. (2) Select your answers and provide your name, email address and MCR number. Click on "Submit answers" to submit.

RESULTS:

(1) Answers will be published in the SMJ November 2009 issue. (2) The MCR numbers of successful candidates will be posted online at www.sma.org.sg/cme/smj by 15 November 2009. (3) All online submissions will receive an automatic email acknowledgment. (4) Passing mark is 60%. No mark will be deducted for incorrect answers. (5) The SMJ editorial office will submit the list of successful candidates to the Singapore Medical Council.

Deadline for submission: (September 2009 SMJ 3B CME programme): 12 noon, 1 November 2009.