

Symptomatic anaemia 17 years after double valve replacement

Wong M H, Chee K H, Azman W

ABSTRACT

A 40-year-old Malay woman presented with increasing lethargy, palpitation and shortness of breath, 17 years after a mitral and aortic valve replacement. A Starr-Edwards prosthetic valve replaced the mitral valve, and a Bjork-Shiley prosthetic valve replaced the aortic valve. Biochemical parameters demonstrated intravascular haemolysis, as evidenced by haemoglobin 7.8 g/dL, reticulocyte count 8.4%, lactate dehydrogenase 2,057 IU/L and low haptoglobin levels (less than 6 mg/dL). Transoesophageal echocardiography revealed a paravalvular leakage over the mitral valve. The haemoglobin levels remained persistently low despite frequent blood transfusion. She successfully underwent a second mitral valve replacement. Her anaemia resolved subsequently.

Keywords: anaemia, haemolysis, haemolytic anaemia, paravalvular leakage, prosthetic valve

Singapore Med J 2009;50(10):e362-e364

INTRODUCTION

Haemolysis is a common clinical finding among patients with prosthetic heart valves. Transoesophageal echocardiographical studies done post-valve replacement have demonstrated small paraprosthetic leaks which are not associated with subclinical haemolysis, and are considered benign during the first year after post-valve replacement.⁽¹⁾ Therefore, when the degree of haemolysis leads to severe or symptomatic anaemia, the physician needs to suspect a paravalvular leak of the prosthesis. The reported incidence of major paravalvular leaks varies from 1% to 5%.⁽²⁻⁴⁾

CASE REPORT

A 40-year-old Malay woman underwent a double valve replacement for severe mitral and aortic regurgitation 17 years ago, due to underlying chronic rheumatic heart disease. A Starr-Edwards prosthetic valve replaced the mitral valve, and a Bjork-Shiley prosthetic valve replaced the aortic valve. She had remained well until September

2007 when she presented with increasing lethargy and shortness of breath for two months. She noted that her urine had turned dark. There was no history of abdominal pain, pale stools or pruritus. There was no evidence of infection or any history to suggest a connective tissue disease. Her menses was regular and there was no menorrhagia. The past medical history revealed that she had undergone a right oophorectomy in 1996 for a right ovarian cyst. She underwent a tooth extraction in March 2007 without complication. Her haemoglobin level was normal during these admissions.

The clinical examination revealed a pale and jaundiced patient. There were no stigmata of infective endocarditis. Her blood pressure and heart rate were normal. The cardiovascular examination revealed a midline thoracotomy scar, and the prosthetic click typical of a ball and cage valve was heard. There was no evidence of bleeding. There was no palpable liver or spleen on abdominal examination. Examination of the other systems was unremarkable. Chest radiograph revealed a ball and cage valve prosthesis. Electrocardiography was in sinus rhythm with a heart rate of 92/minute. The haemoglobin level at presentation was 7.8 g/dL. The peripheral blood film revealed normochromic, normocytic anaemia with evidence of haemolysis and the presence of schistocytes and polychromatic cells. The reticulocyte count was 8.4%, lactate dehydrogenase (LDH) 2,057 IU/L, and haptoglobin was low at < 6 mg/dL. Connective tissue screening revealed a raised rheumatoid factor of 84 IU/ml. Anti-nuclear antibody, anti-neutrophil cytoplasmic antibody and anti-smooth muscle antibody were all negative. Serum C3 and C4 were within normal limits. Coombs test was negative.

On this admission, she was transfused two pints of pack cells to treat her symptomatic anaemia, and she subsequently underwent transoesophageal echocardiography (TEE), which revealed a paravalvular regurgitant jet, seen at the lateral annulus (Figs. 1 & 2). There was no evidence of thrombus or vegetation. Her symptoms improved, and she was discharged after the blood transfusion. She presented again a month later with symptomatic anaemia and was given further blood transfusions. Blood work-up showed a similar picture to her initial presentation, and there was again evidence

Department of
Medicine,
Faculty of Medicine,
University of Malaya,
Kuala Lumpur 50603,
Malaysia

Wong MH, MBBS
Medical Officer

Chee KH, MBBS,
MMed
Associate Professor

Azman W, MBBS,
FRCP
Professor

Correspondence to:
Dr Wong Mun Hoe
Tel: (60) 3 7949 2429
Fax: (60) 3 7960 4190
Email: drwongmh@gmail.com

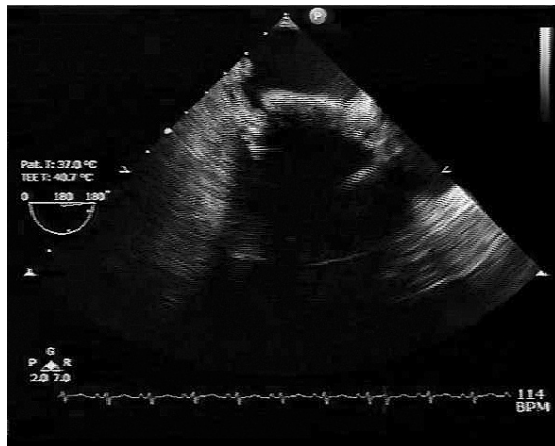


Fig. 1 Transoesophageal echocardiogram shows the Starr-Edwards mitral valve prosthesis with paravalvular leak.

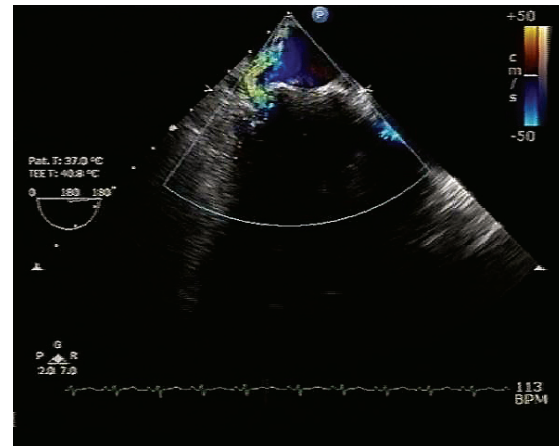


Fig. 2 Transoesophageal echocardiogram shows the Starr-Edwards mitral valve prosthesis with paravalvular leak demonstrated on colour Doppler.

of intravascular haemolysis. A repeated TEE showed similar findings of paravalvular regurgitation. Her blood transfusion requirements increased and she required regular blood transfusion of two pints pack cells at two-month intervals. This prompted further management. After careful discussion with family members and the cardiothoracic team, she underwent a re-operation to replace the leaking prosthetic mitral valve on January 2, 2008.

Intraoperative findings confirmed a paravalvular leak over the posterior prosthetic mitral valve. Inspection of the prosthetic aortic valve did not reveal any abnormality. A mitral valve replacement redo with a 30-mm Starr-Edwards ball prosthesis was inserted to replace the leaking valve. The histopathological examination showed a perivalvular tissue with no vegetation. Postoperatively, she remained well and did not require further blood transfusions to treat her anaemia. She was last seen after three months post-redo mitral valve replacement. Her haemoglobin level remained stable at 13.4 g/dL, and she showed good effort tolerance.

DISCUSSION

Paravalvular leakage results from an incomplete seal between the sewing ring and the valve annulus. Doppler echocardiography can identify paravalvular leaks with high specificity and sensitivity. The addition of colour flow Doppler imaging can identify the origin of the regurgitant jet, which helps differentiate transvalvular from paravalvular leaks.⁽⁵⁾ Infection remains a common cause of paravalvular leak as infected tissue is more friable than healthy tissue. Other causes include surgical techniques, such as suturing method, type of stitches and type of sewing ring.⁽⁵⁾

Anaemia secondary to paravalvular leaks have been

reported. The anaemia usually occurs years after the valve replacement. Misawa et al reported two women presenting with shortness of breath and fatigability eight and nine years after mitral valve replacement, respectively.⁽⁶⁾ Ye et al reported a case of repeat mitral valve replacement after 25 years, due to structural cloth wear and tear.⁽⁷⁾ In our patient, who presented 17 years after the valve replacement, the cause of her paravalvular leak was probably due to wear and tear.

Increased levels of LDH, reduced serum haptoglobulins and reticulocytosis are markers of intravascular haemolysis.⁽⁸⁾ These are common findings in patients with prosthetic valve replacement, which however, rarely lead to severe haemolytic anaemia. Severe haemolysis usually suggests a paravalvular leakage due to partial dehiscence of the valve leaflet or infection. Blood films will support the diagnosis of haemolysis, and Coombs test allows the differentiation of autoimmune haemolytic anaemia from mechanical haemolysis. The type of prosthetic implant used for surgery has been associated with some degree of haemolysis. Patients with caged-ball valve replacements are at higher risks of severe haemolysis compared to disc valves.⁽⁹⁾

Surgery remains the gold standard of severe haemolysis secondary to paravalvular leaks, especially in patients who require repeated blood transfusions.^(10,11) Haemoglobin levels and symptoms improve in most patients postoperatively. However, repeated valve replacements carry significant morbidity and mortality. Echevarria et al reported a hospital mortality of 12.6%, 14.9% and 37% after the first, second and third valve replacements, respectively.⁽¹²⁾ Higher hospital mortality was related to an advanced age at the time of the surgery, poor preoperative functional class, emergency surgery, concomitant tricuspid surgery, double (mitra-aortic) valve

dysfunction, active infective endocarditis as the cause of failure and prolonged aortic cross-clamping time during surgery.

In conclusion, haemolysis is a common finding in patients with prosthetic valve replacement. For patients who present with symptomatic haemolytic anaemia and require repeated blood transfusions, paravalvular leaks should be excluded with TEE. In these patients, surgery should be considered.

REFERENCES

1. Ionescu A, Fraser AG, Butchart EG. Prevalence and clinical significance of incidental paraprosthetic valvular regurgitation: a prospective study using transoesophageal echocardiography. *Heart* 2003; 89:1316-21.
2. Rallidis LS, Moyssakis IE, Ikonomidis I, Nihoyannopoulos P. Natural history of early aortic paraprosthetic regurgitation: a five year follow-up. *Am Heart J* 1999; 138 (2 Pt 1):351-7.
3. Miller DL, Morris JJ, Schaff HV, et al. Reoperation for aortic valve periprosthetic leakage: identification of patients at risk and results of operation. *J Heart Valve Dis* 1995; 4:160-5.
4. Jindani A, Neville EM, Venn G, Williams BT. Paraprosthetic leak: a complication of cardiac valve replacement. *J Cardiovasc Surg (Torino)* 1991; 32:503-8.
5. Bhindi R, Bull S, Schrale RG, Wilson N, Ormerod OJ. Surgery insight: percutaneous treatment of prosthetic paravalvular leaks. *Nat Clin Pract Cardiovasc Med* 2008; 5:140-7.
6. Misawa Y, Konishi H, Saito T, Fuse K. Paravalvular leakage causing hemolytic anemia at 8-9 years after mitral valve replacement. *Jpn J Thorac Cardiovasc Surg* 2002; 50:530-2.
7. Ye Z, Shiono M, Sezai A, et al. Reoperation for a patient 25 years after a Starr-Edwards ball mitral valve was installed. *Ann Thorac Cardiovasc Surg* 2002; 8:311-5.
8. Vongpatanasin W, Hillis LD, Lange RA. Prosthetic heart valves. *N Eng J Med* 1996; 335:407-16.
9. Falk RH, Mackinnon J, Wainscoat J, Melikian V, Bignell AH. Intravascular haemolysis after valve replacement: comparative study between Starr-Edwards (ball valve) and Björk-Shiley (disc valve) prosthesis. *Thorax* 1979; 34:746-8.
10. Kirali K, Mansuroglu D, Yaymaci B, et al. Paravalvular leakage after mitral valve replacement: is left atrial enlargement an additional indication for reoperation? *J Heart Valve Dis* 2001; 10: 418-25.
11. Genoni M, Franzen P, Vogt P, et al. Paravalvular leakage after mitral valve replacement: improved long-term survival with aggressive surgery? *Eur J Cardiothorac Surg* 2000; 17:14-9.
12. Echevarria JR, Bernal JM, Rabasa JM, et al. Reoperation for bioprosthetic valve dysfunction. A decade of clinical experience. *Eur J Cardiothorac Surg* 1991; 5:523-6.