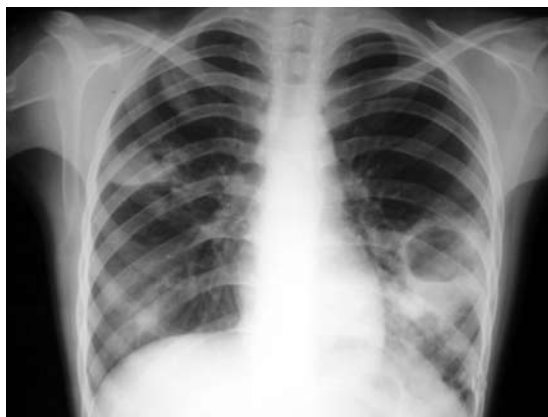

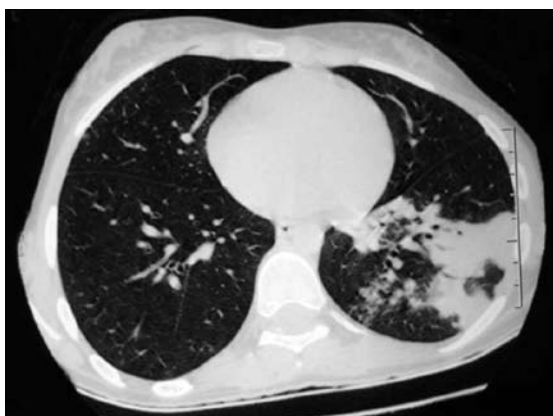**LUNG ABSCESS SECONDARY TO NON-TYPHOIDAL SALMONELLOSIS IN AN IMMUNOCOMPETENT GIRL**

Dear Sir,


Non-typhoidal salmonellosis (NTS) is a common cause of self-limited diarrhoea in healthy children. The responsible organisms may, at times, become invasive with resultant bacteraemia and focal infections.<sup>(1)</sup> Although it is more commonly seen in immunocompromised and chronically-ill children, it may be observed rarely in otherwise healthy, immunocompetent ones. The aim of this letter was to report an 11-year-old immunocompetent girl with *Salmonella* (*S.*) group B spp. lung abscess and thrombocytopenia, resulting in skin and subconjunctival bleed during the course of her infection. This otherwise healthy Hindu Bengali girl, born to non-consanguineous parents, presented with complaints of fever and productive cough, with respiration difficulty of one-month duration. She had associated loose stools which commenced five days prior to the onset, and lasted for ten days. The stools were not accompanied by mucus or blood. Vomiting and painful defaecation were absent. Prior to admission, the girl had received oral amoxicillin 30 mg/kg/day for five days from a local general practitioner, but there was no improvement in her condition. She had become progressively septic with increasing anorexia over the last three days.



**Fig. 1** Chest radiograph shows a thick-walled lung abscess with an air cavity in the lower left zone.



**Fig. 2** High-resolution CT image shows areas of consolidation with an air cavity in the left lower lobe.



**Fig. 3** Photograph shows subconjunctival haemorrhage in the right eye.

On examination, she was febrile and dehydrated with an intact sensorium. She was tachypnoeic and had laboured breathing. The auscultation revealed cavernous breath sounds (low-pitched bronchial breath sounds typically heard in cavities within the lung) and post-tussive crepitations in the left mammary and infrascapular areas. The liver and spleen were enlarged to 2.5 cm and 3 cm below the right and left costal margins, respectively. The haematological investigations revealed the following: haemoglobin 8.4 g/dL, total leucocyte count 3,200/mm<sup>3</sup> (64% neutrophils, 34% lymphocytes), and platelet count 35,500/mm<sup>3</sup>. The arterial blood gas analysis was normal. Initial bone marrow

examination, to exclude autoimmune thrombocytopenia, revealed increased trilineage cellularity without evidence of haemophagocytosis. The Widal test was positive (O titre at 1: 320 dilution). A Giemsa-stained peripheral blood smear for malarial parasites was negative. The liver function tests demonstrated evidence of mild hepatitis. The culture of the stool specimen for pathogenic organisms was negative.

The chest radiograph revealed a thick-walled abscess in the left lower zone (Fig. 1). High-resolution computed tomography of the thorax revealed confluent areas of consolidation with air-containing cavities at the apical, anterior, lateral and posterior basal segments of the left lower lobe (Fig. 2). A chest ultrasonography-guided aspiration of the abscess revealed thick yellow pus (about 35 ml) with an abundance of polymorphonuclear leucocytes. The culture of the pus was positive for *S. group B spp.*, and sensitive to ceftriaxone, amikacin and ciprofloxacin. The blood culture was sterile, and the enzyme-linked immunosorbent assay (ELISA) for HIV-I and II were negative. Laboratory tests directed towards the immune functions of the child were undertaken at this time. The serum immunoglobulin profile revealed the following values: IgG 9.2 (reference range for 7–12 years [RR<sub>7-12</sub>] 7.3–15.1) g/L; IgM 1.3 (RR<sub>7-12</sub> 0.55–2.1) g/L; IgA 2.7 (RR<sub>7-12</sub> 0.70–3.25) g/L. The CD4+ count was estimated at 845 (95% RR 415–1,189) cells/ $\mu$ L; the CD8+ count was 425 (95% RR 336–780) cells/ $\mu$ L; and the calculated CD4+:CD8+ ratio was 1.99:1 (95% RR 0.72–2.56).

The patient was administered intravenous ceftriaxone for 14 days, followed by another 14 days of oral cefixime. On the fourth post-admission day, she developed a few petechial spots on the skin and right eye subconjunctival bleed (Fig. 3). Bleeding from other sites was absent, and the stool guaiac test was negative. The platelet count at this time was 12,500/mm<sup>3</sup>. The prothrombin time, activated partial thromboplastin time and the D-dimer assay were normal. She was transfused with fresh platelet concentrates. There was no evidence of further bleed. The girl became afebrile after ten days of initiation of the intravenous antibiotic therapy. The repeat platelet count on the tenth day of admission was normal. She was discharged on the 18th post-admission day, having made a full clinical recovery. The chest radiograph at the end of six weeks showed a complete resolution of the abscess.

Non-typhoidal *S. spp.* are an important cause of acute gastroenteritis in children of developing countries, and contribute largely to the morbidity and mortality.<sup>(1)</sup> Extraintestinal manifestations due to these organisms are rare and occur most commonly in immunocompromised adults.<sup>(2)</sup> Factors such as the widespread use of antibiotics prior to hospital admission and the low invasive potential of the non-typhoidal *S. spp.*, may be responsible for the reduced magnitude of extraintestinal manifestations seen.<sup>(3)</sup> In children, bacteraemia is the most commonly-detected type of infection, and meningitis, the commonest focal infection in extraintestinal NTS.<sup>(4)</sup> Like in adults, most extraintestinal NTS occurs in children who are immunocompromised or have an underlying medical disorder. The reported girl was not immunocompromised because her immunological profile was normal. Furthermore, she had no significant medical illnesses in the past and the ELISA for HIV-I and II were non-reactive. Factors associated with invasive complications in NTS include age below six months, fever > 38°C, and dehydration on admission.<sup>(4)</sup> The most common serotypes isolated are *S. enteritidis*, *S. paratyphi B* and *S. typhimurium*.<sup>(1)</sup> The history of diarrhoea at the onset of illness suggests the entry of the offending pathogen (*S. group B spp.*) through the gastrointestinal tract. The subsequent bacteraemia may have led to the seeding of the organisms in the lung. However, her blood culture was sterile, probably due to prior treatment with amoxicillin before admission.

Haematological abnormalities commonly associated with enteric fever include anaemia and leucopenia.<sup>(5)</sup> Isolated thrombocytopenia occurring during the course of enteric fever has also been reported.<sup>(6)</sup> Salmonella-associated stimulation of haemophagocytosis has been evidenced in several reports that may explain transient pancytopenia in enteric fever. Alternatively, Serefhanoglu et al suggested that thrombocytopenia may be the result of peripheral autoimmune destruction of the platelets, based on their observation of the hypercellular bone marrow in a patient with enteric fever and who presented with isolated thrombocytopenia.<sup>(7)</sup> The bone marrow examination in our patient revealed an increased trilineage cellularity without evidence of haemophagocytosis, suggesting that the peripheral autoimmune destruction of the circulating platelets, rather than the marrow depression, was the probable reason for the observed thrombocytopenia.

A thorough MEDLINE search revealed a single report<sup>(8)</sup> documenting *S. spp.* as the primary cause of lung abscess in an immunocompetent, five-year-old otherwise-healthy girl, who had cough associated with respiratory distress of five months' duration and finger clubbing secondary to a solitary lung abscess in the right lower zone. A primary pulmonary hydatid cyst, secondarily infected with *S. typhi*, has been reported in a 12-year-old Pakistani girl.<sup>(9)</sup> In their review of 37 children with *S. spp.* bacteraemia, Ciftci et al reported a S $\beta$ <sup>+</sup>-thalassaemic child who had *S. irumu*

bacteraemia, resulting in osteomyelitis and lung abscess.<sup>(3)</sup> In conclusion, as demonstrated in the present report, focal pulmonary infections may result, secondary to NTS bacteraemia in immunocompetent children, albeit rarely.

Yours sincerely,

Rajoo Thapa  
Apurba Ghosh  
Debkrishna Mallick  
Biswajit Biswas

Department of Pediatrics  
The Institute of Child Health  
11 Dr Bireswari Guha Street  
Kolkata 700017  
West Bengal  
India  
Email: rajoothapa@yahoo.co.in

## REFERENCES

1. Bhutta ZA. Salmonella. In: Kliegman RM, Behrman RE, Jenson HB, Stanton BF, eds. Nelson Textbook of Pediatrics. 18th ed. Philadelphia: Saunders Elsevier, 2007: 1182-91.
2. Casado JL, Navas E, Frutos B, et al. Salmonella lung involvement in patients with HIV infection. Chest 1997; 112:1197-201.
3. Ciftçi E, Güriz H, Derya Aysev A, et al. Salmonella bacteraemia in Turkish children: 37 cases seen in a university hospital between 1993 and 2002. Ann Trop Paediatr 2004; 24:75-80.
4. Lee WS, Puthucherry SD, Boey CC. Non-typhoid Salmonella gastroenteritis. J Paediatr Child Health 1998; 34:387-90.
5. Pegues DA, Miller SI. Salmonellosis. In: Fauci AS, Braunwald E, Kasper DL, et al, eds. Harrison's Principles of Internal Medicine. 17th ed. New York: McGraw-Hill, 2008: 956-62.
6. Chiu CH, Tsai JR, Ou JT, Lin TY. Typhoid fever in children: a fourteen-year experience. Acta Paediatr Taiwan 2000; 41:28-32.
7. Serefhanoglu K, Kaya E, Sevinc A, et al. Isolated thrombocytopenia: the presenting finding of typhoid fever. Clin Lab Haematol 2003; 25:63-5.
8. Adhisivam B, Mahadevan S, Udaykumar C. Lung abscess caused by Salmonella. Indian J Pediatr 2006; 73:450-1.
9. Aslam F, Bhaila I, Nadeem N, Fadoo Z. Salmonella typhi-infected lung hydatid cyst. Pediatr Infect Dis J 2005; 24:270-2.