

## CME Article

## Clinics in diagnostic imaging (I28)

Chia E M Y, Teo L L S, Venkatesh S K

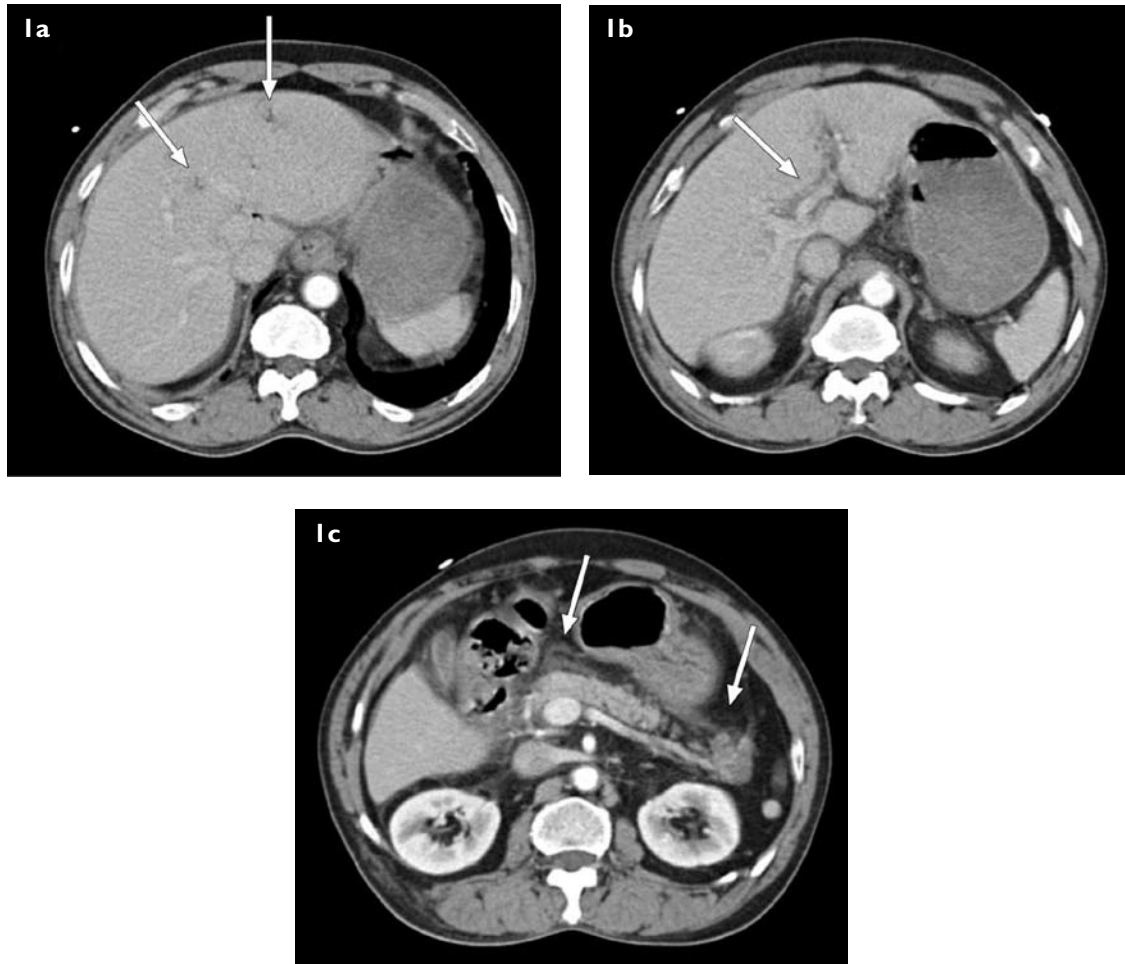


Fig. 1(a–c) Selected axial CT images obtained during the early portal venous phase.

## CLINICAL PRESENTATION

A 66-year-old man presented with a one-day history of epigastric pain. He had a background history of atrial septal defect, tricuspid regurgitation, mitral valve prolapse, chronic obstructive pulmonary disease with pulmonary hypertension, systemic hypertension and hyperlipidaemia. On physical examination, the abdomen was soft and there was mild tenderness in the epigastric region. The total white cell count on admission was normal. However, a repeat full blood count the next day revealed leucocytosis, with a white blood cell count of  $22.81 \times 10^9/L$  (normal range [NR]  $3.26\text{--}9.28 \times 10^9/L$ ); and an elevated neutrophil differential count of 90.3% (NR 43.4%–73.6%). Coagulation profile

was done, viz. prothrombin time 16.1 (NR 12.5–15.2) s, international normalised ratio 1.23, activated partial thromboplastin time 36.7 (NR 25.9–35.7) s.

An arterial blood gas showed lactic acidosis with the following results: pH 7.27 (NR 7.35–7.45);  $pCO_2$  39.9 (NR 35.0–45.0) mmHg;  $pO_2$  81.0 (NR 75.0–100.0) mmHg; bicarbonate 18.5 (NR 23.0–33.0) mmol/L; base excess  $-8.0$  (NR  $-2.0$  to  $2.0$ ) mmol/L; and lactate 2.4 (NR 0.7–2.1) mmol/L. The serum amylase was not elevated and measured 92 (NR  $< 110$ ) U/L. Initial blood and urine cultures were negative. Computed tomography (CT) of the abdomen and pelvis was performed (Figs. 1a–c). What do these images show?

Department of  
Diagnostic Imaging,  
National University  
Hospital,  
5 Lower Kent Ridge  
Road,  
Singapore 119074

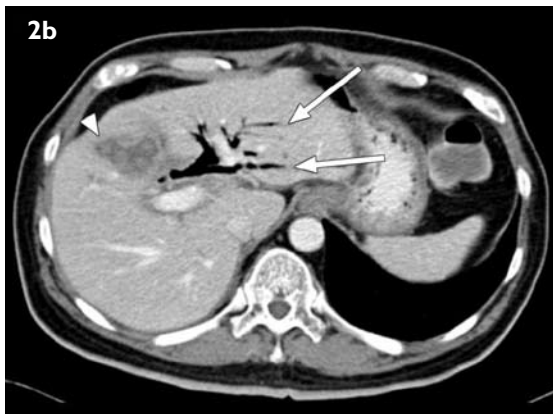
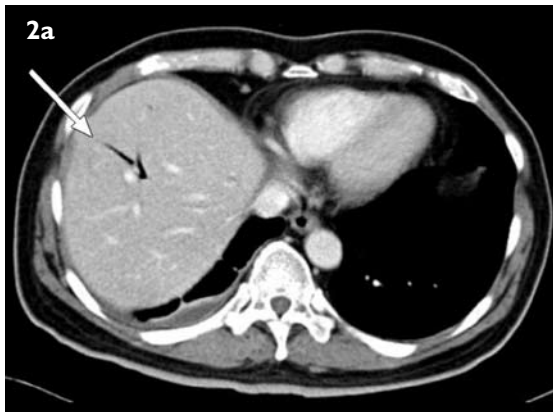Chia EMY,  
MBChBAO,  
MMed, FRCR  
Registrar

Teo LLS, MBChB,  
MMed, FRCR  
Consultant

Department  
of Diagnostic  
Radiology,  
Yong Loo Lin  
School of Medicine,  
National University  
of Singapore,  
5 Lower Kent  
Ridge Road,  
Singapore 119074

Venkatesh SK, MD,  
MMed, FRCR  
Consultant and  
Assistant Professor

Correspondence to:  
Dr Lynette Teo  
Tel: (65) 6772 5207  
Fax: (65) 6779 7101  
Email: lynette\_ls\_teo@nuhs.edu.sg



**Fig. 2** A CT example of aerobilia. (a & b) Axial CT images show biliary gas (arrows) that is found centrally, 2 cm away from the liver capsule. Liver metastasis (b) (arrowhead) is present in segment 4 of the liver in this patient with gallbladder tumour, post-insertion of a biliary stent.

### IMAGE INTERPRETATION

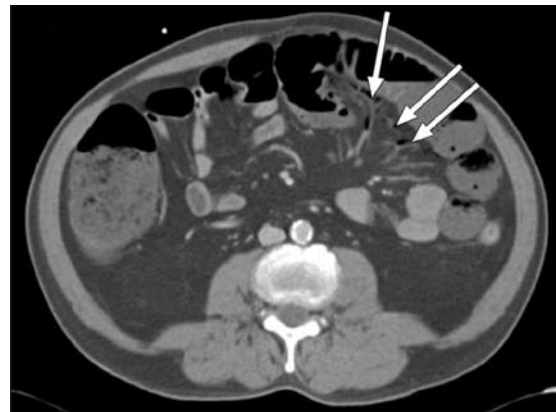
These CT images show subtle branching hypodensities (arrows) (Fig. 1a) in the peripheral non-dependent part of the liver, indicating portal venous gas. There was also partial thrombosis of the left portal vein (arrow) (Fig. 1b). Nonspecific peripancreatic fat stranding (Fig. 1c) was present. The bowel wall showed normal contrast enhancement, with no evidence of filling defects within the superior mesenteric vessels (all images are not shown).

### DIAGNOSIS

Portal pyaemia.

### CLINICAL COURSE

The patient was treated conservatively for pancreatitis. However, on the next day following admission, he developed rectal bleeding and had rebound tenderness in the right iliac fossa. The decision was made to proceed with a laparotomy. A laparotomy, done 23 hours after the CT, showed a long segment of thickening of the caecal wall extending distally to the hepatic flexure with mucosal gangrene. No perforation was detected. The rest of the



**Fig. 3** A CT example of mesenteric gas. Axial CT image shows small lucencies (arrows), consistent with gas within the mesenteric arcades in a 60-year-old man with ischaemic colitis.

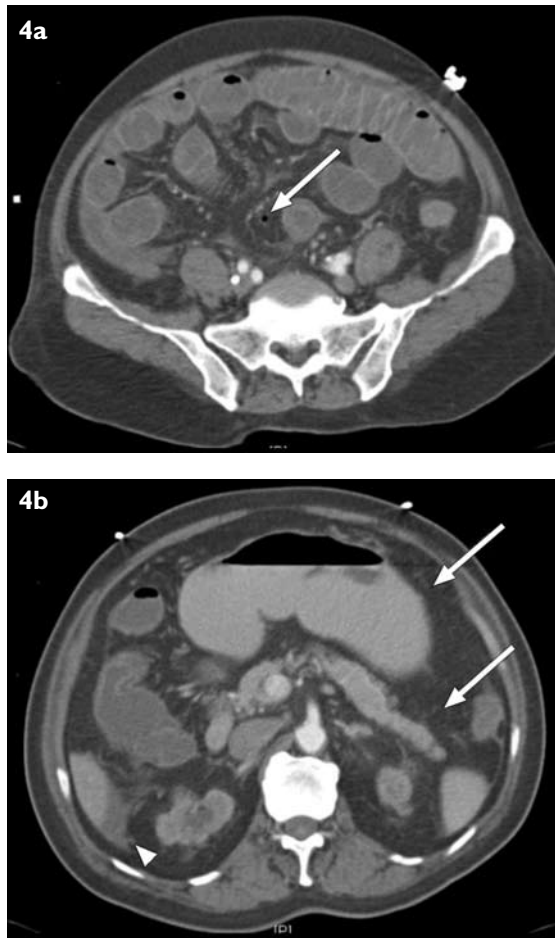
colon, small bowel, stomach, gallbladder and liver were normal. A right hemicolectomy and omentectomy were performed.

Histopathology of the hemicolectomy specimen confirmed the presence of ischaemic colitis. Ischaemic changes, ranging from lamina propria haemorrhage to full thickness ischaemic necrosis of the mucosa were present and associated with submucosal oedema and vascular congestion. Postoperatively, his stay was complicated by the development of hypoxaemia secondary to postoperative atelectasis and chronic obstructive pulmonary disease. He subsequently recovered and was discharged well. At two months follow-up, the patient was doing well with no further complaints.

### DISCUSSION

Portal pyaemia (portal pylephlebitis) is defined as the combination of infection and thrombosis within the portal veins.<sup>(1)</sup> The presence of gas, together with thrombosis, in the portal vein is a known feature in portal pyaemia.<sup>(2)</sup> Hepatic portal venous gas (HPVG) was first described in infants with necrotising enterocolitis in 1955.<sup>(3)</sup> Since then, there have been more reports of portal venous gas in the literature. There are two main theories regarding the pathogenesis of portal venous gas.<sup>(4)</sup> The first is that of a raised intraluminal pressure, resulting in intraluminal gas tracking into the intramural venous plexus through an ulcer, fissure or mucosal tear resulting in portal venous gas. Examples of this theory can be seen in patients with bowel obstruction or patients who have undergone colonoscopy or barium enema.<sup>(5,6)</sup> Another theory postulates that there is a breach in the colonic mucosa with an invasion of gas-forming organisms, resulting in mesenteric and portal venous septicaemia.

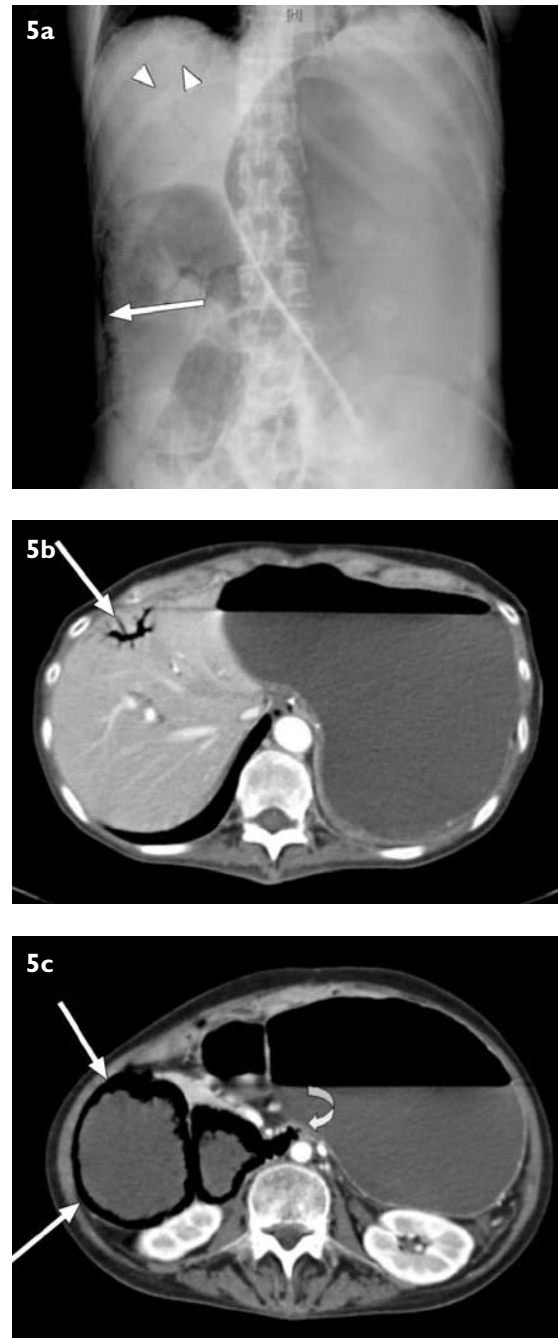
The commonest cause of HPVG is bowel ischaemia.<sup>(7,8)</sup>



**Fig. 4** Another CT example of mesenteric gas in a 65-year-old Chinese man presenting with abdominal pain. (a) Axial CT image shows a tiny pocket of air (arrow) within the mesenteric arcade with generalised small bowel dilatation. (b) Axial CT image also shows a small amount of ascites (arrowhead) and mesenteric fat stranding (arrows). Laparotomy revealed generalised primary fibrinous peritonitis, with no evidence of bowel ischaemia.

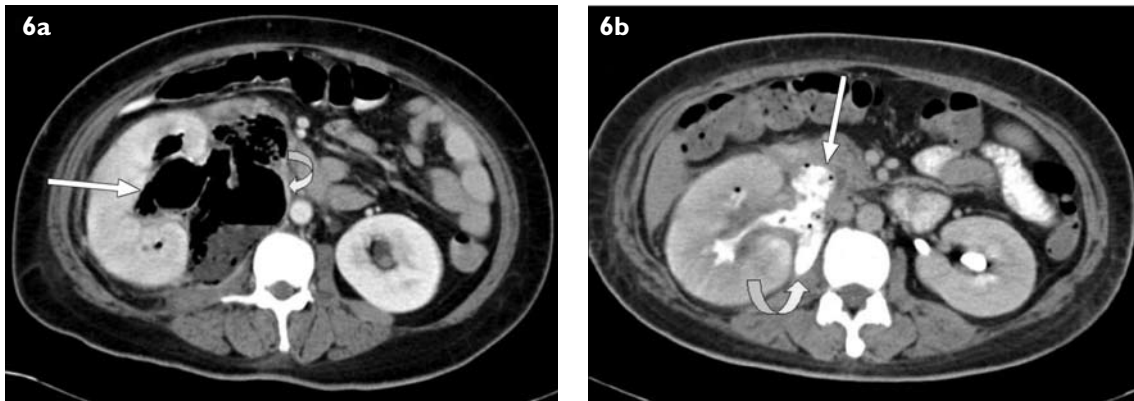
HPVG is also found in many conditions such as diverticulitis, appendicitis, intra-abdominal abscess, bowel obstruction, haemorrhagic pancreatitis, gastric ulcer, ulcerative colitis and Crohn's disease.<sup>(4,9)</sup> It may occur secondary to an infection in the region drained by the portal system or contiguous to the portal vein.<sup>(10)</sup> In our case, the CT finding of portal pyaemia was secondary to ischaemic colitis, given the subsequent clinical findings of abdominal pain and rectal bleeding, as well as the intraoperative findings. Abdominal radiograph, ultrasonography and CT are imaging modalities that are able to demonstrate portal venous gas and portal venous thrombosis. The most sensitive modality is CT.<sup>(7)</sup>

It is important to distinguish portal venous gas from biliary gas. Branching lucencies or hypodensities within 2 cm of the liver capsule on abdominal radiograph or CT is diagnostic of portal venous gas; in contrast to biliary gas, which is found centrally, i.e. more than 2 cm from the

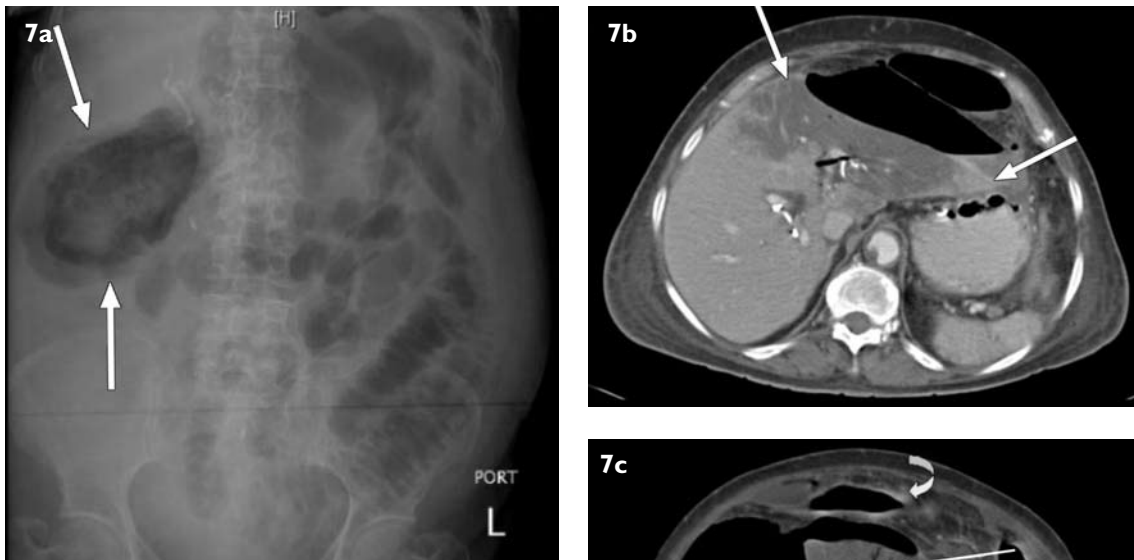


**Fig. 5** A 56-year-old woman presented with vomiting and abdominal distension. (a) Abdominal radiograph shows branching lucencies in the right hypochondrium, in keeping with portal venous gas (arrowheads), with marked dilatation of the stomach and the proximal duodenum. Curvilinear lucencies in the duodenum (arrow) were due to intramural gas. (b) Axial CT image confirms the radiographical findings of portal venous gas (arrow). (c) Axial CT image also shows intramural gas within the duodenal wall (arrows). The transition point was at the level of the third part of the duodenum, between the aorta and the superior mesenteric artery (curved arrow), raising the possibility of superior mesenteric artery syndrome.

liver capsule (Figs. 2a–b). This is because gas in the portal venous system is transported to small peripheral branches by the centrifugal flow of portal venous blood, whereas gas in the biliary tree is prevented from migrating peripherally,



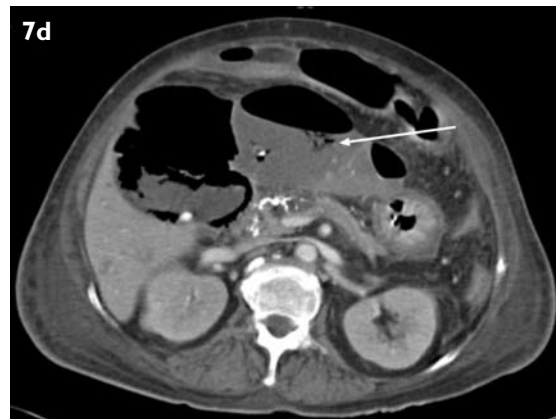**Fig. 6** An example of emphysematous pyelitis in a 45-year-old woman with newly-diagnosed diabetes mellitus, and who presented with abdominal pain. (a) Axial CT image taken in the portal venous phase shows gas in the right pelvicalyceal system (arrow), in keeping with emphysematous pyelitis and a large retroperitoneal abscess (curved arrow). The patient also had portal venous gas (not shown). (b) Axial CT image taken in the delayed phase shows an apparent communication between the second part of the duodenum (arrow), the right renal pelvis and the retroperitoneal abscess collection (curved arrow).



**Fig. 7** An example of emphysematous cholecystitis in a 70-year-old woman who presented with abdominal pain. (a) Abdominal radiograph shows air in the right upper quadrant of the abdomen (arrows), with a globular configuration surrounding a cluster of calcified gallstones, in keeping with emphysematous cholecystitis. (b) Axial CT image shows gas within the hepatic parenchyma, with areas of non-enhancement of the liver (arrows), suggestive of hepatic necrosis. (c & d) Axial CT images show portal venous gas (thin arrows), and confirmed the radiographical findings of emphysematous cholecystitis (solid arrow), with free intraperitoneal air (curved arrow).

by the centripetal flow of bile.<sup>(11)</sup> This is supported by Sisk, who analysed T-tube cholangiograms and found that contrast material did not appear within 2 cm from the liver capsule, compared to all normal portal venograms in which contrast was noted to extend to the liver periphery.<sup>(12)</sup>

The ultrasonographical features of portal venous gas have been described. They appear as echogenic flowing foci within the portal vein or as poorly defined, echogenic patches in the non-dependent portions of the hepatic



parenchyma (i.e. the left lobe and the anterior segment of the right lobe).<sup>(13)</sup> It was previously thought that the presence of portal venous gas signified a grave outcome in both children and adults.<sup>(4)</sup> Liebman et al found a high mortality rate in 75% of patients who had portal venous gas, and advocated urgent surgical exploration for patients with this positive finding.<sup>(4)</sup> The presence of portal venous gas is seen in some children with necrotising enterocolitis, and it usually indicates a more severe disease. This was shown in a study in 2001 comparing the outcome in 40 babies with both necrotising enterocolitis and portal venous air, treated surgically vs. those with medical management. 31 patients who underwent laparotomy had a mortality rate of 55% (17/31). Nine seemingly-stable patients were treated nonoperatively. Six of these nine patients had progressive disease and died before salvage laparotomy could be performed, whereas three (33%) survived without further therapy.<sup>(14)</sup> However, in a study by Faberman and May-Smith, and a literature review based on 182 cases by Kinoshita et al, it was found that the mortality rate of patients who had portal venous gas varied depending on the underlying cause.<sup>(8,15)</sup> The presence of portal venous gas itself was not a predictor of mortality.<sup>(15)</sup>

Based on the literature review by Kinoshita et al, the mortality was high (75%) in patients who had bowel necrosis. However, there were no lethal cases of portal venous gas associated with inflammatory bowel disease (ulcerative colitis or Crohn's disease), fulminant hepatitis, cholangitis, pancreatitis, or portal venous air related to endoscopic procedures. A lower mortality rate was found in portal venous gas related to abscess formation (30%) and gastric ulcer (25%). This resulted in a lower overall mortality rate of 39%, taking into account the large number of patients with portal venous gas with causes other than bowel necrosis.<sup>(15)</sup> Further images show CT examples of HPVG in several patients in our institution, together with their clinical and surgical (if performed) findings. Besides looking for HPVG, it is also important to search for gas in the mesenteric arcades (Figs. 3 & 4) and intramural gas (Fig. 5), which can be subtle and sometimes overlooked. We have also encountered other unusual presentations associated with HPVG, such as emphysematous pyelitis (Fig. 6) and emphysematous cholecystitis with hepatic necrosis (Fig. 7).

The management of portal pyaemia comprises appropriate antibiotics and treatment (resection or drainage) of the primary septic source. The benefits of anticoagulation to reduce mortality have not been proven.<sup>(16)</sup> The complications of portal pyaemia include venous infarction of the bowel (which is the main rationale

for anticoagulation), hepatic abscess formation and portal hypertension.<sup>(17)</sup>

In summary, portal venous gas is a nonspecific radiological sign with a variety of causes. The treatment of patients with portal venous air should be directed to the underlying cause. Conservative management alone for patients with portal venous air associated with stable ulcerative colitis, Crohn's disease or endoscopic procedures was sufficient. The indication for emergent surgical intervention should be based on the underlying cause, bearing in mind the high mortality rate associated with bowel necrosis.

## ABSTRACT

**A 66-year-old man presented with epigastric pain. Computed tomography (CT) of the abdomen showed portal venous gas with partial thrombosis of the portal veins, consistent with portal pyaemia. CT also showed nonspecific peripancreatic fat stranding. The patient was treated conservatively but did not improve, necessitating a laparotomy that revealed ischaemic colitis and bowel necrosis. He underwent a right hemicolectomy and showed clinical improvement. Portal pyaemia is a combination of infection and thrombosis within the portal veins. The presence of gas in the portal vein is a known feature in portal pyaemia. We showed radiological examples of hepatic and portal venous gas in several patients who presented to our institution, with a brief discussion of their radiological findings, causes, management and outcome. The mortality rate of patients with portal venous gas depends on the underlying cause. The high mortality rate of patients with portal venous gas due to bowel necrosis or ischaemia may necessitate emergent surgical intervention.**

**Keywords: bowel ischaemia, hepatic portal venous gas, portal pyaemia, portal pylephlebitis**

*Singapore Med J 2009;50(10):1023-1029*

## REFERENCES

1. Wireko M, Berry PA, Brennan J, Aga R. Unrecognized pylephlebitis causing life-threatening septic shock: a case report. *World J Gastroenterol* 2005; 11:614-5.
2. Kluge S, Hahn KE, Lund CH, Gocht A, Kreymann G. [Pylephlebitis with air in the portal vein system. An unusual focus in a patient with sepsis]. *Dtsch Med Wochenschr* 2003; 128:1391-4. German.
3. Wolfe JN, Evans WA. Gas in the portal veins of the liver in infants: a roentgenographic demonstration with postmortem anatomical correlation. *Am J Roentgenol Radium Ther Nucl Med* 1955; 74:486-9.

4. Liebman PR, Patten MT, Manny J, Benfield JR, Hechtman HB. Hepatic--portal venous gas in adults: etiology, pathophysiology and clinical significance. *Ann Surg* 1978; 187:281-7.
5. Kees CJ, Hester CL Jr. Portal vein gas following barium enema examination. *Radiology* 1972; 102:525-6.
6. Haber I. Hepatic portal vein gas following colonoscopy in ulcerative colitis: report of a case. *Acta Gastroenterol Belg* 1983; 46:14-7.
7. Schulze CG, Blum U, Haag K. Hepatic portal venous gas. Imaging modalities and clinical significance. *Acta Radiol* 1995; 36:377-80.
8. Faberman RS, May-Smith WW. Outcome of 17 patients with portal venous gas detected by CT. *Am J Roentgenol* 1997; 169:1535-8.
9. al-Jahdali, Pon C, Thompson WG, Matzinger FR. Non-fatal portal pyaemia complicating Crohn's disease of the terminal ileum. *Gut* 1994; 35:560-1.
10. Nishimori H, Ezoe E, Ura H, et al. Septic thrombophlebitis of the portal and superior mesenteric veins as a complication of appendicitis: report of a case. *Surg Today* 2004; 34:173-6.
11. Susman N, Senturia HR. Gas embolization of the portal venous system. *Am J Roentgenol Radium Ther Nucl Med* 1960; 83: 847-50.
12. Sisk PB. Gas in the portal venous system. *Radiology* 1961; 77:103-7.
13. Merritt CR, Goldsmith JP, Sharp MJ. Sonographic detection of portal venous gas in infants with necrotizing enterocolitis. *Am J Roentgenol* 1984; 143:1059-62.
14. Molik KA, West KW, Rescorla FJ, et al. Portal venous air: the poor prognosis persists. *J Pediatr Surg* 2001; 36:1143-5.
15. Kinoshita H, Shinozaki M, Tanimura H, et al. Clinical features and management of hepatic portal venous gas: four case reports and cumulative review of the literature. *Arch Surg* 2001; 136:1410-4.
16. Baril N, Wren S, Radin R, Ralls P, Stain S. The role of anticoagulation in pylephlebitis. *Am J Surg* 1996; 172:449-52; discussion 452-3.
17. Wireko M, Berry PA, Brennan J, Aga R. Unrecognized pylephlebitis causing life-threatening septic shock: a case report. *World J Gastroenterol* 2005; 11:614-5.

**SINGAPORE MEDICAL COUNCIL CATEGORY 3B CME PROGRAMME**  
**Multiple Choice Questions (Code SMJ 200910B)**

|   | True                     | False                    |
|---|--------------------------|--------------------------|
| <b>Question 1.</b> The following are known imaging features of portal pyaemia:                              |                          |                          |
| (a) Presence of gas in the portal vein.   | <input type="checkbox"/> | <input type="checkbox"/> |
| (b) Thrombosis of the portal vein.  | <input type="checkbox"/> | <input type="checkbox"/> |
| (c) Echogenic foci in the dependent part of the hepatic parenchyma on ultrasonography.                      | <input type="checkbox"/> | <input type="checkbox"/> |
| (d) It cannot be detected on abdominal radiographs.   | <input type="checkbox"/> | <input type="checkbox"/> |
| <b>Question 2.</b> The following are causes of hepatic portal venous gas:                                   |                          |                          |
| (a) Hepatitis.  | <input type="checkbox"/> | <input type="checkbox"/> |
| (b) Appendicitis.   | <input type="checkbox"/> | <input type="checkbox"/> |
| (c) Colonoscopy.  | <input type="checkbox"/> | <input type="checkbox"/> |
| (d) Haemorrhagic pancreatitis.  | <input type="checkbox"/> | <input type="checkbox"/> |
| <b>Question 3.</b> Regarding portal venous gas:   |                          |                          |
| (a) It can be caused by intraluminal air tracking into the intramural venous plexus through an ulcer.       | <input type="checkbox"/> | <input type="checkbox"/> |
| (b) Branching hypodensities found centrally within the liver is diagnostic of portal venous gas.            | <input type="checkbox"/> | <input type="checkbox"/> |
| (c) If seen in children with necrotising enterocolitis, it indicates less severe disease.                   | <input type="checkbox"/> | <input type="checkbox"/> |
| (d) The commonest cause is ischaemic bowel.   | <input type="checkbox"/> | <input type="checkbox"/> |
| <b>Question 4.</b> Regarding portal pyaemia:  |                          |                          |
| (a) CT is the most sensitive modality to detect portal venous gas.  | <input type="checkbox"/> | <input type="checkbox"/> |
| (b) It can be diagnosed on ultrasonography.   | <input type="checkbox"/> | <input type="checkbox"/> |
| (c) The presence of portal venous gas is inevitably a predictor of mortality and signifies a grave outcome. | <input type="checkbox"/> | <input type="checkbox"/> |
| (d) The mortality rate of patients with portal venous gas is independent of the underlying cause.           | <input type="checkbox"/> | <input type="checkbox"/> |
| <b>Question 5.</b> The following statements are true:   |                          |                          |
| (a) Portal pyaemia is defined as the combination of infection and thrombosis within the portal veins.       | <input type="checkbox"/> | <input type="checkbox"/> |
| (b) Portal pyaemia can only be treated surgically.  | <input type="checkbox"/> | <input type="checkbox"/> |
| (c) Portal pyaemia can be complicated by venous infarction of the bowel.                                    | <input type="checkbox"/> | <input type="checkbox"/> |
| (d) Portal venous gas was first described in infants with necrotising enterocolitis.                        | <input type="checkbox"/> | <input type="checkbox"/> |

**Doctor's particulars:**

Name in full: \_\_\_\_\_

MCR number: \_\_\_\_\_ Specialty: \_\_\_\_\_

Email address: \_\_\_\_\_

**SUBMISSION INSTRUCTIONS:**

(1) Log on at the SMJ website: <http://www.sma.org.sg/cme/smj> and select the appropriate set of questions. (2) Select your answers and provide your name, email address and MCR number. Click on "Submit answers" to submit.

**RESULTS:**

(1) Answers will be published in the SMJ December 2009 issue. (2) The MCR numbers of successful candidates will be posted online at [www.sma.org.sg/cme/smj](http://www.sma.org.sg/cme/smj) by 15 December 2009. (3) All online submissions will receive an automatic email acknowledgment. (4) Passing mark is 60%. No mark will be deducted for incorrect answers. (5) The SMJ editorial office will submit the list of successful candidates to the Singapore Medical Council.

**Deadline for submission: (October 2009 SMJ 3B CME programme): 12 noon, 1 December 2009.**