

# Multiple epidermal cysts occurring in a tattoo

Koh M J A, Teo R Y L, Liu T T

## ABSTRACT

In decorative tattooing, pigment is introduced into the skin with needles or a tattoo gun to create a picture, motif or symbol. Various skin reactions have been reported in association with tattoos. These include acute inflammatory reactions, eczematous hypersensitivity reactions, pseudolymphomatous reactions and skin infections. We present a 24-year-old Malay man who developed multiple epidermal cysts a month after tattooing. To the best of our knowledge, this is the first case in the literature of epidermal cysts occurring after skin tattooing.

**Keywords:** epidermal cyst, milia, skin reaction, tattoo

*Singapore Med J 2009;50(11):e376-e377*

## INTRODUCTION

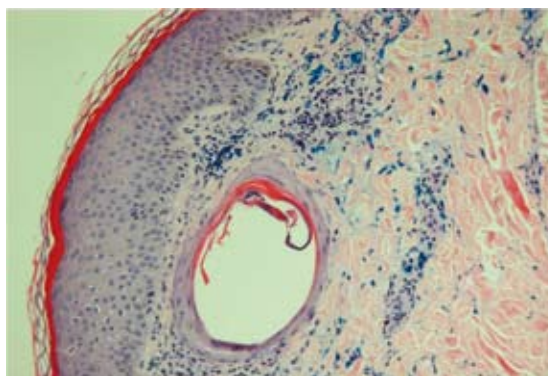
Tattoos have become increasingly popular in today's society, particularly among young people. As such, there has been an increasing number of reports of various skin reactions in association with tattoos. These include acute inflammatory reactions, eczematous hypersensitivity reactions, pseudolymphomatous reactions and skin infections. We report a unique case of a 24-year-old man who developed multiple epidermal cysts a month after tattooing.

## CASE REPORT

A 24-year-old Malay man presented with a mildly pruritic rash that developed over his left forearm tattoo. He had obtained the initial black outline of the tattoo three years prior to consultation. Red, blue and green colourings were added one month before the lesions had appeared. He had been treated with topical steroids for the rash by his general practitioner, with no response. He has another tattoo containing black and red pigments over his right forearm, done years earlier by a different tattoo artist, but he had no lesions over it. Physical examination (Figs. 1a–b) showed multiple pin-point white papules over the green, black and blue areas of the tattoo on the left forearm. The skin overlying the non-tattooed areas of the left forearm was normal.



**Fig. 1** Photograph shows multiple small white papules overlying the tattoo on the left forearm.



**Fig. 2** Photomicrograph shows a small epidermoid inclusion cyst within the dermis (Haematoxylin & eosin, × 10).

A skin biopsy (Fig. 2) was performed from a papule on the left forearm. Histopathology showed a mildly acanthotic and hyperkeratotic epidermis with a small epidermoid inclusion cyst in the dermis. The wall was lined by keratinising squamous epithelium with small amounts of keratin flakes and blue pigment-filled macrophages within. Infiltrates of lymphocytes and histiocytes were present in the superficial dermis. A diagnosis of multiple epidermal cysts secondary to trauma from the tattoo process was made. He was given 10% urea cream and 2% salicylic acid, with mild improvement of the lesions.

## DISCUSSION

In decorative tattooing, pigment is introduced into the skin with needles or a tattoo gun to create a picture,

Department of  
Dermatology,  
Changi General  
Hospital,  
2 Simei Street 3,  
Singapore 529889

Koh MJA, MBBS,  
MRCPCH  
Registrar

Teo RYL, MBBS,  
MMed, MRCP  
Associate Consultant

Liu TT, MBBS,  
MMed, FAMS  
Senior Consultant

**Correspondence to:**  
Dr Mark Jean An Koh  
Tel: (65) 9689 2431  
Fax: (65) 6447 8671  
Email: mark\_koh@cgh.  
com.sg

motif or symbol. Various skin reactions have been reported in association with tattoos. These include: (1) Acute inflammatory reactions, an expected adverse effect which occurs as a result of direct tissue injury, and usually recedes within two to three weeks. (2) Eczematous hypersensitivity reactions may be spongiotic, granulomatous or lichenoid. Red mercuric-based ink has most commonly been associated with this. Laser removal of such tattoos runs a theoretical risk of inducing a systemic allergic reaction.<sup>(1)</sup> Cases of granulomatous hypersensitivity reactions need to be differentiated from the Koebner response occurring in sarcoidosis, as localised hypersensitivity reactions to tattoos have been reported as the presenting feature in systemic sarcoidosis.<sup>(2)</sup> (3) Pseudolymphomatous reaction, which is a rare tattoo reaction that has been reported to occur in the red areas of the tattoo.<sup>(3,4)</sup> Clinically, these present with flesh- to plum-coloured nodules and plaques that may be erroneously diagnosed as cutaneous lymphoma. Histopathology and immunohistochemistry may help to distinguish the two. (4) Skin infections, like common warts,<sup>(5)</sup> tuberculosis cutis<sup>(6)</sup> and zygomycosis,<sup>(7)</sup> have been reported after tattoo applications.

Epidermal cysts are the most common cutaneous cysts and are derived from the follicular infundibulum. They can occur anywhere on the skin, but are most common on the face and upper trunk. They can range from a few millimetres to several centimetres in diameter. Tiny superficial epidermal cysts are known as milia. Epidermal cysts may be primary or may arise from disrupted follicular structures or traumatically-implanted epithelium. The occurrence of epidermal cysts has been reported following trauma,<sup>(8)</sup> radiotherapy,<sup>(9)</sup> and after surgical procedures, such as needle biopsy.<sup>(10)</sup> To the best of our knowledge, this is the first case reported in the literature of epidermal cysts occurring after a tattooing process. During tattooing, the introduction of pigment

into the skin may cause disruption of the epithelium, leading to the occurrence of these cysts.

Larger epidermal cysts are removed by simple excision, or incision and expression of the cyst contents together with the wall. For multiple small epidermal cysts or milia, the use of laser ablation<sup>(11)</sup> or electrodesiccation<sup>(12)</sup> has been reported to be useful. Topical retinoid therapy has also been reported to be helpful in reducing the size and number of milia.<sup>(13)</sup>

## REFERENCES

1. Ashinoff R, Levine VJ, Soter NA. Allergic reactions to tattoo pigment after laser treatment. *Dermatol Surg* 1995;21:291-4.
2. Sowden JM, Cartwright PH, Smith AG, Hiley C, Slater DN. Sarcoidosis presenting with a granulomatous reaction confined to red tattoos. *Clin Exp Dermatol* 1992; 17:446-8.
3. Kahofer P, El Shabrawi-Caelen L, Horn M, Kern T, Smolle J. Pseudolymphoma occurring in a tattoo. *Eur J Dermatol* 2003; 13:209-12.
4. Blumental G, Okun MR, Ponitch JA. Pseudolymphomatous reaction to tattoos. Report of three cases. *J Am Acad Dermatol* 1982; 6:485-8.
5. Ragland HP, Hubbell C, Stewart KR, Nesbitt LT Jr. *Verruca vulgaris* inoculated during tattoo placement. *Int J Dermatol* 1994; 33:796-7.
6. Wong HW, Tay YK, Sim CS. Papular eruption on a tattoo: a case of primary inoculation tuberculosis. *Australas J Dermatol* 2005; 46:84-7.
7. Parker C, Kaminski G, Hill D. Zygomycosis in a tattoo, caused by *Saksenaea vasiformis*. *Australas J Dermatol* 1986; 27:107-11.
8. Hall JP, Sheffey RJ, Chagares WE, Yong RM. Epidermal inclusion cyst in the foot of a Vietnam veteran. *J Am Podiatr Med Assoc* 2006; 96:445-7.
9. Lee A, Griffiths WA. Multiple milia due to radiotherapy. *J Dermatolog Treat* 2002; 13:147-9.
10. Davies JD, Nonni A, D'Costa HF. Mammary epidermoid inclusion cysts after wide-core needle biopsies. *Histopathology* 1997; 31:549-51.
11. Dmovsek-Olup B, Vedlin B. Use of Er:YAG laser for benign skin disorders. *Lasers Surg Med* 1997; 21:13-9.
12. Al-Mutairi N, Joshi A. Bilateral extensive periorbital milia en plaque treated with electrodesiccation. *J Cutan Med Surg* 2006; 10:193-6.
13. Connelly T. Eruptive milia and rapid response to topical tretinoin. *Arch Dermatol* 2008; 144:816-7.