

PET-CT as an effective imaging modality in the staging and follow-up of post-transplant lymphoproliferative disorder following solid organ transplantation

Department of Diagnostic Imaging, Serdang Hospital, Jalan Puchong, Serdang 43000, Malaysia

Noraini A R, Gay E, Ferrara C, Ravelli E, Mancini V, Morra E, Muti P, Tahir A, Abdul Jalil N, Rossetti C

Noraini AR, MD
Consultant

Abdul Jalil N, MD
Consultant

Department of Nuclear Medicine, Ospedale Niguarda, Ca' Granda Piazza Ospedale Maggiore 3, Milan 20162, Italy

Gay E, MD
Consultant

Ferrara C, MD
Consultant

Rossetti C, MD
Director

Department of Pathology and Haematology

Ravelli E, MD
Consultant
Haematologist

Mancini V, MD
Consultant
Haematologist

Morra E, MD
Director

Muti P, MD
Consultant
Haematologist

Division of Health Care Services Research, Institute for Health System Research, Ministry of Health Malaysia, Jalan Rumah Sakit Bangsar, Kuala Lumpur 59000, Malaysia

Tahir A, MD
Head

Correspondence to:
Dr Noraini Abdul Rahim
Tel: (60) 3 8947 5555
Fax: (60) 3 8947 5322
Email: norainichoo2@hotmail.com

ABSTRACT

Introduction: To establish the role of positron-emission tomography (PET)-computed tomography (CT) in post-transplant lymphoproliferative disorder (PTLD) patients, compared to conventional imaging (ultrasonography/CT/magnetic resonance imaging) in relation to its accuracy, sensitivity and specificity.

Methods: 30 patients (26 males and 4 females), with a median age of 49.5 (range 18–74) years, were retrospectively evaluated. In 29 cases, the diagnosis was confirmed by histopathology. Malignant lymphoma was detected in 20 cases, polymorphic lymphoproliferative disorder in six cases, multiple myeloma in two cases and Hodgkin's disease in one case. A total of 49 PET-CTs (13 studies for staging at diagnosis and 36 studies at follow-up as assessment post-therapy) were compared to conventional imaging. Imaging results in accordance with disease status were assessed at a median follow-up of 17.8 (range 1.5–42.2) months post-PET-CT.

Results: In 41 of 49 examinations performed for staging and on follow-up, PET-CT and conventional imaging findings were concordant. Compared to conventional imaging, PET-CT showed comparable sensitivity (75 percent vs. 83 percent), similar specificity (100 percent in both modalities) and comparable accuracy (77 percent vs. 85 percent) during staging at diagnosis. PET-CT was found to be superior to conventional imaging modalities at follow-up, with greater sensitivity (100 percent vs. 81 percent), specificity (80 percent vs. 100 percent)

and accuracy (97 percent vs. 83 percent).

Conclusion: PET-CT is an accurate diagnostic tool for staging and for the follow-up of PTLD patients. It represents a good alternative imaging method to avoid contrast-related nephrotoxicity in patients who often develop impaired renal function secondary to chronic immunosuppressive therapy. However, further studies are recommended before considering PET-CT as a routine diagnostic tool in PTLD.

Keywords: computed tomography, positron-emission tomography, post-transplant lymphoproliferative disorder, solid organ transplant, transplant complications

Singapore Med J 2009;50(12):1189-1195

INTRODUCTION

Post-transplant lymphoproliferative disorder (PTLD) is a well-recognised complication which develops as a result of chronic immunosuppression following organ transplantation. It develops in the post-transplant patient, depending on the organ transplanted and the type and length of immunosuppressive therapy. Its aetiology is related to Epstein-Barr virus (EBV)-induced B-lymphocyte proliferation in an impaired immune surveillance caused by the pharmacological suppression of EBV-specific T-cells. The histology and clinical course of PTLD are heterogeneous, including benign polyclonal lymphocyte proliferations and malignant monoclonal forms. According to the World Health Organization, PTLDs are classified into three main categories, viz. early lesion (inclusive of mononucleosis-like infection and plasmacytic hyperplasia), polymorphic PTLD (polyclonal or monoclonal) and monomorphic PTLD (malignant lymphoma, plasmocytoma-like lesions and

Hodgkin's lymphoma).⁽¹⁾

The clinical presentation is not specific, and almost any organ can be affected. The disease may involve the lymph nodes or may be extranodal, limited to the allograft or widely disseminated. Transplant recipients are basically frail patients because of their long history of organ failure that has resulted in transplantation. Moreover, they are all immunosuppressed and heavily-treated patients, so pharmacological toxicities (mainly nephrotoxicity) often affect their organ function. Therefore, being critically-ill at diagnosis is a commonly-encountered problem for PTLD patients, who often present with severe constitutional symptoms (fever, malaise, infectious mononucleosis-like syndrome) and symptoms relating to solid or hollow organ dysfunction.

Treatment options for such patients include reduction of immunosuppression, antiviral treatment to control viral replication, chemotherapy, radiotherapy, immunotherapy and surgery. Early diagnosis is associated with a better prognosis and disease extent is an important prognostic factor that may affect therapy. Tissue biopsy is always necessary to confirm the diagnosis, but it is evident that timely availability of an accurate, immediate and easily feasible imaging method is critical in the diagnostic phase and at staging of PTLDs. High-sensitivity imaging techniques are required for the optimal management of these patients and play an important role in assessing the response to therapy, which then leads to the appropriate therapeutic approach.

In contrast to the available data for different types of lymphomas, there is no standardised imaging approach to assess tumour location, morphology and follow-up of PTLDs yet. In most centres, computed tomography (CT) is currently the imaging modality of choice. Additional imaging investigations, such as magnetic resonance (MR) imaging and bone scintigraphy, are helpful in evaluating extranodal disease sites, such as bones, spine, brain and intra-abdominal solid organs. Recently, positron-emission tomography (PET) is being extensively employed as a standard additional diagnostic test in the management of most subtypes of lymphomas. The use of PET-CT imaging in the evaluation of PTLD has been documented. However, to the best of our knowledge, the description of PET-CT usage for staging and monitoring therapy has previously been limited to smaller patient series or confined to single-organ transplants. In order to establish the role of PET-CT in staging and follow-up of PTLD, we describe our experience on 30 cases of PTLD which were on regular follow-up. A total of 49 PET-

CTs were performed at the same time as conventional imaging (ultrasonography [US]/CT/MR imaging), either for staging or assessment of response to therapy.

METHODS

Our study population included 30 patients with a diagnosis of PTLD in solid organ transplant recipients (14 liver, 12 heart, three kidney and one lung) at Niguarda Hospital, Milan, Italy. Of these 30 patients, 26 were males and four were females, with a median age at presentation of 49.5 (range 18–74) years. All recruited patients, either at their diagnostic phase or during the post-treatment follow-up, had a PET-CT study done between April 2003 and September 2006, and underwent staging analysis, including standard conventional imaging techniques (CT or MR imaging) and tissue or bone marrow biopsy. After having completed their treatment, they underwent a repeat conventional imaging and PET-CT examination at follow-up to evaluate disease response and for disease monitoring after therapy. A total of 49 PET-CT scans were performed in our PTLD patients, either at diagnosis (13 examinations) or during assessment post-treatment/follow-up (36 examinations). Their results were compared with conventional imaging findings (US/CT/MR imaging) performed at about the same time and then verified with the clinical disease status assessed by haematologists.

PET-CT was performed using an integrated Biograph PET-CT system (Siemens AG, Erlangen, Germany) that combined dual-slice spiral CT with a dedicated full-ring bismuth germanate crystal PET scanner. CT image acquisition was accomplished without intravenous contrast administration. The following protocol was used. CT scanogram was performed to plan the CT and PET study. Low-dose CT acquisition was performed with parameters of 2.5-mm slices, spiral mode at 50 mAs and 130 kV without administration of intravenous contrast agent, as CT was performed for anatomical correlation and attenuation correction for PET images. Immediately after CT image acquisition, the table was positioned for PET image acquisition (5 min/bed position), 60 minutes after 18F-fluoro-2-deoxyglucose (FDG) injection in the range of 7–9 mCi after overnight fasting. Acquisition was performed from the lung to the thighs in three-dimensional mode. Reconstruction of the emission data was performed by using an iterative algorithm with the software Somaris/5 VA40C (Siemens AG, Erlangen, Germany) and stored in a 128 matrix (FWHM 5 mm, Zoom 1, pixel size 5.1, scatter correction). CT data was used for attenuation correction. Volume projected images (transaxial, coronal and sagittal slices) and fusion images were generated for interpretation.

Table I. SUV_{max} of the most active lesion in staging at diagnosis and at follow-up, in comparison to the disease status in eight patients.

Patient no.	SUV _{max} in staging at diagnosis	SUV _{max} at follow-up	PTLD persistence*	Patient outcome
1.	19.17	14.42	Yes	Died
2.	3.41	Negative	No	Alive
3.	5.74	Negative	No	Alive
4.	9.37	Negative	No	Alive
5.	5.39	Negative	No	Alive
6.	6.60	4.53	Yes	Died
7.	13.96	Negative	No	Alive
8.	5.81	Negative	No	Alive

PTLD: post-transplant lymphoproliferative disorder

* Clinical disease status

The results from the 49 PET-CTs done for staging and follow-up assessment were compared with that of conventional imaging reports obtained via the hospital information system in terms of the number, size and sites of lesions detected. The study reports chosen for comparison were those done at the same time or at the nearest date. The consultant radiologist and nuclear medicine specialists retrospectively reviewed the PET, CT component of the PET-CT and fusion images of the selected cases, respectively. Agreement was reached by consensus. All PET-CT studies were interpreted in a non-blinded manner. The clinical data were provided by the haematologists. All imaging results performed for staging (both conventional imaging and PET-CT) were correlated to the histological findings in order to complete the diagnosis and look for histological subtypes. Imaging results obtained from the repeat examinations (both conventional imaging and PET-CT) during follow-up were compared to the disease status provided by the haematologists. The median clinical follow-up post-PET-CT was 17.8 months (range 1.5–42.2) months. The purpose of the follow-up post-PET-CT was to verify if patients who had negative findings maintained free from clinical signs of disease.

The results were tabulated and analysed via sensitivity and specificity analysis by a statistician. The standardised uptake value (SUV) calculation was made on every patient, and a reading of at least one lesion with SUV_{max} above 2.5 in the diagnosis and follow-up finding was considered positive. This was because we considered that the conventional and PET-CT imaging appearance of PTLD could not be distinguished from lymphoma, a malignant lesion. (SUV_{max} 2.5 was utilised as the cut-off point as recommended by a meta-analysis study from University of Tennessee, Knoxville, Tennessee, where factors influencing the value were standardised, where

applicable. SUV_{max} of 2.5 was found to be appropriate for separating certain benign and malignant lesions). The SUV_{max} results of the patients who had positive PET-CT during staging and had follow-up PET-CT available (eight patients), were compared to the disease status ascertained by haematologists and tabulated in Table I. The sensitivity, specificity and accuracy of each imaging modality were calculated (Tables II and III).

RESULTS

In 29 of 30 cases, the diagnosis was confirmed by histopathological analysis, but it was not possible to assign one case to any histological category because of inadequate specimens. We identified 20 cases of malignant lymphoma, six polymorphic lymphoproliferative disorders, two multiple myeloma, and one case of Hodgkin's disease. All lesions identified in these cases demonstrated increased metabolic activity on PET imaging with visual increased FDG uptake. These findings were further confirmed by semiquantitative assessments using SUV_{max} with values above 2.5. There were two statistical analyses done on the results obtained in our study, i.e. during staging at diagnosis and in the post-treatment follow-up study.

In staging, both conventional and PET-CT imaging results were compared with the gold standard, which was the histopathological biopsy report. The sensitivity, specificity and accuracy derived are tabulated in Table II. During staging at diagnosis, the conventional imaging modalities were found to be more sensitive and more accurate than PET-CT in detecting PTLD. In addition, both techniques were found to be equally specific in detecting PTLD, especially if the results were positive. However, our study showed they were poor at predicting the status of the disease when the results were found to be negative. The second statistical analysis involved the results obtained during post-treatment follow-up. The imaging results were compared with the clinical disease status, which were verified by the haematologists. PET-CT was found to be superior to conventional imaging modalities at follow-up. The latter was also found to be poor at predicting the status of the disease when the results were found to be negative (Table III).

In addition, we tabulated the highest recordable SUV_{max} of eight patients who had positive PET-CT findings during staging at diagnosis and had available follow-up PET-CT study (Table I). Their SUV_{max} at staging and follow-up were observed and compared with the clinical outcome. Two patients had died, while the remaining six patients are still alive. Only eight patients underwent both examinations, i.e. positive reading on PET-CT during

Table II. Comparison between conventional imaging modalities and PET-CT in staging at diagnosis of post-transplant lymphoproliferative disorder.

No. of examinations	TP	TN	FP	FN	Sensitivity (%)	Specificity (%)	PPV (%)	NPV (%)	Accuracy (%)
PET-CT	9	1	0	3	75	100	100	25	77
CI	10	1	0	2	83	100	100	33	85

PET-CT: positron-emission tomography-computed tomography; CI: conventional imaging; TP: true-positive; TN: true-negative; FP: false-positive; FN: false-negative; PPV: positive predictive value; NPV: negative predictive value

Table III. Comparison between conventional imaging modalities and PET-CT at the post-treatment follow-up of post-transplant lymphoproliferative disorder.

No. of examinations	TP	TN	FP	FN	Sensitivity (%)	Specificity (%)	PPV (%)	NPV (%)	Accuracy (%)
PET-CT	31	4	1	0	100	80	97	100	97
CI	25	5	0	6	81	100	100	45	83

PET-CT: positron-emission tomography-computed tomography; CI: conventional imaging; TP: true-positive; TN: true-negative; FP: false-positive; FN: false-negative; PPV: positive predictive value; NPV: negative predictive value

staging at diagnosis and follow-up PET-CT, while the rest of the patients either had negative reading during staging at diagnosis or did not have follow-up PET-CT available. Lymph node enlargement involved the cervical, axillae, thorax and abdominopelvic region. The extranodal sites included the lung parenchyma, stomach, liver and spine.

DISCUSSION

PTLD is a well-recognised complication of organ transplantation and was first reported in 1969.⁽²⁾ PTLD can affect nearly any organ system, and the disease entity has a wide spectrum of clinical and pathological appearances. Patients may present with symptoms ranging from benign infection resembling mononucleosis to that of aggressive lymphoma. PTLDs are different from lymphoproliferative disorders that occur in the general population.^(3,4) The most striking distinction is the relatively high frequency of extranodal disease and the lower frequency of nodal disease in patients with PTLD. The imaging goals for patients with PTLD are to detect disease, guide biopsy and direct appropriate follow-up imaging rather than to establish a specific diagnosis. The case illustrated in Fig. 1 shows a good example of PET-CT playing a role in evaluating the staging and response to therapy of these malignancies.

PTLD involving abdominal organs accounts for over half of the cases, with the liver being the most frequently-involved organ. In decreasing order of incidence, they are: focal/deposits and diffuse infiltration or periportal soft tissue disease. To the best of our knowledge, this unique feature of periportal lymphomatous infiltration, seen only on CT of liver transplant recipients, has not been described in non-immunocompromised patients.⁽⁵⁾

We had a patient, a 52-year-old man, who developed multifocal lesions with periportal infiltration in a transplanted liver and was diagnosed as PTLD (diffuse non-Hodgkin lymphoma type) six months post-transplant due to hepatocellular carcinoma.

PTLD affecting the lungs is more commonly found following lung transplantation than of other organs, mostly within a year of transplantation.⁽⁶⁾ The typical appearance that have been described are multiple pulmonary nodules with a peripheral and basal predominance, occasionally with a surrounding halo of ground glass opacity. Other patterns include air space consolidation, mediastinal and hilar lymphadenopathy, pleural or chest wall masses, pericardial or pleural effusions and thymic enlargement.^(7,8) These nodules will demonstrate increased FDG activities with the SUV within the range of malignancy. In our study, one of the patients with lung involvement, a 55-year-old man, developed multifocal lung lesions in both lung fields six years after a heart transplant. He was diagnosed as PTLD (peripheral non-Hodgkin's lymphoma). PET-CT was performed one month after the conventional imaging at its diagnostic stage, which revealed more lung nodules, and in addition, demonstrated associated cervical lymph nodes in the same study, which was not shown in the earlier CT of the thorax. Thus, PET-CT helped to stage the disease more accurately in this case.

Although the CT appearance of the central nervous system and both head and neck manifestations of the PTLD have been described,⁽⁹⁾ to our knowledge, no PET-CT appearance from spine involvement in PTLD has been reported so far. Zamagni et al compared the 18F-FDG PET-CT, MR imaging and whole body planar

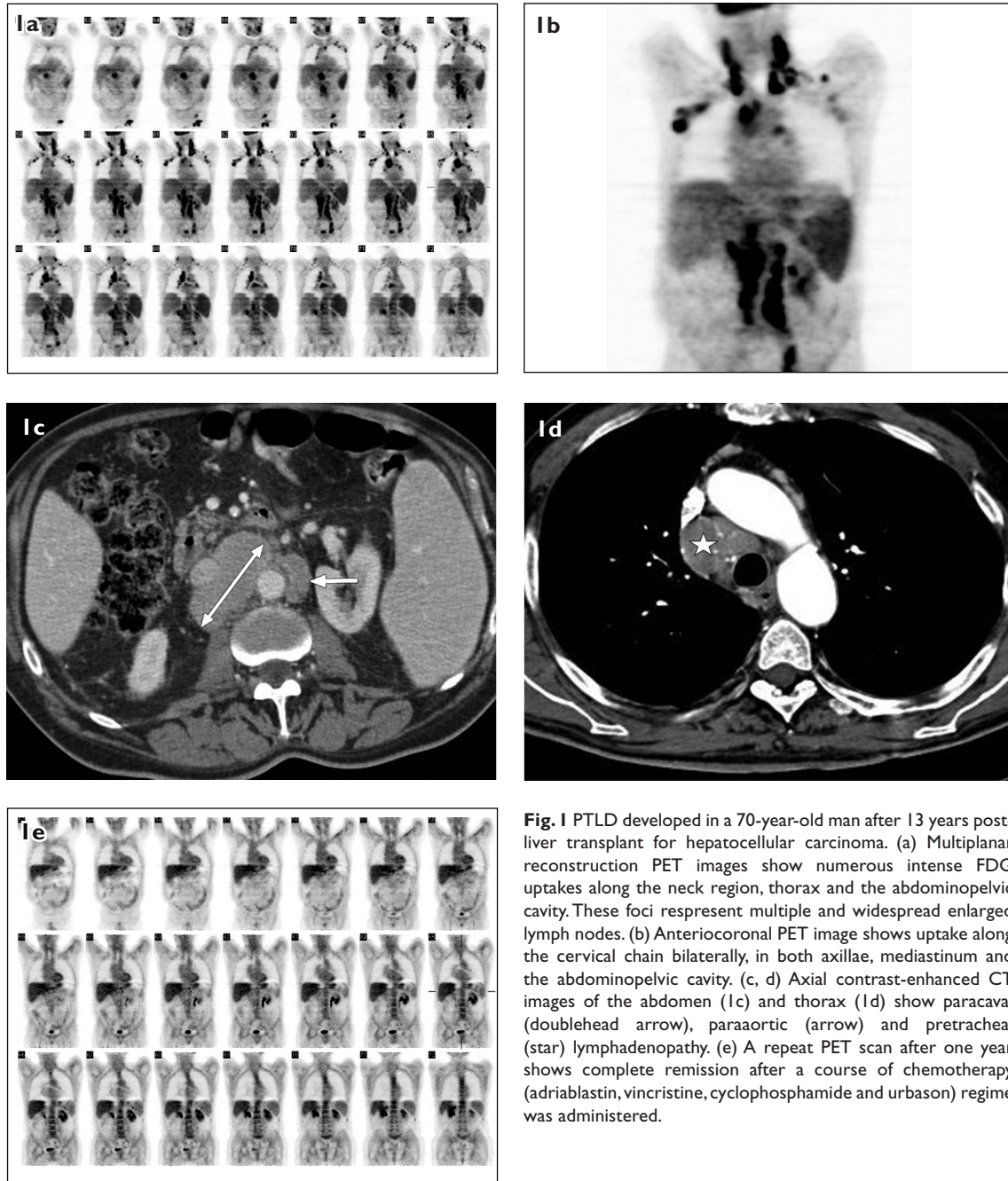


Fig. 1 PTLD developed in a 70-year-old man after 13 years post-liver transplant for hepatocellular carcinoma. (a) Multiplanar reconstruction PET images show numerous intense FDG uptakes along the neck region, thorax and the abdominopelvic cavity. These foci represent multiple and widespread enlarged lymph nodes. (b) Anteriacoronal PET image shows uptake along the cervical chain bilaterally, in both axillae, mediastinum and the abdominopelvic cavity. (c, d) Axial contrast-enhanced CT images of the abdomen (1c) and thorax (1d) show paracaval (doublehead arrow), paraaortic (arrow) and pretracheal (star) lymphadenopathy. (e) A repeat PET scan after one year shows complete remission after a course of chemotherapy (adriablastin, vincristine, cyclophosphamide and urbason) regime was administered.

radiographs in the assessment of bone disease in newly-diagnosed multiple myeloma, and revealed that in 30% of patients, PET-CT of the spine and pelvis failed to show abnormal findings in areas where MR imaging revealed an abnormal pattern of bone marrow involvement, more frequently of a diffuse type. By combining MR imaging of the spine and pelvis and ^{18}F -FDG PET-CT, the ability to detect sites of active multiple myeloma, both medullary and extramedullary, can be as high as 92%.⁽¹⁰⁾ Our study supports this observation when one of our patients with a histological diagnosis of diffuse large cell non-Hodgkin's lymphoma type had a lesion in the L1 vertebra body detected by PET-CT. MR imaging performed two weeks

later demonstrated more sites involved, including the T11 and L3 vertebrae. All these lesions appeared hyperintense on T2 images and enhanced post-gadolinium, indicating disease infiltration or involvement. In addition, MR imaging also showed degenerative changes in the end-plates of the L5 vertebra.

Although contrast-enhanced CT (CECT) is currently the first-line imaging modality in the assessment of Hodgkin's disease and non-Hodgkin's lymphoma, recent studies suggest that PET is more accurate for staging and follow-up.⁽¹¹⁾ It is quickly becoming a standard additional diagnostic test in lymphoma and has proven to be more accurate than CT alone in the evaluation of Hodgkin's

disease and high-grade non-Hodgkin's lymphoma. The value of PET-CT in low-grade non-Hodgkin's lymphoma and PTLT, however, remains unclear. In a limited post-renal transplant study series by O'Conner et al, FDG PET was found to be an effective imaging modality in the staging and follow-up of PTLT.⁽¹²⁾

We also evaluated PET-CT findings in the different histopathological forms of PTLT (malignant lymphoma vs. polymorphic lymphoproliferative disease vs. Hodgkin's disease; or monoclonal [24 cases] vs. polyclonal [four cases]), where we noted that the effectiveness of PET-CT for different subtypes may significantly differ, as in lymphomas.⁽¹³⁾ Although the general belief that the overall ability of FDG-PET to stage patients with polyclonal disease could be limited, all four of our polyclonal patients who were diagnosed to have a negative study at follow-up PET-CT continued their clinical follow-up for a period of time. All of them were proven disease-free. With this understanding, we hope to further our study in order to establish the relationship between the PET-CT findings and PTLT subtypes.

Besides several advantages of PET over conventional imaging, the major advantage was its ability to detect disease in the absence of morphological abnormalities (e.g. normal-size lymph nodes with tumour involvement) and to distinguish benign from malignant enlargements in lymph nodes and other tissues. Furthermore, CECT may also fail to assess tumour response after treatment, as fibrotic tissue cannot be distinguished from viable tumour. This is the main reason why in follow-up, PET-CT is more reliable compared to conventional imaging. Our results in Table III show that the p-value for the sensitivity, specificity and accuracy tests obtained from PET-CT findings in follow-up, was statistically significant; being 0.000005, 0.00002 and 0.0098, respectively.

There is also an advantage of doing a PET-CT study rather than a CECT study in post-transplant patients. Contrast media-induced nephropathy (CIN) leading to acute renal failure is a rare event in the general population, and it is associated with exposure to iodinated contrast agents (defined as > 25% increase in serum creatinine levels over the baseline in the first five days). However, because of the increased utilisation of procedures that use iodinated contrast agents, particularly diagnostic CT, CIN has become one of the leading causes of hospital-acquired acute renal failure, accounting for 12% of all cases.⁽¹⁴⁾ Patients with the highest risk of developing CIN are those with preexisting renal insufficiency or chronic kidney disease, diabetes mellitus and those with a high-contrast volume administered, where the rates of incidence are higher. Renal impairment is a known risk in

PTLT patients receiving chemotherapy.

In addition to our experience in imaging these patients as described above, we observed the potential of PET-CT in predicting disease outcome (Table I). We found that at follow-up, two patients with a SUV_{max} value above 4 (Patients 1 and 6) represented severe disease activity that affected their clinical outcome, as both had died, whereas six patients with negative readings in the follow-up PET-CT accurately corresponded with the disease status verified by the haematologist, i.e. they were disease-free on clinical follow-up and are still alive to date. Thus, SUV_{max} readings from PET-CT can provide a predictive value on patient prognosis.

In conclusion, this study suggests that PET-CT is an accurate diagnostic tool in the staging and follow-up of PTLT patients. However, reconfirmation with the histology of all positive findings remains mandatory. PET-CT is also a useful modality in patients with impaired renal function due to chronic immunosuppressive treatment. As no contrast agent is used, contrast-related nephrotoxicity is avoided in PTLT patients. MR imaging remains the gold standard for the diagnosis, especially for infiltrative pattern of spinal involvement in PTLT. Therefore, MR imaging of the spine should be included for all patients with suspected spine involvement. The limitation of this present study was the small study population. Further studies with larger sample sizes are needed to statistically confirm our results before PET-CT can be implemented as a routine diagnostic tool in suspected cases of PTLT following solid organ transplantation.

REFERENCES

1. World Health Organization. Classification of tumours. In: Jaffe ES, Harris NL, Stein H, Vardiman JW, eds. Pathology and Genetics of Tumors of Haematopoietic and Lymphoid Tissues. Lyon: IARC Press, 2001:1221-43.
2. Penn I, Hammond W, Brettschneider L, Starzl TE. Malignant lymphomas in transplantation patients. *Transplant Proc* 1969; 1:106-12.
3. Ranganathan S, Jaffe R. Is there a difference between Hodgkin's disease and a Hodgkin's-like post-transplant lymphoproliferative disorder, and why should that be of any interest? *Pediatric Transplantation* 2004; 8:6-8.
4. Dharnidharka VR, Douglas-Nikitin V. Hodgkin's-like PTLT versus true Hodgkin's disease. *Pediatric Transplantation* 2004; 8:581-2.
5. Pickhardt PJ, Siegel MJ. Posttransplantation lymphoproliferative disorder of the abdomen: CT evaluation in 51 patients. *Radiology* 1999; 213:73-8.
6. Marom EM, McAdams HP, Butnor KJ, Coleman RE. Positron emission tomography with fluoro-2-deoxy-D-glucose (FDG-PET) in the staging of post transplant lymphoproliferative disorder in lung transplant recipients. *J Thorac Imaging* 2004; 19:74-8.
7. Carignan S, Staples CA, Müller NL. Intrathoracic lymphoproliferative disorders in the immunocompromised patient: CT findings. *Radiology* 1995; 197:53-8.

8. Dodd GD 3rd, Ledesma-Medina J, Baron RL, Fuhrman CR. Posttransplant lymphoproliferative disorder: intrathoracic manifestations. *Radiology* 1992; 184:65-9.
9. Scarsbrook AF, Warakaulle DR, Dattani M, Traill Z. Post-transplantation lymphoproliferative disorder: the spectrum of imaging appearances. *Clin Radiol* 2005; 60: 47-55.
10. Zamagni E, Nanni C, Patriarca F, et al. A prospective comparison of 18F-fluorodeoxyglucose positron emission tomography-computed tomography, magnetic resonance imaging and whole-body planar radiographs in the assessment of bone disease in newly diagnosed multiple myeloma. *Haematologica* 2007; 92:50-5.
11. McCormack L, Hany TI, Hubner M, et al. How useful is PET/CT imaging in the management of post-transplant lymphoproliferative disease after liver transplantation? *Am J Transplant* 2006; 6:1731- 6.
12. O'Conner AR, Franc BL. FDG PET imaging in the evaluation of post-transplant lymphoproliferative disorder following renal transplantation. *Nucl Med Commun* 2005; 26:1107-11.
13. Elstrom R, Guan L, Baker G, et al. Utility of FDG-PET scanning in lymphoma by WHO Classification. *Blood* 2003; 101:3875-6.
14. Miller JC. Contrast-media induced nephropathy and diagnostic CT. *Radiology Rounds* 2007; 5.

Singapore Medical Journal Honour Roll of Editors

<i>Honorary Editor</i>	<i>Term of Service</i>
<i>Dr Gwee Ah Leng</i>	<i>1960 - 1971</i>
<i>Dr Tan Kheng Khoo</i>	<i>1971 - 1975</i>
<i>Prof Lim Pin</i>	<i>1975 - 1978</i>
<i>Prof Feng Pao Hsü</i>	<i>1978 - 1987</i>
<i>Prof Chee Yam Cheng</i>	<i>1988 - 1995</i>
<i>Prof Tan Choon Kim</i>	<i>1995 - 1996</i>
<i>Prof Kua Ee Heok</i>	<i>1996 - 1999</i>
<i>A/Prof C Rajasoorya</i>	<i>2000 - 2003</i>
<i>Prof Wilfred CG Peh</i>	<i>2004 - 2009</i>